

Original Research Article

Radiographic imaging of mastoid in chronic otitis media: need or tradition?

Sabeeh Beig^{1*}, Saifullah Khalid², Satish Chandra Sharma¹

¹Department of Otorhinolaryngology, ²Department of Radiodiagnosis, J. N. Medical College and Hospital (A. M. U.), Aligarh, Uttar Pradesh, India

Received: 03 July 2020

Revised: 18 July 2020

Accepted: 20 July 2020

***Correspondence:**

Dr. Sabeeh Beig,

E-mail: sabeehbeig@gmail.com

Copyright: © the author(s), publisher and licensee Medip Academy. This is an open-access article distributed under the terms of the Creative Commons Attribution Non-Commercial License, which permits unrestricted non-commercial use, distribution, and reproduction in any medium, provided the original work is properly cited.

ABSTRACT

Background: Computed tomography is the imaging of choice in chronic otitis media (COM) but it is neither available at every centre nor is affordable to masses of economically weaker countries. In this situation where only X-ray facility is available should plain radiographs of mastoid be done? If yes then what is the analytical evidence? This study, was conducted to find the utility of plain radiographs of mastoid by comparing radiological findings vis-a-vis operative findings.

Methods: Pre-operative radiographs of mastoids (Schuller's view (s/v)) were taken and the radiological findings were statistically analysed with the operative findings.

Results: Plain radiograph of mastoid (s/v) predicted some of the surgical landmarks of mastoid surgery viz tegmen and sinus plates with a fair degree of accuracy. The positive predictive value (PPV) for radiolucent shadow (assumed to indicate bone destruction and thus cholesteatoma) was also high but at the same time, a low negative predictive value and a Cohen's kappa test showing only a fair agreement underscores the point that absence of a radiolucent shadow does not rule out the presence of cholesteatoma.

Conclusions: Radiographs of mastoid are helpful in providing a prior knowledge of the surgical landmarks in mastoid surgery. Hence with this information, if a surgeon finds himself more at ease in operating a patient then this imaging should be done when CT scan facility is unavailable. However, citing the limited information on other aspects of the disease, its use as a 'routine' investigation in chronic otitis media is discouraged.

Keywords: Plain radiograph mastoids, Schuller's view, Chronic otitis media, Attico antral, Cholesteatoma

INTRODUCTION

Major proportions of chronic otitis media (COM) patients are concentrated in the developing countries and India belongs to the highest prevalence group.¹

Imaging is universal investigation in cases of COM. Indeed, studies have shown usefulness of high-resolution computed tomography (HRCT) of the temporal bone in these cases.² However, facilities of CT and MRI are neither available everywhere nor affordable for every

patient, more so in countries like India where a substantial population lives below poverty line and in low facility areas. In this situation where only X-ray facility is available should plain radiographs of mastoid be done? If yes then what is the analytical evidence?

The present study was done to find the utility of plain radiographs of mastoid by comparing radiological findings vis-a-vis operative findings.

METHODS

This was a cross-sectional analytical study done at tertiary level teaching hospital J. N. Medical College and Hospital, A. M. U, Aligarh. Study period was from October 2015 to April 2018.

Study population

32 patients of COM (atticoanal disease) who presented to ENT outpatient facility of the hospital were included. Patients with a previous history of ear surgery, history of temporal bone fracture, those having a neoplastic or granulomatous disease of temporal bone and those considered unfit for surgery (e.g. pregnancy/ischemic heart disease) were excluded. Diagnosis of COM (atticoanal disease) was made on clinical grounds.

Study instruments

Performa for history and examination, for radiologist to report findings, for surgeon to report intra operative findings.

After a detailed history and examination and obtaining an informed consent these patients underwent bilateral plain radiograph of mastoid Schuller's view (s/v) and findings were reported by a single experienced radiologist. The radiologist was asked to comment on the following points: dural plate position, sinus plate position, dural plate integrity, sinus plate integrity, radiolucent shadow in the mastoid. This radiological reporting was then compared with the intra-operative findings.

Ethical approval

All procedures performed were in accordance with the ethical standards of the institutional ethics committee and with the 1964 Helsinki declaration and its later amendments or comparable ethical standards.

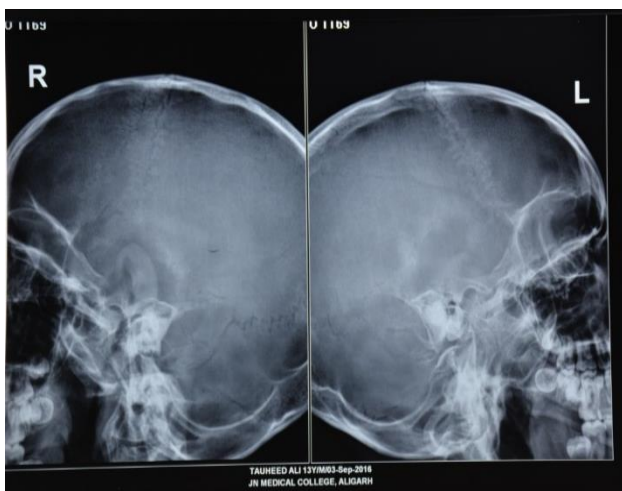


Figure 1: Patient with right COM showing radiolucent shadow in the right mastoid.

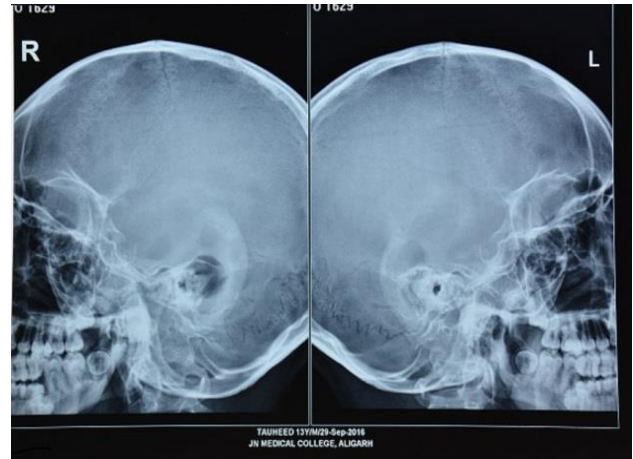

Figure 2: Post-operative radiograph.

Data management and processing

Considering the intraoperative findings as the gold standard, sensitivity, specificity, and positive and negative predictive values were calculated for all the analysed points. In addition, a Cohen's kappa value was also calculated while analysing radiolucent shadow.

RESULTS

A total of 32 patients were enrolled in the study. Majority of the patients were in the second decade of life (Figure 3). Out of the total number of subjects 19 were males and 13 were females with a male to female ratio of 1.5:1 (Figure 4). Dural plate position was found normal in all the 32 cases intraoperatively and plain radiograph (s/v) predicted the same with 100% negative predictive value (NPV) (Table 1).

One case of an anteposed sigmoid sinus was detected intra-operatively. The NPV based on radiograph was 96.88% (Table 2).

Intra-operative finding of breach in dural plate was seen in 5 patients. It was radiologically detected in all the cases but 5 false positive results were also given. Hence, the NPV was 100% in this case but the PPV dropped to just 50% (Table 3).

Out of the 7 cases of sinus plate erosion only 2 could be detected on plain radiograph (s/v) giving an NPV of 82.14% (Table 4).

In 10 cases where a radiolucent shadow was reported, cholesteatoma was found in all the cases giving a 100% positive predictive value but at the same time an NPV of just 36.36% and a Cohens kappa value of 0.263.

This implies that radiographic finding of a radiolucent shadow in these patients was strongly suggestive of cholesteatoma but at the same time its absence did not rule out the same (Table 5 and 6).

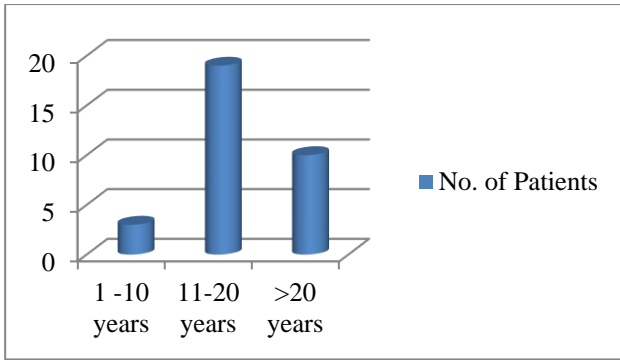


Figure 3: Age wise distribution of patients.

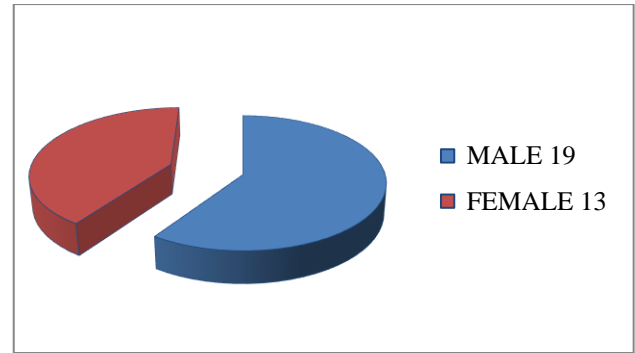


Figure 4: Gender distribution of patients.

Table 1: Correlating dural plate position.

Dural plate position		TP	TN	FP	FN	Sn (%)	Sp (%)	Predictive values (95% CI)			
R (S/V)	Operative	PPV (%)		NPV (%)							
N	Low	N	Low								
32	0	32	0	0	32	0	0	*	100	*	100

R (S/V) = radiograph (Schuller's view), N = normal, TP = true positive, TN = true negative, FP = false positive, Sn = sensitivity, Sp = specificity, CI = confidence interval, PPV = positive predictive value, and NPV = negative predictive value.

Table 2: Correlating sinus plate position.

Sinus plate position		TP	TN	FP	FN	Sn (%)	Sp (%)	Predictive values (95 % CI)			
R (S/V)	Operative	PPV (%)		NPV (%)							
N	An.	N	An.								
32	0	31	1	0	31	0	1	0	100	*	96.88

R (S/V) = radiograph (Schuller's view), N = normal, An. = anteposed, TP = true positive, TN = true negative, FP = false positive, Sn = sensitivity, Sp = specificity, CI = confidence interval, PPV = positive predictive value, and NPV = negative predictive value.

Table 3: Correlating dural plate integrity.

Dural plate integrity		TP	TN	FP	FN	Sn (%)	Sp (%)	Predictive values (95 % CI)			
R (S/V)	Operative	PPV (%)		NPV (%)							
N	Br.	N	Br.								
22	10	27	5	5	22	5	0	100	81.48	50 (31.19-68.81)	100

R (S/V) = radiograph (Schuller's view), N = normal, Br. = Breach, TP = true positive, TN = true negative, FP = false positive, Sn = sensitivity, Sp = specificity, CI = confidence interval, PPV = positive predictive value, and NPV = negative predictive value.

Table 4: Correlating sinus plate integrity.

Sinus plate integrity		TP	TN	FP	FN	Sn (%)	Sp (%)	Predictive values (95 % CI)			
R (S/V)	Operative	PPV (%)		NPV (%)							
N	Br.	N	Br.								
28	4	25	7	2	23	2	5	28.57	92.00	50 (14.53-85.47)	82.14 (73.95-88.17)

R (S/V) = radiograph (Schuller's view), N = normal, Br. = breach, TP = true positive, TN = true negative, FP = false positive, Sn = sensitivity, Sp = specificity, CI = confidence interval, PPV = positive predictive value, and NPV = negative predictive value.

Table 5: Correlating radiolucent shadow with cholesteatoma.

Radiolucent shadow		Cholesteatoma	TP	TN	FP	FN	Sn (%)	Sp (%)	Predictive values (95 % CI)		
R(S/V)	Operative	PPV (%)		NPV (%)							
P	A	P	A								
10	22	24	8	10	8	0	14	41.67	100	100	36.36 (28.95-44.49)

R (S/V) = radiograph (Schuller's view), P = present, A = absent, TP = true positive, TN = true negative, FP = false positive, Sn = sensitivity, Sp = specificity, CI = confidence interval, PPV = positive predictive value, and NPV = negative predictive value.

Table 6: Analysing interrater agreement between radiolucent shadow on plain radiograph (s/v) and intra-operative finding of cholesteatoma.

Variables	Radiolucent shadow	No radiolucent shadow
Cholesteatoma	10	22
No cholesteatoma	0	8

Cases in agreement = 18; Cohens Kappa value (with 95% confidence interval) = 0.263 (0.067-0.459); Strength of agreement = fair (0.01-0.20 = slight agreement, 0.21-0.40 = fair agreement, 0.41-0.60 = moderate agreement, 0.61-0.80 = substantial agreement, 0.81-100 = almost perfect agreement).

DISCUSSION

In this study, the age ranges from 3 years to 37 years with a mean age of 17.72 years. Major proportions of patients are in their second decade of life. Likewise, Gerami et al observed the disease in the younger age group.³ However Leighton et al and Bates et al found the mean age in their study to be in the sixth and fourth decade respectively.^{4,5} The male to female ratio was found to be 1.5:1 which indicates a male predominance. This is in accordance with the findings of Gerami et al and Guarano et al.^{3,6}

In the present study the operating surgeon did not come across any case of a low-lying dura. Plain radiograph mastoid (s/v) predicted the finding with 100% negative predictive value which implies that if a low-lying dura is not reported on a plain radiograph mastoid (s/v), it is unlikely that a low-lying dura would be found intraoperatively.

Intra-operatively there was 1 case of an anteposed sigmoid sinus which was reported as normal by the radiologist while the rest were correctly reported and hence a negative predictive value of 96.88% was obtained.

Our findings of a low-lying dura (0/32 cases) is similar to Rai who found that only 1 out of their 50 cases had a low-lying dura.⁷ Our finding is however in contrast to Zhaohui et al who reported a 21.8% incidence of low-lying dura in their study.⁸ The incidence of an anteposed sigmoid sinus is 3.1% in our study which is similar to Tomura et al (1.6%) but it differs from that reported by Zelikovich et al (36.5%).^{9,10}

Incidence of low-lying dura and anteposed sigmoid sinus varies widely among previous studies. For low lying dura, it varies between 2% and 21.8% whereas for an anteposed sigmoid sinus it varies between 1.6% and 36.5%.⁷⁻¹⁰ This wide variation can be attributed to the fact that there are no defined landmarks to label a case as having a low lying dura or an anteposed sigmoid sinus and hence reporting becomes highly subjective which is reflected in the wide range of above mentioned values.

Intra-operatively dural plate breach was found in 5 cases (15.6%). This finding is similar to Rai who reported an incidence of 12% but is in conflict with Suatkeskin et al who reports an incidence of 5%.^{7,11}

The coherence with findings of Rai which is an India based study and the conflict with findings of Suatkeskin et al which is a Turkey based study is probably for the reason that in the Indian scenario, patients come to medical attention very late in the course of disease progression especially at the tertiary health care facility like the one in which the present study was conducted.⁷⁻¹¹

Plain radiograph mastoid (s/v) detected all the 5 cases of dural plate erosion with an additional 5 false positive results thereby accounting for 100% negative predictive value but only 50% positive predictive value. Hence if intact dural plate is reported, it is quite likely that the dural plate will be found intact intraoperatively but at the same time a positive result has only a 50% chance of being true. Intra-operatively sinus plate erosion was found in 21.8% of cases. This is similar to the findings of Rai (18%).⁷ Plain radiograph mastoid (s/v) detected sinus plate erosion with a negative predictive value of 82.14%. Presence of bone destruction with cholesteatoma was found intraoperatively in 75% of the cases. This is in line with the findings of O'reilly et al (79%) and also Jackler, O'Donoghue, and Alzhoubi with all 3 of them reporting an incidence of 80%.¹²⁻¹⁵

Radiolucent shadow in mastoid on plain radiograph mastoid (s/v) in these study subjects of COM was considered to represent bone destruction and indicative of presence of cholesteatoma (Figures 1 and 2). Indeed, all 10 cases with a radiolucent shadow on plain radiograph mastoid (s/v) did have cholesteatoma intra-operatively giving a 100% positive predictive value. However, a negative predictive value of 36.36% together with a Cohen's kappa value of 0.263 which is interpreted as only a 'fair' degree of agreement was also found. This underscores the point that absence of a radiolucent shadow does not rule out the presence of cholesteatoma.

Limitations

This study was undertaken with a sample size of 32 subjects. Although statistically adequate, a larger sample size may lead to further insights and more authenticated findings applicable to a larger cohort.

Clinical significance

This study provides a statistical basis, discouraging routine use of plain radiographs in chronic otitis media, a practice that is prevalent in the Indian scenario.

CONCLUSION

We thus conclude that plain radiographs of mastoid are to some extent helpful in providing a prior knowledge of the

surgical landmarks in mastoid surgery. Hence with this information, if a surgeon finds himself more at ease in operating a patient then a plain radiograph of mastoid may be done when CT scan facility is unavailable. However, citing the limited information that a plain radiograph of mastoid has to offer on other aspects of the disease, its use as a routine investigation in chronic otitis media should be discouraged.

Funding: No funding sources

Conflict of interest: None declared

Ethical approval: The study was approved by the Institutional Ethics Committee

REFERENCES

1. World Health Organization; Chronic suppurative otitis media, Burden of illness and Management options; report of Department of Child and Adolescent Health and Development, Prevention of Blindness and Deafness, Geneva; 2004.
2. Beig S, Sharma SC, Khalid M. Revisiting Correlation Between Pre-Operative High-Resolution Computed Tomography and Operative Findings in Attico Antral Disease. *Indian J Otolaryngol Head Neck Surg.* 2018;1-6.
3. Gerami H, Naghavi E, Moghadam WM, Forghanparast K, Akbar MH. Comparison of preoperative computerized tomography scan imaging of temporal bone with the intraoperative findings in patients undergoing mastoidectomy. *Saudi Med J.* 2009;30:1048.
4. Leighton SEJ, Robson AK, Anslow P. The role of CT imaging in management of CSOM. *Clin Otolaryngol.* 1993;18:23-9.
5. Bates GJ, O'Donoghue GM, Anslow P, Houlding T. Can CT Detect Labyrinthine Fistulae Preoperatively. *Acta Otolaryngologica.* 1988;106:40-5.
6. Gaurano JL, Joharjy IA. Middle ear cholesteatoma: Characteristic CT findings in 64 patients. *Ann Saudi Med.* 2004;24:4427.
7. Rai T. Radiological study of the temporal bone in chronic otitis media: Prospective study of 50 cases. *Indian J Otol.* 2014;20:48-55.
8. Zhaohui L, Zhenchang W, Junfang X, Kun Z, Hong Z. HRCT study of anatomic variations of temporal bone. *Chin Arc Otolaryngol Head Neck Surg.* 2006;2:97-101.
9. Tomura N, Sashi R, Kobayashi M, Hirano H, Hashimoto M, Watarai J. Normal variations of the temporal bone on high-resolution CT: Their incidence and clinical significance. *Clin Radiol.* 1995;50:144-8.
10. Zelikovich EI. Computed tomography of the temporal bone in diagnosis of otitis media chronicapurulenta. *Vestn Otorinolaringol.* 2004;4:25-9.
11. Keskin S, Çetin H, Tore HG. The Correlation of temporal bone CT with surgery findings in evaluation of chronic inflammatory diseases of the middle ear. *Eur J Gen Med.* 2011;8:24-30.
12. O'Reilly BJ, Chevretton EB, Wylie I, Thakkar C, Butler P, Sathanathan N, et al. The value of CT scanning in chronic suppurative otitis media. *J Laryngol Otol.* 1991;105:990-4.
13. Jackler RK, Dillon WP, Schindler RA. Computed tomography in suppurative ear disease: a correlation of surgical and radiographic findings. *Laryngoscope.* 1984;94:746-52.
14. O'Donoghue GM. Cholesteatoma: Diagnosis and staging by CT scan. *J Otolaryngol.* 1987;12:157-60.
15. Alzoubi FQ, Odat HA, Balas AHA, Saeed SR. The role of pre-operative CT scan in patients with chronic otitis media. *Eur Arch Otorhinolaryngol.* 2009;266:807-9.

Cite this article as: Beig S, Khalid S, Sharma SC. Radiographic imaging of mastoid in chronic otitis media: need or tradition? *Int J Otorhinolaryngol Head Neck Surg* 2020;6:1592-6.