

## Original Research Article

# Pediatric aero-digestive foreign bodies in the emergency setup: an otorhinolaryngologist's perspective

Abhilasha Goswami\*, Hironya Borah

Department of Otorhinolaryngology, Gauhati Medical College, Guwahati, Assam, India

**Received:** 22 June 2020

**Accepted:** 01 August 2020

### \*Correspondence:

Dr. Abhilasha Goswami,

E-mail: [abhilasha.goswami@gmail.com](mailto:abhilasha.goswami@gmail.com)

**Copyright:** © the author(s), publisher and licensee Medip Academy. This is an open-access article distributed under the terms of the Creative Commons Attribution Non-Commercial License, which permits unrestricted non-commercial use, distribution, and reproduction in any medium, provided the original work is properly cited.

## ABSTRACT

**Background:** The objective of the study was to investigate cases of foreign bodies in the aero-digestive tract among the paediatric population.

**Methods:** This study was carried out under the aegis of the department of otorhinolaryngology over a one-year period, from April 2019 to March 2020. A total of 82 paediatric patients presented to the emergency department with aero-digestive foreign body, where opinion of the otorhinolaryngologist was sought. All the patients were initially stabilised and assessed clinically. Detailed history was obtained, thorough clinical evaluation done and necessary investigations including radiological tests were performed. After ascertaining the nature and location of the foreign body, prompt removal of the same was done in all the patients under general anaesthesia.

**Results:** A total of 82 children presented to the emergency with history of inhalation/ingestion of foreign body or suspicion of such, and requiring otorhinolaryngological intervention. There were 55 boys and 27 girls, with 74 cases of ingestion and 8 cases of aspiration of foreign body. The most common foreign body ingested was coin and the most common foreign body aspirated was small button battery.

**Conclusions:** Foreign bodies in the aero-digestive tract are a common problem encountered by the otorhinolaryngologist in the emergency setup. It constitutes a health hazard in all age groups, but more so among the paediatric population, requiring effective management and immediate intervention. Careful clinical and radiological evaluation followed by prompt removal of the aero-digestive foreign body is essential to reduce the morbidity and mortality. Prevention and public education are the most vital and ideal management for this serious problem.

**Keywords:** Foreign body, Endoscopy, Esophagoscopy, Otorhinolaryngology

## INTRODUCTION

A foreign body is an exogenous or endogenous object or extraneous matter that has entered the body either by accident or by design, but does not belong there.

The aero-digestive tract refers to the combination of the organs and tissues forming the respiratory and the digestive tracts, including the nose, the oral cavity, the pharynx, the larynx, the trachea and part of the esophagus.<sup>1</sup>

Cases of foreign bodies in the aero-digestive tract among the paediatric population is a common problem going as far back as 1692, when Frederick the Great, the Crown Prince of Brandenburg, at just four years of age, swallowed a shoe buckle.<sup>2</sup> Foreign bodies in the aero-digestive tract are a common clinical entity encountered during clinical practice by an otorhinolaryngologist. Most of the foreign bodies do not have an immediate problem on the airway and also pass through the gastro-intestinal tract easily, causing little or no sequelae. Some foreign bodies (e.g., magnets, button batteries, nails) are serious and life-threatening emergencies, which if not discovered

early, can lead to significant mortality and morbidity. Otorhinolaryngologists should be familiar with the diagnosis, treatment and complications of foreign bodies in the aero-digestive tract, so as to avoid over-testing and over-treating, while identifying and intervening for high-risk foreign bodies.

### **Epidemiology**

Global population explosion and an expeditious lifestyle are two of the chief factors responsible for the increase in the number of aero-digestive foreign bodies cases in both children and adults. Majority of the paediatric aero-digestive foreign bodies are because of toddlers and pre-schoolers who, besides developing gross and fine motor skills, are also curious to explore the world with their hands and mouths.<sup>3</sup> Among the older children, boys are more prone to inhaling and/or ingesting foreign bodies, mostly due to their poor situational decision-making.<sup>4</sup> A large majority of cases of pediatric aero-digestive foreign bodies are either unrecognised, or are managed at home, without any intervention by health care workers<sup>5</sup>. The rest are brought to the attention of the primary care physician or to the emergency department, where careful assessment, clinical evaluation and radiological investigations are carried out for effective and prompt management.

### **Clinical scenario**

Aspiration and ingestion of foreign bodies is a commonly encountered clinical condition in the life of an otorhinolaryngologist. No age group is immune to this condition, but it is more prevalent among the paediatric population. In children, the commonest foreign body reported is coin, followed by jewellery, marbles, peanuts, toys, button, batteries and sometimes even safety pins. In 70-80% of cases with history of foreign body ingestion, the foreign bodies that have passed the oesophagus will pass uneventfully via the gastro-intestinal tract. The foreign bodies aspirated into the trachea-bronchial tree pose diagnostic challenge, as often such foreign bodies are radiolucent.<sup>6,7</sup> Management of cases with foreign bodies in the aero-digestive tract requires clinical acumen and proper radiological evaluation. Foreign bodies in the aero-digestive tract should be promptly and effectively managed to prevent complications. Foreign bodies in the aero-digestive tract are the commonest cause of morbidity and mortality in the paediatric age group worldwide. It is the third leading cause of death in infants and the fourth leading cause of death in children between 1-6 years of age.<sup>8</sup> Aero-digestive foreign bodies have both acute and chronic life-threatening complications such as: atelectasia, ulceration and necrosis of mucosa, abscesses, sepsis and even death. So, observation and delayed treatment are not recommended.

This study is aimed to investigate cases of foreign bodies in the aero-digestive tract among the pediatric population, and to suggest preventive measures for the same.

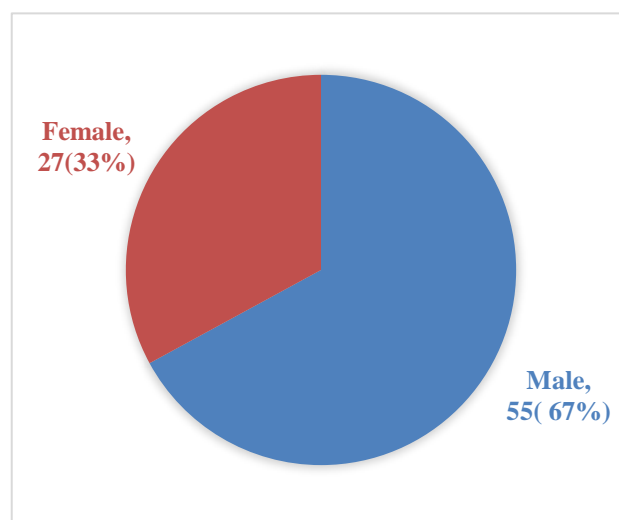
## **METHODS**

After approval by the institutional ethical committee, the study was carried out on a total of 82 paediatric patients with foreign bodies in the aerodigestive tract, who presented to the otolaryngologist on an emergency basis, over a period of one year - from April 2019 to March 2020. These patients were studied in detail regarding their age, sex, type of foreign body, site of lodgement, common symptoms during presentation and the problems encountered while managing these patients.

Inclusion criteria were, all children between 0-12 years of age with history of ingestion/inhalation of foreign body or suspected of such on the basis of their clinical symptoms and foreign body in nose, nasopharynx, hypopharynx, oesophagus, trachea and bronchus. Exclusion criteria were foreign bodies in oral cavity and oropharynx. Patients fulfilling the inclusion criteria were initially stabilised and then evaluated. Detailed history was taken from the parents/siblings/caregivers so as to understand the nature of the foreign body, as radiolucent foreign bodies often lead to diagnostic dilemma. Thorough clinical evaluation and necessary investigations, including radiological tests, were carried out and the patients were treated accordingly.

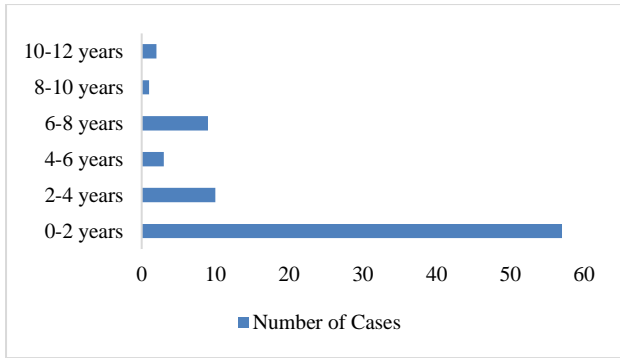
## **RESULTS**

In our study, out of the 82 cases, 67% were male and 33% were female (Figure 1).



**Figure 1: Distribution of paediatric aero-digestive tract foreign bodies on the basis of gender.**

In our study, most of the cases were found to be in the age group of 0-2 years (57 cases), followed by 2-4 years (10 cases), 6-8 years (9 cases), 4-6 years (3 cases), 10-12 years (2 cases) and 1 case in the 8-10 years age group (Figure 2).



**Figure 2: Distribution of cases on the basis of age.**

In our study, 8 cases presented to us with history of aspiration of foreign body and the remaining 74 cases had history of ingestion of foreign body (Table 1).

**Table 1: Distribution of cases based on site of lodgement of foreign body.**

Location of foreign body	Number of cases	
	Male	Female
Nose	3	1
Nasopharynx	1	1
Hypopharynx	30	21
Esophagus	19	4
Trachea	1	0
Bronchi	1	0

In our study, foreign bodies were removed by different procedures based on their size and site of lodgement. Endoscopic removal of foreign bodies were done in 6 cases, direct laryngoscopy with foreign body removal was done in 51 cases, removal of foreign body using rigid esophagoscope was done in 23 cases and in 2 cases, where the foreign body was lodged in the trachea and the left bronchus respectively, flexible bronchoscopy with foreign body removal was done (Table 2).

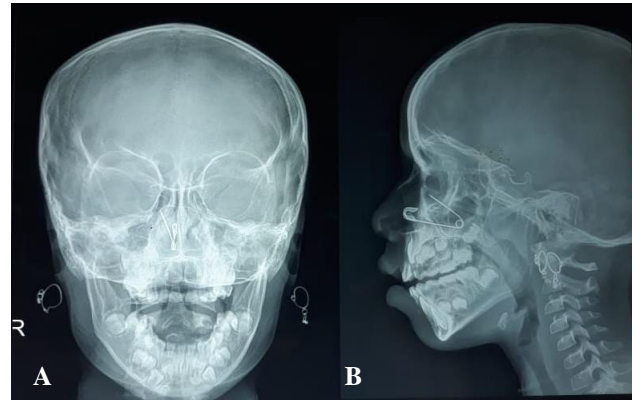
**Table 2: Distribution of cases based on the procedure executed to remove the foreign body.**

Procedure	Number of cases
Endoscopic removal	6
Direct laryngoscopy	51
Rigid esophagoscopy	23
Flexible bronchoscopy	2

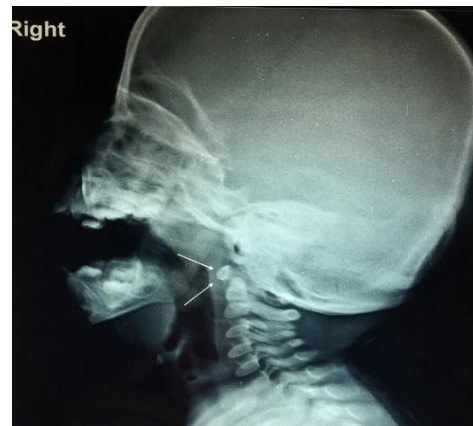**DISCUSSION**

Foreign bodies in the aero-digestive tract are some of the most common cases encountered by the otorhinolaryngologist in the emergency set-up (Figures 3-7). Aspiration and ingestion of foreign bodies is a common adverse event in all age groups, but more so in infants and children. Clinical acumen of the treating otorhinolaryngologist is paramount in the diagnosis,

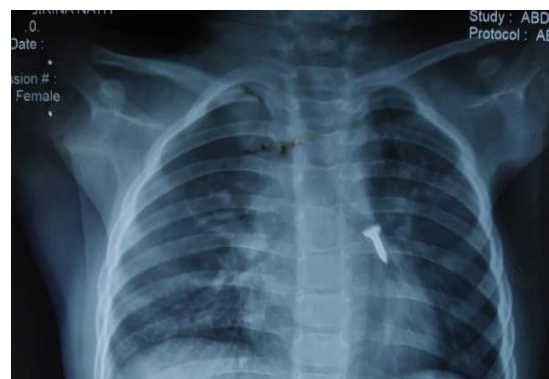management and prompt retrieval of the foreign body from the paediatric aero-digestive tract.



**Figure 3: Radiograph (A) antero-posterior, and (B) lateral views of a 7 year old female showing a foreign body (an open safety pin) in her right nasal cavity.**



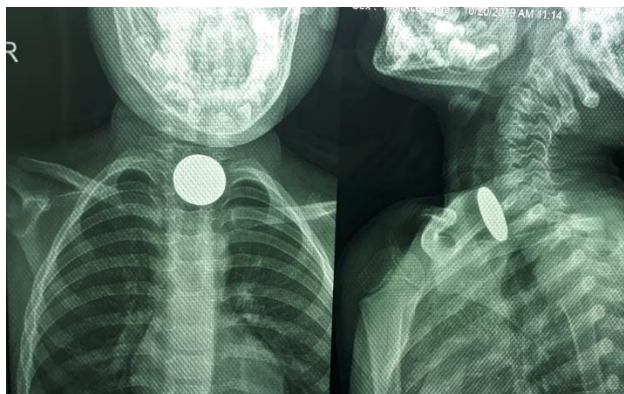**Figure 4: Radiograph of a 1 year old male showing a radioopaque foreign body in the nasopharynx.**



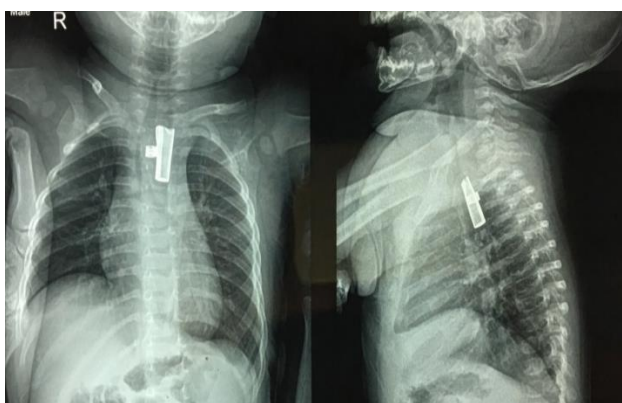
**Figure 5: A postero-anterior view chest radiograph of a 3 year old female showing a foreign body (nail) in the left bronchus.**

In our study, out of the total 82 cases, 55 were male and 27 were female, with a male to female ratio of 2:1. In a study conducted by Rothmann and Boeckman in 1980, they found that boys were more prone to aerodigestive

tract foreign bodies than girls (2:1).<sup>9</sup> This is similar with that observed by authors like Brown and Clarck,<sup>10</sup> and O'Neil, Holdomb and Neblett.<sup>11</sup>



**Figure 6: Radiograph of a 2 year old male showing a foreign body(coin) in the hypopharynx.**



**Figure 7: Radiograph of a 6 month old male showing a foreign body(pendant) in the oesophagus.**

In our study, maximum cases (57 cases, 70%) were found in the age group of 0-2 years, followed by that in the age group of 2-4 years (10 cases). This is similar to the findings of authors Jackson et al (74%), Rothmann et al (77% of 225 cases) and Brown et al (74% of 115 cases).<sup>9,10,12</sup>

In our study, most of the foreign bodies were lodged in the hypopharynx (62%) and were removed using direct laryngoscopy. Such cases were successfully managed by laryngoscopy almost a century ago by Jackson, who reduced the mortality rate in aero-digestive tract foreign bodies from 20% to 2%.<sup>12</sup> A case with foreign body in the bronchus(nail) was successfully managed by flexible bronchoscopy. Killian, the pioneer of bronchoscopy, in 1897, successfully managed tracheobronchial foreign bodies by bronchoscopic extraction.<sup>13</sup>

In our study, there were no complications while performing the intervention or in the post-operative period. All our patients were discharged by the 3<sup>rd</sup> post-operative day.

## Prevention

Prevention is the most valuable and ideal management of foreign body ingestion, be it in the pediatric, adult or elderly population. Education of caregivers so as to ensure a safe surrounding milieu and attention to toy safety are indispensable for preventing foreign body ingestion.<sup>14</sup> Doctors should provide anticipatory guidance and educate the parents on prevention and safety during every visit. Otorhinolaryngologists treating a patient with foreign body in the aero-digestive tract should capitalize on the visit and consider it a “learning session” regarding appropriate toys and foods that parents provide to their children.

## CONCLUSION

Foreign bodies in the aero-digestive tract are a common problem faced during clinical practice. It constitutes a health hazard in all age groups, but more so among the paediatric population, requiring effective management and immediate intervention. Detailed history, careful assessment, clinical evaluation, radiological investigations after stabilizing the child in the emergency department and prompt removal of the aero-digestive foreign body is essential to reduce the morbidity and mortality. Aero-digestive foreign bodies have both acute and chronic life-threatening complications such as: atelectasia, ulceration and necrosis of mucosa, abscesses, sepsis and even death. So, observation and delayed treatment are not recommended. As is the case with all injuries, “prevention is better than cure”. Injury prevention and public education are the most vital and important deterrents for this serious problem. Parents or caregivers should be educated about keeping away hazardous articles from reach of children and to keep a close supervision on the activities of their children, as it is the hallmark of prevention. However, when all precautions fail, swift and careful intervention will reduce long-term complications.

*Funding: No funding sources*

*Conflict of interest: None declared*

*Ethical approval: The study was approved by the Institutional Ethics Committee*

## REFERENCES

1. NCI Dictionary of Cancer Terms. National Cancer Institute. Available at: <https://www.cancer.gov/publications/dictionaries/cancer-terms/def/aero-digestive-tract>. Accessed on 25 May 2020.
2. Denney W, Ahmad N, Dillard B, Nowicki MJ. Children will eat the strangest things: a 10 year retrospective analysis of foreign body and caustic ingestions from a single academic center. *Pediatr Emerg Care.* 2012;28(8):731-4.
3. Hesham A, Kader H. Foreign body ingestion: children like to put objects in their mouth. *World J Pediatr.* 2010;6(4):301-10.

4. Lemberg PS, Darrow DH, Holinger LD. Aerodigestive tract foreign bodies in the older child and adolescent. *Ann Otol Rhinol Laryngol*. 1996; 105:267-71.
5. Conners GP, Chamberlain JM, Weiner PR. Pediatric coin ingestion: a home based survey. *Am J Emerg Med*. 1995;13(6):638-40.
6. Karakoc F, Cakir E, Ersu R, Uyan ZS, Colak B, Karadag B, et al. Late diagnosis of foreign body aspiration in children with chronic respiratory symptoms. *Int J Pediatr Otorhinolaryngol*. 2007;71:241-6.
7. Bittencourt PF, Camargos PA, Scheinmann P, De Blic J. Foreign body aspiration: Clinical, radiological findings and factors associated with its late removal. *Int J Pediatr Otorhinolaryngol* 2006;70:879-4.
8. Esclamado RM, Richardson MA. Laryngotracheal foreign bodies in children. A comparison with bronchial foreign bodies. *Am J Dis Child* 1987;141:259-62.
9. Rothmann BF, Boeckman CR. Foreign bodies in the larynx and tracheo bronchial tree. *Ann Otol Rhinol Laryngol*. 1980;89:434-6.
10. Brown TC, Clarck CM. Inhaled FB in children. *Medical Journal Australia*. 1983;2:322-6.
11. O'Neil JA, Jr. Holdomb CW, Jr. Neblett WW. Management of tracheobronchial & Oesophageal foreign bodies in childhood. *J Paediatric Surg*. 1983;18:475-9.
12. Chevalier J, Jackson L. Diseases of the air and food passages of foreign body origin. WB Saunders & Co. Ltd. Philadelphia and London. *J Laryngol Otol*. 1936;51(12):824-5.
13. Fleischer K. Erkennung und Entfernung Von. Bronchial-frem-dkorpem einstJetzt. *Ther-Ggegenw*. 1974;113:348-58.
14. Committee on Injury, violence, and poison prevention. Policy statement-prevention of choking among children. *Pediatrics*. 2010;125 (3):601-7.

**Cite this article as:** Goswami A, Borah H. Pediatric aero-digestive foreign bodies in the emergency setup: an otorhinolaryngologist's perspective. *Int J Otorhinolaryngol Head Neck Surg* 2020;6:1642-6.