

Case Report

First branchial cleft fistula: a case report

Rupa Mehta^{1*}, Ankit Mishra¹, Nitin M. Nagarkar¹, Vandita Singh²

¹Department of ENT and Head and Neck Surgery, ²Department of Pathology, All India Institute of Medical Sciences Raipur, Chhattisgarh, India

Received: 05 June 2020

Accepted: 09 July 2020

***Correspondence:**

Dr. Rupa Mehta,

E-mail: rmehta0409@yahoo.com

Copyright: © the author(s), publisher and licensee Medip Academy. This is an open-access article distributed under the terms of the Creative Commons Attribution Non-Commercial License, which permits unrestricted non-commercial use, distribution, and reproduction in any medium, provided the original work is properly cited.

ABSTRACT

First branchial cleft anomalies (BCA) are a rare finding in head and neck with incidence of nearly 1 million per year which are distributed below external auditory canal, above the hyoid bone, anterior to sternocleidomastoid and posterior to submandibular triangle. First branchial cleft cysts are frequently misdiagnosed as they are rare and pose unfamiliar clinical signs and symptoms. Here we are reporting a case of surgical management of 1st branchial cleft fistula in a 5 years old male child from AIIMS, Raipur, Chhattisgarh, India as it's a rare entity. Child presented with discharge from right upper part of neck. There was a swelling in right upper lateral part of neck with an opening also in floor of right external auditory canal (EAC). Contrast enhanced computed tomography of neck showed a 4.8 cm long obliquely oriented fistulous tract opening at junction of middle and upper one third of sternocleidomastoid with opening in right EAC. Surgical excision of the fistulous tract was done with preservation of facial nerve. Histopathology examination confirmed the presence of fistula. Common clinical presentation of BCAs is pre-auricular swelling (24%), parotid swelling (36%) or cervical region swelling (41%). In our case, it was a fistulous opening that presented as discharging tract in upper neck. Management include early diagnosis, control of infection and complete excision with facial nerve preservation Surgical approach should be based on the clinical examination, imaging and clinical course; and there is a need to safely identify and preserve facial nerve in almost all cases.

Keywords: Branchial cleft anomalies, Facial nerve, Branchial cleft fistula

INTRODUCTION

The term 'branchial cyst' was coined by Ascherson in 1832.¹ First branchial cleft anomalies are a rare finding in head and neck, the incidence being around 1 million per year.¹⁻³ The occurrence of first branchial cleft anomalies usually varies from less than 8% to 21.4%.¹⁻³ They are distributed below external auditory canal, above the hyoid bone, anterior to sternocleidomastoid and posterior to submandibular triangle.¹ Main theories which describe the development of branchial cleft anomalies include incomplete obliteration of branchial mucosa, persistence of vestiges of pre-cervical sinus, origin from

thyropharyngeal duct and origin from cystic lymph nodes.¹

In 1972, Work proposed a classification for first branchial cleft anomalies which states that type 1: anomalies superficial to facial nerve in close proximity to ear and type 2: lesion communicating with external auditory canal or tympanic membrane, mostly lying medial to facial nerve.³

First branchial cleft cysts are frequently misdiagnosed as they are rare and pose unfamiliar clinical signs and symptoms.⁴ Management of these includes early diagnosis, control of infection and complete excision with facial nerve preservation.⁵ Here we present a case of first

branchial cleft fistula in a 5 years old male child and its surgical management.

CASE REPORT

A 5-year-old male child visited department of Otorhinolaryngology and Head and Neck Surgery in outpatient department at AIIMS Raipur with complaints of recurrent discharge from right upper neck since last 3 years. According to his parents, the child had 2 to 3 such episodes per year on an average which began as painless swelling which later ruptured spontaneously. On various occasions it was associated with ear discharge which subsequently resolved with medication. Child had unremarkable family and medical history. There was a swelling at the junction of upper and middle one third of sternocleidomastoid muscle at its anterior border with small opening in the floor of right external auditory canal with no active discharge and no cervical lymphadenopathy.

Management and surgical approach

USG neck revealed a cutaneous lesion in right paramedian region in anterior cervical triangle with irregular hypoechoic sinus tract, suggestive of branchial cleft sinus. Contrast enhanced computed tomography of neck showed a 4.8 cm long obliquely oriented fistulous tract opening at junction of middle and upper one third of sternocleidomastoid, then extending superiorly and laterally along the anterior border of sternocleidomastoid travelling behind right submandibular gland posterior to ramus of mandible and deep to parotid gland opening internally at anteroinferior and medial aspect of right auricle.

Based on the investigations, diagnosis of first branchial cleft fistula was made and excision under general anaesthesia was planned.

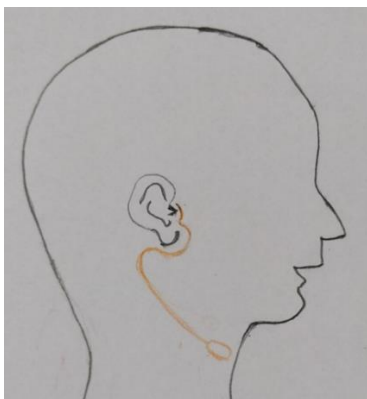


Figure 1: Incision with lower elliptical extension around the opening in lower part of neck.

Modified Blair's incision was given behind and below the right pinna and extended below till the opening in the upper neck which was elliptically included in the incision

(Figure 1). Methylene blue dye was injected through the opening in upper neck.

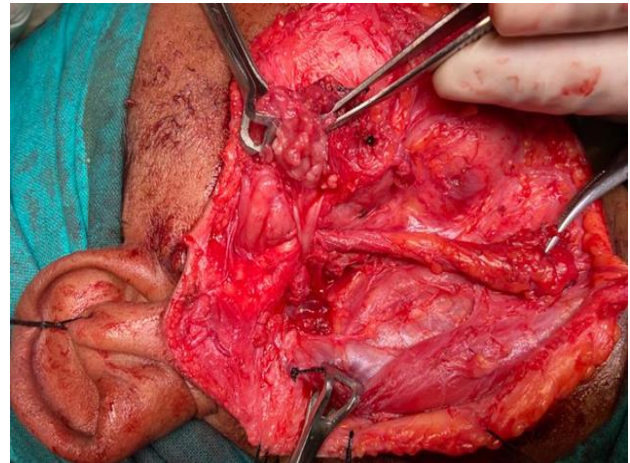


Figure 2: Exposure of the fistulous tract.

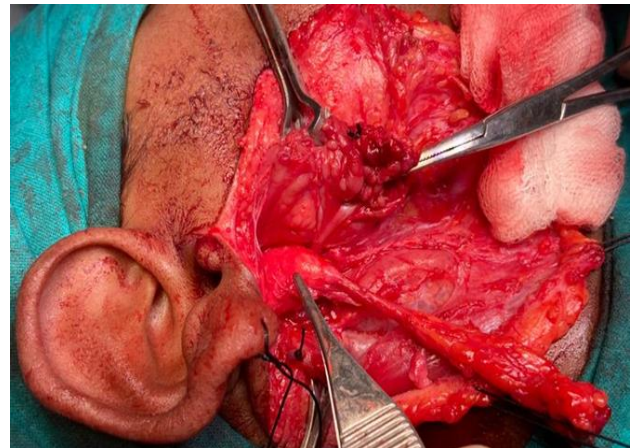


Figure 3: Dissection of the fistulous tract preserving the facial nerve.

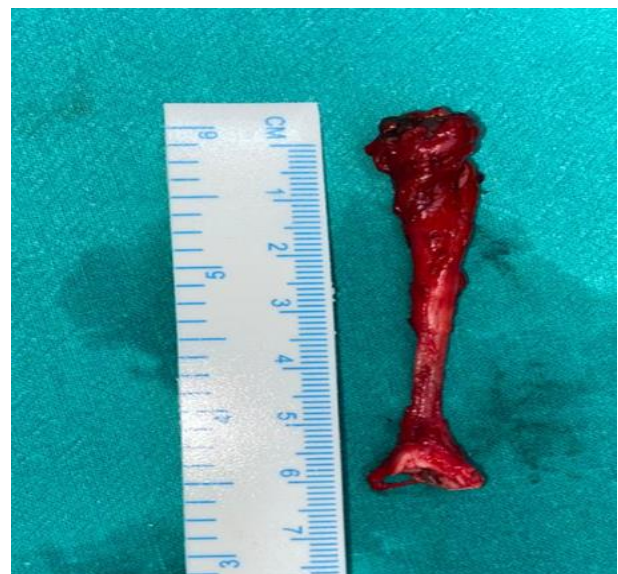

Figure 4: Excised fistulous tract.

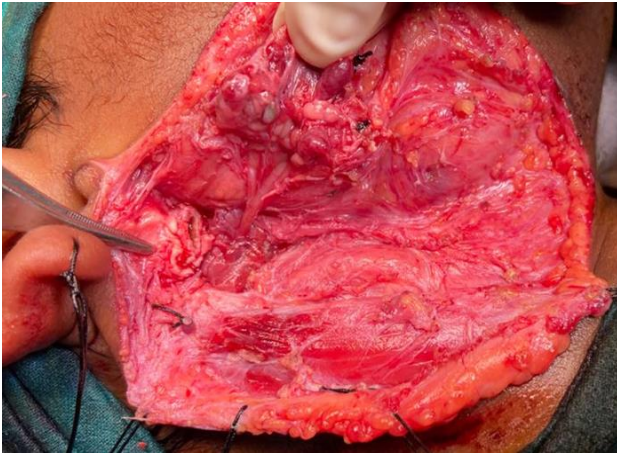


Figure 5: Surgical site after removal of fistula tract showing facial nerve trunk preserved.

Dissection was started from lower elliptical end which was dissected from surrounding tissue and raised upwards along the anterior border of sternocleidomastoid, posterior to submandibular salivary gland, further traversing medial to parotid gland and facial nerve trunk (Figures 2-5).

With preservation of all the aforementioned structures, upper end of fistula was traced which was just lateral to right external auditory canal in the auricle. Entire fistula tract, nearly 6.5 cm in length was excised and sent for histopathological evaluation. Patient was discharged on postoperative day 4, intravenous antibiotics were administered. Histopathological analysis revealed skin with underlying tissue containing fistulous tract lined by stratified squamous epithelium with adnexa.

Oral antibiotics were advised and patient was called for follow up on post-operative day 7 for suture removal. On follow up, surgical site was healthy. Further monthly follow-up was advised.

DISCUSSION

First branchial cleft anomalies can appear at any age but are rare. The age at presentation varies and was stated as 19 years in one case.¹ They can be in the form of cysts, sinus or fistula; cysts being the commonest.⁶ Common clinical presentation are pre-auricular swelling (24%), parotid swelling (36%) or cervical region swelling (41%).⁷ In our case, it was a fistulous opening that presented as discharging tract in upper part of neck. The Work classification system is widely quoted which classifies first branchial cleft anomalies into two types.⁸ Type 1 anomalies present as a cystic mass with ectodermal origin, with squamous epithelium but no skin adnexa or cartilage remnants. Type 2 present as cysts, sinuses, or fistula tracts and are of mixed ectodermal and mesodermal origin. They at times pass through the parotid either superficial or deep to the facial nerve, sometimes the tract may end in cartilage segment of

external auditory canal.¹⁻³ In our case, it was found to be traversing medial to facial nerve reaching up to the right external auditory canal. Imaging studies can help in determining the appropriate surgical approach. Prior drainage or rupture of cystic variant may lead to scar formation or fistula formation. The reported recurrence rate is as high as 14-22%.⁹ Definitive treatment for such anomalies is surgical excision where surgical plan needs to be tailored according to the tract traversed by the sinus or fistula. Key to complete excision is keeping the tract, cyst or fistula intact. Preservation of facial nerve is another key fragment in these surgeries for which sometimes the removal of superficial lobe of parotid gland is required with identification of facial nerve which is to be tailored specifically for each case.

CONCLUSION

First branchial cleft anomalies are rare but are a potential differential diagnosis when a patient presents with swelling over upper lateral neck or around the external ear. Management include early diagnosis, control of infection and complete excision with facial nerve preservation. Surgical approach should be based on the clinical examination, imaging and clinical course; and there is a need to safely identify facial nerve in almost all cases.

Funding: No funding sources

Conflict of interest: None declared

Ethical approval: Not required

REFERENCES

1. Chavan S, Deshmukh R, Karande P, Ingale Y. Branchial cleft cyst: a case report and review of literature. *J Oral Maxillofacial Pathol.* 2014;18:150.
2. Bajaj Y, Ifeacho S, Tweedie D, Albert DM, Cochrane LA, Wyatt ME. Branchial anomalies in children. *Int J Pediatric Otorhinolaryngol.* 2011;758:1020-3.
3. Shinn JR, Purcell PL, Horn DL, Sie KC, Manning S. First branchial cleft anomalies: otologic manifestations and treatment outcomes. *Otolaryngol Head Neck Surg.* 2015;152:506-12.
4. Arvind K, Vijayalakshmi R. A type 1 Branchial cleft cyst masquerading as parotid tumour. *Natl J Maxillofac Surg.* 2014;5:84-5.
5. Quintanilla-Dieck L, Virgin F, Wootten C, Goudy S, Penn E. Surgical Approaches to First Branchial Cleft Anomaly Excision: A Case Series. *Case Reports Otolaryngol.* 2016;3902974.
6. Waldhausen JH. Branchial Cleft and arch anomalies in children. *Semin Pediatr Surg.* 2006;15:64-9.
7. Triglia JM, Nicollas R, Ducroz V, Koltai PJ. First branchial cleft anomalies: A study of 39 cases and review of literature. *Arch Otolaryngol Head Neck Surg.* 1998;124:291-5.
8. Work WP. Newer concepts of first branchial cleft defects. *Laryngoscope.* 1972;82:1581-93.

9. Goudakos JK, Blioskas S, Psillas G, Vital V, Markou K. Duplication of the external auditory canal: two cases and a review of the literature. *Case Reports in Otolaryngol.* 2012;ID924571:4.

Cite this article as: Mehta R, Mishra A, Nagarkar NM, Singh V. First branchial cleft fistula: a case report. *Int J Otorhinolaryngol Head Neck Surg* 2020;6:1568-71.