

Original Research Article

Postoperative mastoid cavity problems: a tertiary care centre experience

Aditiya Saraf, Raies Ahmad*, Deep Jyoti, Parmod Kalsotra

Department of ENT and Head and Neck Surgery, SMGS Hospital, Government Medical College Jammu, Jammu and Kashmir, India

Received: 17 May 2020

Accepted: 04 July 2020

***Correspondence:**

Dr. Raies Ahmad,
E-mail: raies987@gmail.com

Copyright: © the author(s), publisher and licensee Medip Academy. This is an open-access article distributed under the terms of the Creative Commons Attribution Non-Commercial License, which permits unrestricted non-commercial use, distribution, and reproduction in any medium, provided the original work is properly cited.

ABSTRACT

Background: Aims and objectives of the study were to find incidence and causes for postoperative mastoid cavity problems after modified radical mastoidectomy.

Methods: The present prospective study was conducted in the Department of ENT, SMGS Hospital, GMC Jammu from September 2017 to February 2020 on 25 patients with active squamosal chronic otitis media. All patients underwent modified radical mastoidectomy after taking written and informed consent. A period of 3 months postoperatively was taken as a healing time for complete epitheliasation of cavity. Any patient presenting with symptoms beyond this period was considered a cavity problem case.

Results: Out of 25 patients, 9 patients had cavity problems, the incidence of cavity problem being 36%. Perforation in tympanic membrane was seen in 7 patients (77%) and high facial ridge in 2 patients (22%). There was no case of narrow meatoplasty in our study.

Conclusions: Incidence of mastoid cavity problems can be reduced if the open cavity procedures are executed adequately.

Keywords: Cavity, Meatoplasty, Mastoid

INTRODUCTION

Open mastoid cavity procedures are a form of surgical treatment of chronic otitis media and can be broadly defined as those procedures requiring the removal of posterior exterior canal wall. Depending on how the middle ear and disease are managed, it can be identified by many names such as canal wall down mastoidectomy, modified radical mastoidectomy, Bondy mastoidectomy or radical mastoidectomy.¹

In 1873, Von Troltsch suggested that Schwartze's simple mastoidectomy needed to be modified to reduce persistent otorrhoea after initial surgery.^{2,3} Von Bergmann applied the term 'radical' to any procedure in which posterior and superior canal walls were removed.⁴ Bondy described a modification of this radical procedure in which superior

and part of posterior wall were removed without disturbing intact tympanic membrane, ossicles or tympanic cavity.⁵ Introduction of tympanoplastic techniques by Zollner and Wullstein directed attention to reconstruction of sound conducting apparatus of middle ear and led to emergence of modified radical mastoidectomy (MRM).^{6,7}

It is very rare for any surgeon to treat cholesteatoma medically, making surgery the principle management of cholesteatoma. MRM is indicated in cases with unresectable disease, unreconstructable posterior canal wall, inadequate patient follow up and poor Eustachian tube function.¹

The purpose of every open cavity procedure is to exteriorize the mastoid cavity for future monitoring of

recurrent cholesteatoma, provide drainage for unresectable temporal bone infection and occasionally, provide exposure for difficult to access areas of temporal bone. Supporters of open cavity techniques stress upon the fact that even if some disease is left behind, it can be removed in subsequent visits and also, there is better ventilation of cavity which has a drying effect.⁸

Normally, the open cavity heals by secondary intention. Failure of healing and complete epithelisation leads to various cavity problems such as vertigo, otorrhoea, hearing impairment, wax/debris collection, dependency on doctor for repeated cleaning of cavity, difficulty in wearing hearing aids and residual/ recurrent disease.⁹

There are very few studies in medical literature regarding the analysis of post-mastoidectomy cavity problems. We, with our study, aimed to find incidence and causes for postoperative mastoid cavity problems after MRM.

METHODS

The present prospective study, after approval by Institutional ethics committee, was conducted in the Department of ENT, SMGS Hospital, GMC Jammu from September 2017 to February 2020 on 25 patients.

Inclusion criteria

Patients with chronic otitis media active squamosal disease (cholesteatoma).

Exclusion criteria

Patients with intratemporal or intracranial complications, patients with active foci of infection in nose, paranasal sinuses and throat, patients with malignancy of temporal bone.

All patients were subjected to relevant clinical history and general physical examination. All patients underwent otoscopic examination and examination under microscope. All patients were subjected to routine blood investigations and X-ray mastoid Schuller’s view. In all patients, pure tone audiometry was done.

All patients underwent modified radical mastoidectomy after taking written and informed consent. In all patients, postauricular incision was given, retraction of soft tissues and exposure of mastoid area was done. Removal of cortical bone and exposure of antrum was done. Removal of bridge (superior osseous wall) was done and facial ridge (deeper part of posterior meatal wall) was lowered. Disease was removed and mastoid cavity was smoothed with polishing burs. Tympanoplasty with ossicular reconstruction was done. Meatoplasty was done. Wound was closed and mastoid dressing was done. Patients were kept in hospital for 7 days on antibiotic cover with stitch removal on 7th postoperative day.

A period of 3 months was taken as a healing time for complete epithelization of cavity. Any patient presenting with symptoms beyond this period was considered a cavity problem case. Postoperatively, patients were called every 2 weekly for 3 months and 3 weekly for next two months. At all follow-up visits, otoscopic examination was done.

All data was analysed using statistical package for the social science version 20.

RESULTS

The majority of patients were in the age group of 21-30 years (56%), with mean age of presentation being 29.4 years.

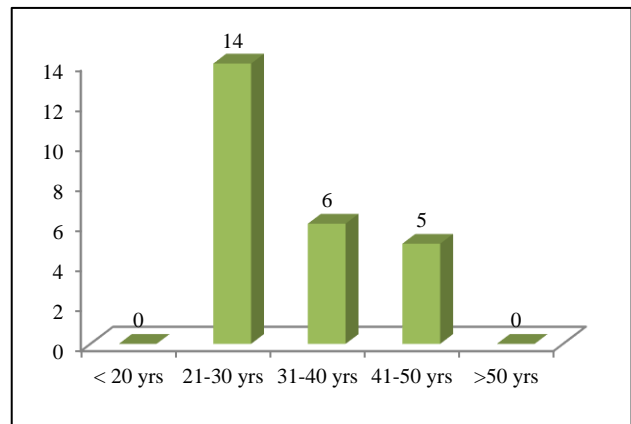


Figure 1: Age distribution.

Out of 25 patients, 17 were males (68%) and 8 were females (32%).

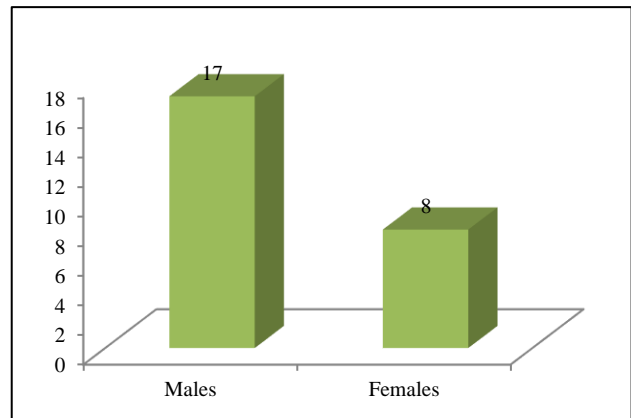


Figure 2: Sex distribution.

Out of 25 patients, 9 patients had cavity problems, the incidence of cavity problem being 36%.

Out of 9 patients, 8 cases had cavity problem in the form of persistent otorrhoea (88%), 5 patients had impacted debris/wax (55%), 3 patients had complaint of hearing

impairment (33%) and 1 patient had persistent vertigo (11%).

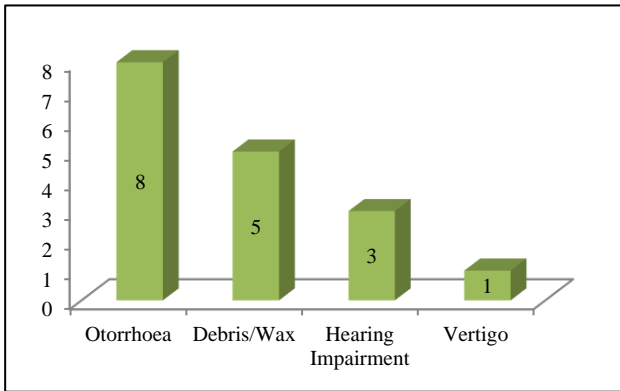


Figure 3: Mastoid cavity problems.

As far as cause of cavity problem was concerned, perforation in tympanic membrane was seen in 7 patients (77%) and high facial ridge in 2 patients (22%). There was no case of narrow meatoplasty in our study.

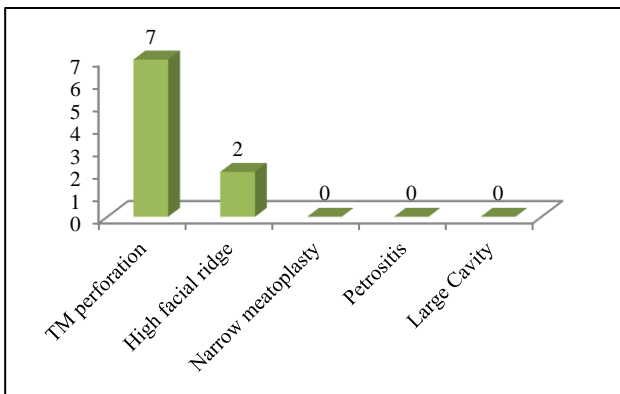


Figure 4: Causes for cavity problems.

All cavity problem patients were given topical antibiotic-steroid medication and systemic antibiotic. No case was surgically treated.

DISCUSSION

The key to success in otological surgery is not whose technique one uses, but how well one uses it and one’s own ability and judgement. A perfectly performed primary canal wall down mastoidectomy with tympanoplasty not only results in a trouble free and water tolerant ear, but also good hearing results.¹⁰

The aims of surgery for cholesteatoma are eradication of disease, hearing improvement and a well epithelialized, self-cleansing mastoid cavity. The reasons for a problem mastoid cavity can be high facial ridge, sump in cavity below floor of external auditory canal, small external auditory meatus and perforation in tympanic membrane.¹¹

The majority of patients were in the age group of 21-30 years (56%), with mean age of presentation being 29.4 years. Vartianen et al and Kuo et al also reported majority of patients in this age group.^{12,13}

Out of 25 patients, 17 were males (68%) and 8 were females (32%). Similar male preponderance was shown by Bhatia et al in their study.¹⁴ However, Chhapola et al reported equal sex incidence.¹⁵

Out of 25 patients, 9 patients had cavity problems, the incidence of cavity problem being 36%. Our finding was comparable to study done by Kos et al, who reported an incidence of 30%.¹⁶ However, Rajan et al in their study showed an incidence of 26%.¹⁷

Out of 9 patients, 8 cases had cavity problem in the form of persistent otorrhoea (88%), 5 patients had impacted debris/wax (55%), 3 patients had complaint of hearing impairment (33%) and 1 patient had persistent vertigo (11%). Rajan et al also showed otorrhoea to be most common complaint.¹⁷ Exposed middle ear and Eustachian tube area was a major factor for persistent discharge. Vertigo may occur due to stimulation of horizontal semicircular canal because of a single cavity.

The most common cause for mastoid cavity problem in our study was perforation in tympanic membrane, seen in 7 patients (77%), which was consistent with study conducted by Rajan et al.¹⁷ The tympanic membrane should remain intact so that there is no communication between the mastoid cavity and mesotympanum and Eustachian tube orifice. Also, high facial ridge was observed in 2 patients (22%), which was consistent with Rajan et al.¹⁷ However, Sade in their study revealed high facial ridge in 80% of cases.¹⁸ The cavity must be rounded with facial ridge lowered down to level of floor of external auditory canal for effective migration of epithelium. There was no case of narrow meatoplasty in our study (0%). Rajan et al showed narrow meatoplasty in about 3% cases while Vartianen et al had narrow meatoplasty in 27% of their study cases.^{12,17}

CONCLUSION

A chronically discharging ear is a source of worry to otologists for centuries due to high rate of morbidities. Though ours was a study with limited sample size (n=25), it can be concluded that incidence of cavity problems can be reduced if the open cavity procedures are executed adequately. Persistent discharge was most common mastoid cavity problem in our study and tympanic membrane perforation was most common cause of cavity problem.

Funding: No funding sources

Conflict of interest: None declared

Ethical approval: The study was approved by the Institutional Ethics Committee

REFERENCES

1. Kveton JF. Open cavity mastoid operations. In: Gulya AJ, Minor LB, Poe DS, editors. *Glasscock Shambaugh Surgery of the Ear*. 6th ed. PMPH publishers; 2010: 515-528.
2. by Tröltsch AF. *Textbook of ear medicine: including the anatomy of the ear*. FCW Vogel; 1881.
3. Schwartz HH, Eysell UA. About the artificial opening of the mastoid process. *Arch Ear Hearing*. 1873;7:157.
4. Von Bergmann E. *Surgical treatment of the diseases of brain*. Berlin; 1889.
5. Bondy G. Total chiseling with preservation of eardrum and ossicles. *Msch Ehrenheilkunde*. 1910;44:15
6. Zollner F. The radical operation with special reference to the hearing function. *Zschr Laryngol Rhinol Otol*. 1951;30:104.
7. Wullstein H. Functional operations in the middle ear with the help of the free split-flap graft. *Arch Ears Noses U Larynx*. 1952;161:422.
8. Matsuda Y, Kurita T, Ueda Y. Effects of tympanic membrane perforation on middle ear sound transmission. *J Laryngol Otol*. 2014;123:81-9.
9. Smith JA, Danner CJ. Complications of chronic otitis media and cholesteatoma. *Otolaryngol Clin North Am*. 2010;39:1237-55.
10. Sheehy JL. Cholesteatoma surgery: canal wall down procedures. *Ann Otol Rhinol Laryngol*. 1988;97:30-5.
11. Browning GG, Merchant SN, Kelly G. Chronic otitis media. In: Gleeson M, editor. *Scott Brown's Otorhinolaryngology, head and neck surgery*, 7th ed. Hodder Arnold publishers; 2008: 3396-3439.
12. Vartianen E. Ten year results of canal wall down mastoidectomy for acquired cholesteatoma. *Auris Nasus Larynx*. 2001;27:227-9.
13. Kuo CY, Huang BR, Chen HC, Shih CP, Chang WK, Tsai YL, et al. Surgical results of retrograde mastoidectomy with primary reconstruction of the ear canal and mastoid cavity. *Biomed Res Int*. 2015: 517035.
14. Bhatia S, Karmarkar S, DeDonato G, Mutlu C, Taibah A, Russo A, et al. Canal wall down mastoidectomy: causes of failure, pitfalls and their management. *J Laryngol Otol*. 1995;109(7):583-9.
15. Chhapola S, Matta I. Mastoid obliteration versus open cavity: a comparative study. *Indian J Otolaryngol Head Neck Surg*. 2014;66(1):207-13.
16. Kos MI, Castrillon R, Montandon P. Anatomic and functional long term results of canal wall down mastoidectomy. *Ann Otol Rhinol Laryngol*. 2004;113:872-6.
17. Rajan D, James S. A prospective analysis of post mastoidectomy cavity complications. *Int J Otorhinolaryngol Head Neck Surg*. 2019;5:1566-9.
18. Sade J. Treatment of retraction pockets and cholesteatoma. *J laryngol Otol*. 1982;96:685-704.

Cite this article as: Saraf A, Ahmad R, Jyoti D, Kalsotra P. Postoperative mastoid cavity problems: a tertiary care centre experience. *Int J Otorhinolaryngol Head Neck Surg* 2020;6:1500-3.