

Case Report

Pseudo-Duane's retraction syndrome: a rare clinical entity

Sobhana Chandran*

Department of ENT, Topiwala National Medical College and B.Y.L Nair Hospital, Mumbai, Maharashtra, India

Received: 15 May 2020

Accepted: 12 June 2020

***Correspondence:**

Dr. Sobhana Chandran,

E-mail: dr.sobhanachandran@gmail.com

Copyright: © the author(s), publisher and licensee Medip Academy. This is an open-access article distributed under the terms of the Creative Commons Attribution Non-Commercial License, which permits unrestricted non-commercial use, distribution, and reproduction in any medium, provided the original work is properly cited.

ABSTRACT

Studies of sequelae of isolated medial orbital wall fractures show that the majority of patients with this condition are often asymptomatic, which makes the diagnosis based only on clinical grounds difficult. One of the rare complications of this entity is pseudo-Duane's retraction syndrome, which is characterised by horizontal diplopia, restricted abduction with or without limited adduction, accompanied by narrowing of the palpebral fissure, globe retraction and pseudo ptosis on abduction. This is a case report of a 46-year-old female who developed pseudo-Duane's retraction syndrome following trauma to her left orbit. She presented with left eye pain, diplopia, horizontal gaze restrictions, left eye ecchymosis and enophthalmos. Careful history taking and thorough ophthalmic examination including forced duction test along with radiological imaging helped clinch this diagnosis. Timely intervention by an endoscopic approach to release the medial rectus muscle entrapped within the fracture resolved the patient's symptoms.

Keywords: Medial orbital wall fracture, Pseudo-Duane's retraction syndrome, Forced duction test

INTRODUCTION

Isolated orbital medial wall fractures are rare due to the multiple bony septa within the ethmoid sinus that provide reinforcement and support to the thin medial wall. Patients with fewer ethmoid air cell septa and a larger medial wall area are more likely to develop medial wall fractures than floor fractures.¹ They are usually asymptomatic.

Entrapment of the medial rectus muscle within a medial orbital wall fracture is the most common cause of pseudo-Duane's retraction syndrome.² This happens when the initial blow causes the orbital contents to displace into the sinus through the fractured bone forming a hinge. Once the pressure from the blow is released, the bone returns to its original position, trapping the displaced orbital contents within the ethmoid sinus.³ The following is an interesting case of a middle-aged patient who presented with this condition following trauma to her orbit.

CASE REPORT

A 46-year-old female, with a history of blunt force trauma to her left orbit 2 days prior to her visit to the ENT OPD, presented with complaints of left eye pain, double vision on looking to the right and restricted adduction movement. Before the trauma, the patient had no vision complaints or history of squint. There was no history of recent epistaxis or loss of consciousness. General examination was unremarkable. A detailed ophthalmic examination of the left eye revealed subconjunctival ecchymoses with minimal periorbital oedema, mild enophthalmos, mild restriction of abduction movement with minimal palpebral fissure narrowing on attempted lateral gaze, with severe restriction of adduction movement and increased diplopia and pain on attempting to do so, suggestive of pseudo-Duane's retraction syndrome (Figure 1). Right eye examination and extraocular movements were normal. Visual acuity and colour vision were normal in both eyes. Rest of the ENT examination was normal.

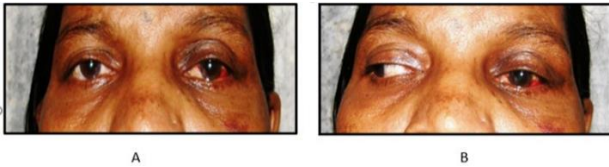


Figure 1 (A and B): Restricted adduction movement of left eye with left subconjunctival ecchymosis

Computed tomography (CT) with contrast of paranasal sinuses and orbit with fine slices was done. The scan revealed fracture of the left lamina papyracea with medial rectus muscle thickening and entrapment within the fracture and mild orbital enophthalmos (Figure 2). Rest of the bony orbital wall and orbital contents were intact and unremarkable. Based on the history, clinical examination and radiological findings, it was decided to do an endoscopic endonasal approach for reduction of medial orbital wall fracture and release of the entrapped muscle under general anaesthesia.

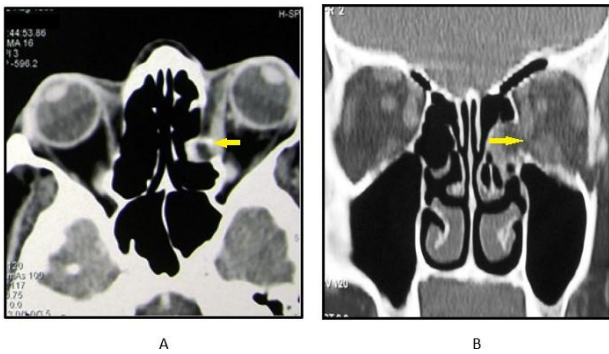


Figure 2 (A and B): Axial and coronal cuts on CT scan showing left medial orbital wall fracture with medial rectus entrapment and thickening.

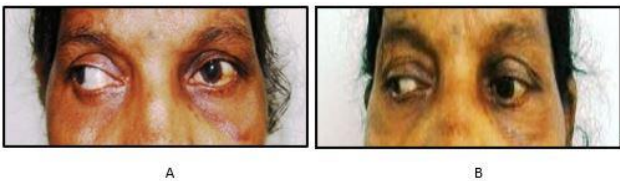


Figure 3 (A and B): Left eye adduction movement-preoperative and postoperative.

A forced duction test performed just prior to the surgery was positive and showed marked restriction of adduction movement of left eye. The patient underwent left sided uncinectomy, middle meatal antrostomy, anterior and posterior ethmoidectomy to have the lamina papyracea carefully delineated. The fractured part of the lamina papyracea was identified and bone bits were carefully removed to free the entrapped medial rectus. There was no significant orbital fat prolapse. The post-operative period was uneventful and immediate partial improvement in extraocular movements were noted. The patient was given 3 days of intravenous antibiotics,

systemic steroids and analgesics and discharged on postoperative day 3. Follow up nasal endoscopy in ENT OPD one week after surgery showed a well healing nasal cavity with improvement in left eye extraocular movements and almost complete resolution of orbital symptoms (Figure 3). The patient had normal range of extraocular movements and complete resolution of symptoms within a month following surgery.

DISCUSSION

Duane's retraction syndrome, as described by Alexander Duane in 1905, is a rare congenital, non-progressive eye movement disorder. It is characterised by marked restriction of abduction of the eye with partial restriction of adduction, along with eye ball retraction and narrowing of palpebral fissure on adduction.⁴ In 1976, Thomas D. Duane described another entity, the pseudo-Duane's retraction syndrome, with a similar yet different set of symptoms, in which abduction of the affected eye is possible to some extent, with or without restriction of adduction, and the globe retraction and narrowing of the palpebral fissure occurs on abduction.²

The aetiology is also completely different for the two entities. In Duane's retraction syndrome, the lateral movement anomaly results from the failure of the abducens nucleus and nerve to fully innervate the lateral rectus muscle; globe retraction occurs as a result of abnormal innervation of the lateral rectus muscle by the oculomotor nerve.⁵ Pseudo-Duane's retraction syndrome has been reported to be caused by acquired or congenital factors that affect the functioning of the medial rectus muscle. Entrapment of the medial rectus muscle in a medial orbital wall fracture has been known to be the most common cause.²

There are two primary theories on the mechanism of fractures to the medial orbital wall, namely 'the buckling theory' and 'the hydraulic theory'. The buckling theory holds that the transmission of force from an anterior blow that deforms the bony rim, but does not fracture it, causes the thinner medial orbital wall to fracture. According to the hydraulic theory, a traumatic impact to the soft tissue of the orbit displaces the tissue into the orbital cavity, resulting in fracture of the orbital bones.⁶ In most cases, a combination of the two may be the cause of fracture.

Medial wall fractures should be suspected in all cases of blunt trauma to orbit. Such patients should undergo complete ophthalmic examination with special attention to extraocular movements and globe displacement. Though patients may present with periorbital oedema, ecchymosis, epistaxis, diplopia or other symptoms, most patients are asymptomatic and fracture may be an incidental finding on a CT scan.⁷ Various degrees of limitation of abduction and adduction are noted in patients with medial rectus entrapment following medial orbital wall fracture. The degree of abduction limitation depends on the amount of "slack" medial rectus anterior

to the site of entrapment. If there is a surplus of muscle length anterior to the entrapment site, then there will be lesser restriction of abduction and vice versa. Adduction deficit is due to ischemia and/or neuropraxia of the entrapped medial rectus muscle along with displacement of the muscle's point of origin from the orbital apex to the fracture site following trauma.⁸

Patients presenting with Pseudo-Duane's retraction syndrome due to medial rectus entrapment secondary to trauma require surgical intervention at the earliest as there may be reduced blood flow and nerve compression leading to permanent injury to the muscle.³ Delay in surgical intervention beyond 2 weeks could cause retraction to persist due to scarring of the orbital tissue and contraction of the tissues around the medial rectus despite freeing the orbital tissues.² Forced duction tests performed at the beginning and end of surgery will help to establish the degree of entrapment of the medial rectus and to indicate whether the condition has been resolved with the attempted surgical intervention, respectively.⁹

Other rare causes of pseudo-Duane's retraction syndrome have also been reported. Murthy et al reported a case of an 18-year-old female with recent onset diplopia on right gaze with symptoms of pseudo-Duane's.¹⁰ Ultrasound B-scan showed evidence of cysticercosis of right medial rectus muscle which resolved within 2 weeks on taking oral albendazole and prednisolone. Khan et al reported a case of a 28-year-old male who developed similar symptoms after undergoing multiple surgeries for recurrent pterygium.¹¹ A case of pseudo-Duane's retraction syndrome was reported by Duane et al which was secondary to orbital metastasis.⁹

Congenital cases of pseudo Duane's retraction syndrome are unusual. Lee et al reported a case of a 6-year-old girl with congenital squint with no history of forceps delivery or orbital trauma. CT and magnetic resonance imaging were normal but forced duction test showed marked restriction of abduction of left eye. Tight contracture of the medial rectus was seen intraoperatively which was released with tenotomy and the child's squint improved.¹² Chatterjee et al reported a rare case of bilateral pseudo-Duane's retraction syndrome in a 21-year-old female with congenital squint and no trauma history which was corrected with the release of fibrous bands arising from bilateral medial recti intraoperatively.¹³

CONCLUSION

Isolated fractures of the medial wall of orbit are uncommon and often missed. In this case, a detailed history taking along with thorough clinical examination, including a complete ophthalmic examination, helped identify pseudo-Duane's retraction syndrome which raised suspicion of a medial orbital wall fracture which was confirmed on CT scan. Timely intervention by

endoscopic approach to release the entrapped medial rectus helped relieve the patient's symptoms and avoid permanent restriction of ocular motility.

Funding: No funding sources

Conflict of interest: None declared

Ethical approval: Not required

REFERENCES

1. Song WK, Lew H, Yoon JS, Oh MJ, Lee SY. Role of medial orbital wall morphologic properties in orbital blow-out fractures. *Investigative Ophthalmol Visual Sci.* 2009;50(2):495-9.
2. Gittinger JW, Jr, Hughes JP, Suran EL. Medial orbital wall blow-out fracture producing an acquired retraction syndrome. *J Clin Neuroophthalmol.* 1986;6:153-6.
3. Jordan DR, Allen LH, White J, Harvey J, Pashby R, Esmaeli B. Intervention within days for some orbital floor fractures: the white-eyed blowout. *Ophthal Plast Reconstr Surg.* 1998;14:379-90.
4. DeRespinis PA, Caputo AR, Wagner RS, Guo S. Duane's retraction syndrome. *Surv Ophthalmol.* 1993;38:257-88.
5. Kekunnaya R, Negalur M. Duane retraction syndrome: causes, effects and management strategies. *Clin Ophthalmol.* 2017;11:1917-30.
6. Warwar RE, Bullock JD, Ballal DR, Ballal RD. Mechanisms of orbital floor fractures: a clinical, experimental, and theoretical study. *Ophthal Plast Reconstr Surg.* 2000;16:188-200.
7. Nolasco FP, Mathog RH. Medial orbital wall fractures: classification and clinical profile. *Otolaryngol Head Neck Surg.* 1995;112:549-56.
8. Brannan PA, Kersten RC, Kulwin DR. Isolated medial orbital wall fractures with medial rectus muscle incarceration. *Ophthal Plast Reconstr Surg.* 2006;22:178-83.
9. Duane TD, Schatz NJ, Caputo AR. Pseudo-Duane's retraction syndrome. *Trans Am Ophthalmol.* 1976;74:122-9.
10. Murthy R. Inverse Duane's retraction syndrome following myocysticercosis. *Indian J Ophthalmol.* 2008;56(1):89-90.
11. Khan AO. Inverse globe retraction syndrome complicating recurrent pterygium. *Br J Ophthalmol.* 2005;89(5):640-1.
12. Lew H, Lee JB, Kim HS, Han SH. A case of congenital inverse Duane's retraction syndrome. *Yonsei Med J.* 2000;41(1):155-8.
13. Chatterjee PK, Bhunia J, Bhattacharyya I. Bilateral inverse Duane's retraction syndrome-a case report. *Indian J Ophthalmol.* 1991;39:183-5.

Cite this article as: Chandran S. Pseudo-Duane's retraction syndrome: a rare clinical entity. *Int J Otorhinolaryngol Head Neck Surg* 2020;6:1387-9.