

Original Research Article

Endoscopic interlay tympanoplasty: our experience

Sajitha Bhaskaran K.*, Naveen Kumar

Department of ENT, SIMSRC, Bangalore, Karnataka, India

Received: 05 May 2020

Revised: 08 June 2020

Accepted: 09 June 2020

*Correspondence:

Dr. Sajitha Bhaskaran K.,

E-mail: sajitharijesh@gmail.com

Copyright: © the author(s), publisher and licensee Medip Academy. This is an open-access article distributed under the terms of the Creative Commons Attribution Non-Commercial License, which permits unrestricted non-commercial use, distribution, and reproduction in any medium, provided the original work is properly cited.

ABSTRACT

Background: Chronic otitis media is treated conventionally by tympanoplasty using a temporalis fascia graft using a microscope, through a post aurial approach. The present study comprises of 50 cases of chronic otitis media, which were treated by endoscopic interlay technique of tympanoplasty, combining two novel approaches in otological surgery.

Methods: Total of 50 patients were studied, with in a period of one year at our institution. All of them underwent type I endoscopic tympanoplasty by interlay method. All of whom were followed up for 6 months. Patients were evaluated in terms of graft uptake, improvement in hearing and rate of complications.

Results: In the present study, we have recorded a graft uptake rate of 98%. The mean post operative air bone gap at the end of 6 months was 0.9 dB ($p=0.001$) which was statistically highly significant.

Conclusions: Endoscopic interlay tympanoplasty is a novel and preferred technique, which could be implemented in all cases of dry chronic otitis media.

Keywords: Chronic otitis media, Endoscopic tympanoplasty, Interlay

INTRODUCTION

Chronic otitis media (COM) is a persistent inflammation that causes irreversible changes in the mucosa of middle ear and mastoid cavity. It constitutes a major health problem in the developing world both in children and adults. Tympanoplasty was first introduced by Berthold for repair of tympanic membrane and was further popularized and developed by Wullstein and Zollner. There are various techniques of tympanoplasty adopted by various otologists which include underlay, overlay, interlay, double breasting, gel film and sandwich technique. The most commonly preferred method is underlay technique where in graft is placed medial to the mucosal layer, where as in interlay technique-graft is placed between the fibrous layer and the mucosal layer of the drum remnant. The benefits of using interlay

technique are there is no reduction in middle ear space anterior blunting and lateralization of graft also can be avoided.¹

Microscopes have been used effectively in otological practice since ages and the use of endoscopes was limited to endonasal and sinus surgeries. However, in recent past endoscopes were gradually introduced into otological practice, because of better visualization of the hidden areas of middle ear.² Eventually endoscopes had its implications in otological surgeries and also are now preferred by many otologists in tympanoplasty. In the present study, an attempt is made to combine these two novel techniques in tympanoplasty, which is endoscopic type-1 interlay tympanoplasty, using temporalis fascia as graft.

METHODS

The present study comprised of a total of 50 patients, with in a period of one year at Sapthagiri Institute of Medical Sciences, Bangalore. All of them underwent type I endoscopic tympanoplasty by interlay method.

The duration of prospective study was 1 year, December 2018 to January 2020.

Inclusion criteria

Patients diagnosed with chronic otitis media, mucosal type with dry central perforation were included.

Exclusion criteria

Patients with active ear disease, any ossicular necrosis, tympanosclerosis or any co morbidities were excluded.

Detailed clinical history and examination was done in all cases, necessary laboratory investigations, otoendoscopy, pure tone audiometry and radiological investigations were performed. Informed consent was obtained from all patients.

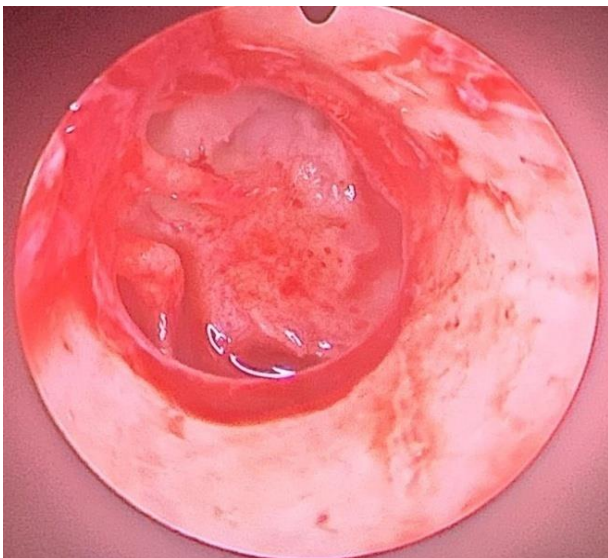


Figure 1: Tympanomeatal flap elevated by interlay technique.

All the cases underwent surgery under local anesthesia by transcanal approach, using temporalis fascia, which was harvested by a small 2 cm incision in temporal region. Under endoscopic guidance transcanal incision was put and tympanomeatal flap was elevated circumferentially except at the lateral process of malleus region. Once the level of annulus was reached the fibro squamous layer alone was lifted up leaving behind the mucosal layer using a curved blunt hook (Figure 1). Middle ear was then inspected for ossicular continuity, Eustachian tube orifice and round window reflex was confirmed. Malleus was skeletonised, Temporalis fascia was then grafted in

such a fashion that it rested on the mucosal layer of tympanic membrane under the handle of malleus (Figure 2). Tympanomeatal flap was then repositioned and canal filled with antibiotic impregnated gelfoam and medicated ointment pack.

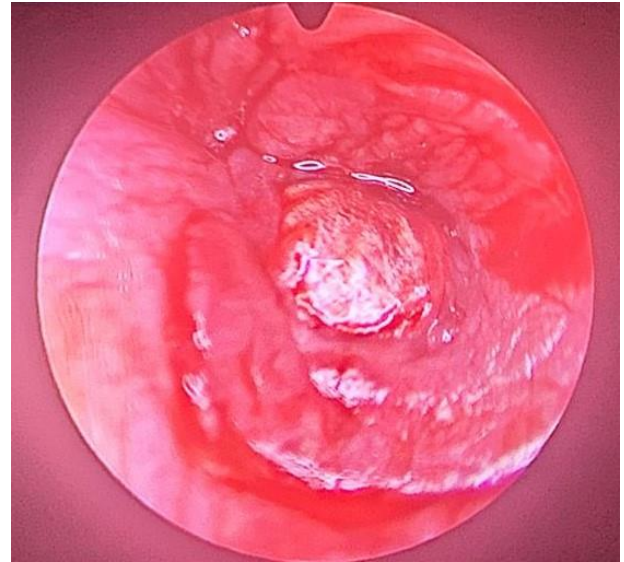


Figure 2: Tympanic membrane grafting done by interlay method.

RESULTS

The 50 cases included in the present study comprised 32 (64%) male and 18 (36%) female patients. The age of the patients ranged from 15 to 57 years, with the mean age being 33.6 years with a standard deviation of 9.64 (Table 1).

Maximum number (54%) of patients had complaints of both ear discharge and hearing loss while there was history of discharge and hearing loss only in 34 and 12% respectively.

Table 1: Age-wise distribution of the patients.

Age group (in years)	Number of patients	Percentage
15-25	9	10
26-35	18	24
36-45	17	34
45-55	6	20
Total	50	100

Table 2: Preoperative air-bone gap of the patients.

Preoperative ABG	Number of patients	Percentage
11-20	27	54
21-30	13	26
31-40	10	20
Total	50	100

The mean pre-operative air bone gap (ABG) in our study was 19.5 dB with a standard deviation of 7.9 dB.

The post operative ABG closure at the end of 6 months was as follows. In the 6th month 44 (88%) cases had complete AB gap closure ($p=0.001$), 3 (6%) cases had a residual AB gap of 5 dB and 10 dB each ($p=0.001$), all of which were statistically significant.

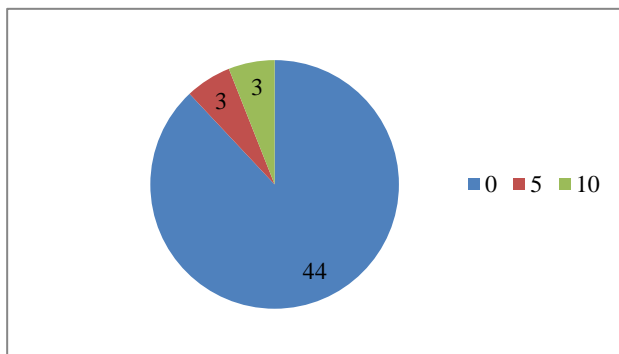


Figure 3: Post operative air-bone gap of the patients.

In the present study, out of 50 patients, 49 of them had a normal tympanic membrane at the end of 6 months, with a graft uptake rate of 98%.

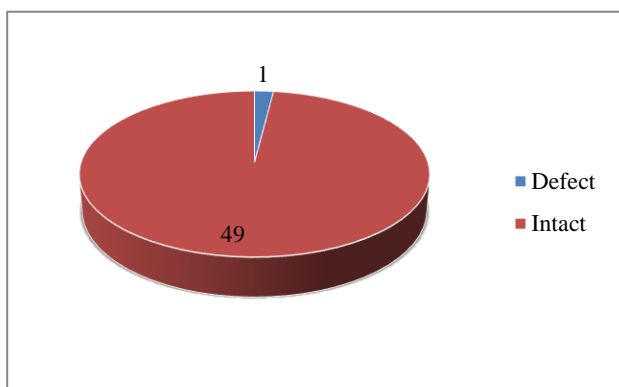


Figure 4: Graft uptake.

DISCUSSION

Endoscopic ear surgery has revolutionized the otological surgeries. Endoscopes provides angled and close up images of middle ear and its hidden areas. It has shorter operation time, is less invasive, shorter hospital stay and improved cosmetic outcome unlike microscopes which gives only the linear view, not of the deep recesses of middle ear.

In the present study, an attempt is made to combine two novel techniques in tympanoplasty, such as endoscope guided interlay technique, which is endoscopic type-1 interlay tympanoplasty, using temporalis fascia as graft.

In the present study, out of 50 cases, 27 patients (54%) had pre operative air bone (A-B) gap within 11-20 dB, 13

cases (26%) had A-B gap within 21-30 dB, 10 cases (20%) had A-B gap in the range of 31-40 dB respectively. The mean pre-operative air bone gap (ABG) in our study was 19.5 dB with a standard deviation of 7.9dB (Table 2).

The post operative ABG closure at the end of 6 months was as follows. In the 6th month 44 (88%) cases had complete AB gap closure ($p=0.001$), 3 (6%) cases had a residual AB gap of 5 dB and 10 dB each ($p=0.001$), all of which were statistically significant.

The mean post operative ABG at the end of 6 months was 0.9 dB ($p=0.001$) which was statistically highly significant.

Sergi et al by underlay technique reported mean post op ABG as 9.9 dB. Lima et al reported the mean ABG closure to be 10.3 dB. 56% achieved complete ABG closure.³ Lee et al reported in their study that postoperative air-bone gap was less than 10 dB in 80.4% cases.¹⁰

In the present study, we have recorded a graft uptake rate of 98%, which is slightly higher than the success rate (96%) reported by Guo et al on 53 patients and Patil et al on 100 patients.^{4,5} Our results were also better than those reported by Komune et al and Kawatra et al who in their respective studies reported the success rate to be 94.2% and 93.3%.^{6,7} Hay et al and Patil et al reported a 91% success rate with interlay myringoplasty, lower as compared to the present study.^{8,9}

CONCLUSION

The interlay technique of doing type I tympanoplasty has high success rate both in terms of graft uptake as well as ABG closure. The complications are less as compared to other techniques, also endoscopic approach to middle ear and tympanoplasty has given a new perspective to otologists. It gives a good cosmetic outcome and less postoperative morbidity. Therefore, endoscopic tympanoplasty should be preferred over the conventional microscopic approach. Endoscopic interlay tympanoplasty is a novel and preferred technique, which could be implemented in all cases of dry chronic otitis media.

Funding: No funding sources

Conflict of interest: None declared

Ethical approval: The study was approved by the Institutional Ethics Committee

REFERENCES

1. Sharma N, Sharma P, Goyal VP, Sharma KG. Interlay versus underlay type 1 tympanoplasty: a comparative study of the techniques in 100 cases. Int J Otorhinolaryngol Head Neck Surg. 2019;5:64-8.

2. Prajapati BJ, Patel ND, Rai S. Endoscopic transcanal tympanoplasty: a case series. *Int J Otorhinolaryngol Head Neck Surg.* 2018;4:717-20.
3. Sergi B, Galli J, De Corso E, Parrilla C, Paludetti G. Overlay versus underlay myringoplasty: report of outcomes considering closure of perforation and hearing function. *Acta Otorhinolaryngol Ital.* 2011;31(6):366-71.
4. Guo M, Huang Y, Wang J. Report of myringoplasty with interlay method in 53 ears perforation of tympani. *Lin Chuang Er Bi Yan Hou Ke Za Zhi.* 1999;13(4):147-9.
5. Patel J, Aiyer RG, Gajjar Y, Gupta R, Raval J, Suthar PP. Endoscopic tympanoplasty vs microscopic tympanoplasty in tubotympanic csom: a comparative study of 44 cases. *Int J Res Med Sci.* 2015;3(8):1953-7.
6. Komune S, Wakizono S, Hisashi K, Uemura T, Interlay Method For Myringoplasty. *Larynx Auris Nasus.* 1992;19(1):17-22.
7. Kawatra R, Maheshwari P, Kumar G. A comparative study of the techniques of myringoplasty - overlay, underlay & interlay. *IOSR J Dent Med Sci.* 2014;13:12-6.
8. Hay A, Blanshard J, The anterior interlay myringoplasty: Outcome and hearing results in anterior and subtotal tympanic membrane perforations, *Otol Neurotol.* 2014;35(9):1569-76.
9. Patil BC, Misale PR, Mane RS, Mohite AA, Outcome Of Interlay Grafting In Type 1 Tympanoplasty For Large Central Perforation. *Indian J Otolaryngol Head Neck Surg.* 2014;66(4):418-24.
10. Lee P, Kelly G, Mills RP. Myringoplasty: does the size of the perforation matter? *Clin Otolaryngol Allied Sci.* 2002;27:331-4.

Cite this article as: Sajitha BK, Kumar N. Endoscopic interlay tympanoplasty: our experience. *Int J Otorhinolaryngol Head Neck Surg* 2020;6:1274-7.