

## Original Research Article

DOI: <http://dx.doi.org/10.18203/issn.2454-5929.ijohns20203197>

# Comparative evaluation of mastoid pneumatization pattern using X-ray mastoid and high-resolution computed tomography temporal bone in unilateral squamosal chronic otitis media

Akanksha Dhiman<sup>1</sup>, Ankur Gupta<sup>1\*</sup>, Nishi Sharma<sup>1</sup>, Akhilandeshwari Prasad<sup>2</sup>

<sup>1</sup>Department of Otorhinolaryngology and Head and Neck Surgery, <sup>2</sup>Department of Radiodiagnosis, Atal Bihari Vajpayee Institute of Medical Science and Dr. Ram Manohar Lohia Hospital, New Delhi, India

**Received:** 24 April 2020

**Revised:** 15 June 2020

**Accepted:** 16 June 2020

### \*Correspondence:

Dr. Ankur Gupta,

E-mail: [gupta.ankur39@yahoo.in](mailto:gupta.ankur39@yahoo.in)

**Copyright:** © the author(s), publisher and licensee Medip Academy. This is an open-access article distributed under the terms of the Creative Commons Attribution Non-Commercial License, which permits unrestricted non-commercial use, distribution, and reproduction in any medium, provided the original work is properly cited.

## ABSTRACT

**Background:** Chronic otitis media (COM) affects 0.5-30% of individuals in any community and over 20 million people are estimated to suffer from this condition worldwide. COM often evolves in a continuum. Squamosal disease is more commonly found in poorly pneumatized bones, but whether the sclerosis is relevant to the etiology of the disease or is caused by it, has not been fully resolved. Our study aimed at comparing the mastoid pneumatization patterns obtained using X-ray mastoid and high-resolution computed tomography (HRCT) temporal bone. It was an interventional study.

**Methods:** Sixty patients of unilateral squamosal COM, aged more than 8 years, underwent X-ray mastoid Schuller's view and HRCT temporal bone, using Philips extended brilliance 48 slice CT.

**Results:** Upon analysis, in diseased and healthy ears, the coincidence of X-ray and HRCT findings was 63.33% and 80% respectively.

**Conclusions:** HRCT temporal bone should be done in all cases of squamosal COM to know the extent of the disease, pneumatization patterns and the presence of anatomical variations.

**Keywords:** Squamosal disease, Chronic otitis media, Pneumatized, Sclerotic, Diploic, Schuller's view, HRCT temporal bone

## INTRODUCTION

Otitis media is one of the most prevalent diseases in the world. Abnormalities which cause mild or minimal symptoms, can progress to severe changes, such as retraction pockets and destructive cholesteatoma. This continuum model explains the development of COM in a progressive manner.<sup>1,2</sup> The mastoid air cell system has been recognized as an important contributor to the pathophysiology of middle ear inflammatory diseases.<sup>3</sup> The term pneumatization denotes the process that takes place from perinatal period to puberty, is genetically

determined and greatly influenced by the environment.<sup>4</sup> There have been many reports on the measurement of mastoid pneumatization.<sup>5-8</sup> Our study aimed at studying the differences in pattern of mastoid pneumatization, detected by X-ray mastoid and HRCT temporal bone, in cases of unilateral squamosal COM.

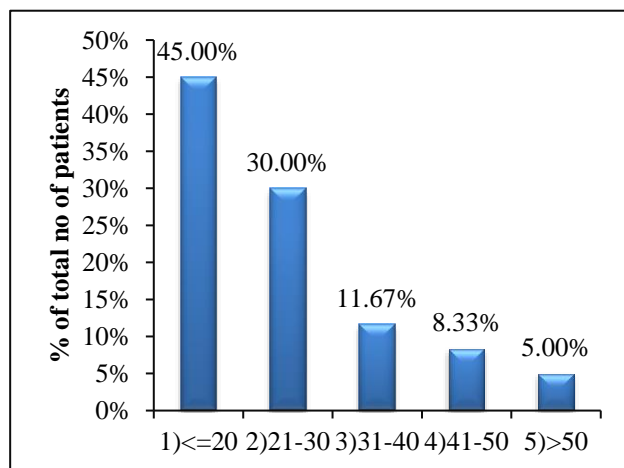
## METHODS

The study was done in the departments of ENT and radiology of Atal Bihari Vajpayee Institute of Medical Sciences and Dr. Ram Manohar Lohia Hospital, New Delhi between November 2016 to March 2018. Sixty

patients of unilateral squamosal COM, having history of more than 8 years were included in the study and underwent complete otorhinolaryngologic examination. All patients were subjected to X-ray mastoid Schuller's view and HRCT temporal bone using Philips extended brilliance 48 slice CT. Scanning commenced from the lower margin of the external auditory meatus and extended upward to the arcuate eminence of the superior semicircular canal. Slight extension to the head was given to avoid the gantry tilt and thereby protect the lens from radiation. Pneumatization pattern, of diseased and contralateral ear obtained, were compared. Ethical clearance was obtained from the Institutional ethical committee (IEC). Categorical variables were presented in number and percentage and continuous variables were presented as mean  $\pm$ SD (standard deviation) and median. Normality of data was tested by Kolmogorov-Smirnov test. Quantitative variables were compared using Anova/Kruskal Wallis test (when the data was not normally distributed) between three groups. Qualitative variables were correlated using Chi-square test. The data was analyzed using statistical package for social sciences (SPSS) version 21.0.

## RESULTS

Majority of the participants were 20 years old (45%) followed by 30% subjects between 21 to 30 years. The youngest patient was 8 years old while the eldest was 70 years. The mean age was 25 years (Figure 1).

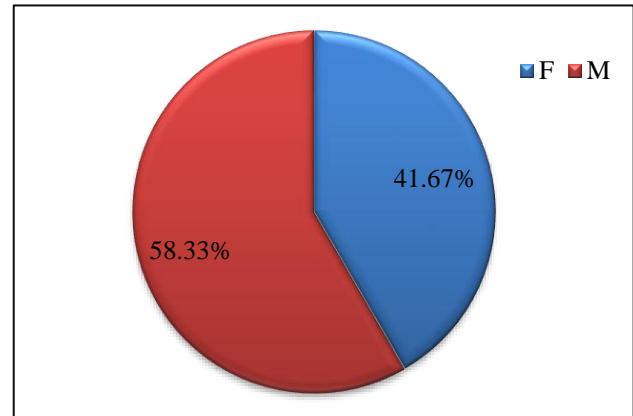


**Figure 1: Age distribution of patients.**

The male to female ratio was 1.4:1 (Figure 2). Chronic otorrhea was the most common symptom followed by hearing loss. Majority of patients (75%) had conductive hearing loss.

Radiological evaluation of diseased ear with X-ray showed sclerosis in 85% followed by diploic and pneumatized mastoid in 11.7% and 3.3% respectively and it was observed that contralateral healthy ears had

pneumatized mastoid in 68.3% followed by diploic and sclerotic in 25% and 6.7% respectively Table (1 and 2).



**Figure 2: Sex distribution of patients.**

**Table 1: Distribution of the patients according to the type of mastoid pneumatization of diseased ear in X-ray.**

Diseased ear	Frequency	Percentage
Diploic	7	11.67
Pneumatized	2	3.33
Sclerotic	51	85.00
Total	60	100.00

**Table 2: Distribution of the patients according to the type of mastoid pneumatization of contralateral ear in X-ray.**

Contralateral healthy ear	Frequency	Percentage
Diploic	15	25.00
Pneumatized	41	68.33
sclerotic	4	6.67
Total	60	100.00

**Table 3: Showing distribution of patients according to type of pneumatization of diseased ear in HRCT.**

Diseased ear	Frequency	Percentage
Diploic	5	8.33
Pneumatized	24	40
Sclerotic	31	51.67
Total	60	100.00

**Table 4: Distribution of patients according to type of pneumatization of contralateral healthy ear in HRCT.**

Contralateral healthy ear	Frequency	Percentage
Diploic	5	8.33
Pneumatized	46	76.67
Sclerotic	9	15
Total	60	100.00

**Table 5: Cross tabulation showing comparison of pneumatization pattern of diseased ears as assessed with X-ray mastoid and HRCT temporal bone.**

Diseased ear (X-ray) vs diseased ear (HRCT)		Diseased ear (HRCT)			Total	P value
		Diploic	Pneumatized	Sclerotic		
Diseased ear (X-ray)	Diploic	5	2	0	7	<0.0001
	Pneumatized	0	2	0	2	
	Sclerotic	0	20	31	51	
Total cases		5	24	31	60	

**Table 6: Cross tabulation showing comparison of pneumatization pattern of healthy ears as assessed with X-ray mastoid and HRCT temporal bone.**

Contralateral ear (X-ray) vs contralateral ear (HRCT)		Contralateral ear (HRCT)			Total	P value
		Diploic	Pneumatized	Sclerotic		
Contralateral ear (X-ray)	Diploic	4	6	5	15	<0.0001
	Pneumatized	1	40	0	41	
	Sclerotic	0	0	4	4	
Total cases		5	46	9	60	

HRCT analysis of diseased ear showed sclerosis in 51.7% followed by diploic and pneumatized pattern in 8.3% and 40%, respectively however amongst healthy ears the pattern showed well cellularity in 76.7% followed by diploic and sclerotic in 8.3% and 15% respectively (Table 3 and 4).

Comparative evaluation of pneumatization pattern of diseased ears and healthy ears with X-ray and HRCT has been shown in (Table 5 and 6) respectively. P value was statistically significant in both the groups.

On analysis, in diseased ears, the coincidence of X-ray and HRCT findings of status of mastoid was 63.33% whereas in healthy ears, the coincidence was 80%.

## DISCUSSION

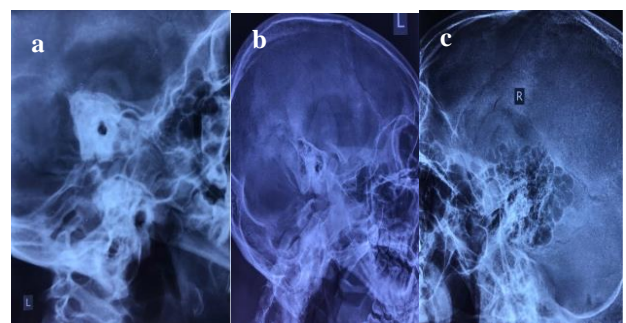
We observed a very wide range age bracket with minimum age of 8 years and maximum age 70 years. Roy et al in their study also reported that large group of patients were in second decade of life.<sup>9</sup> According to the observations of Memon, COM is a disease of young adults and about 50% of patients were between the ages of 11- 30 years.<sup>10</sup> Pre- dominant presence of COM in younger decades of life observed by other investigators matches with findings of our study.

In our study, male population was 58.33% and female population was 41.67%. Aquino et al in his study observed strong male predilection in squamosal COM, thus endorsing our findings.

Majority of the patients presented with otorrhoea followed by hearing impairment. The duration of ear discharge ranged from 8 days to 65 years (mean duration 9 years). Other clinical symptoms with which the patients presented were earache 26.67%, post aural swelling

(18.33%), tinnitus (18.33%), vertigo (11.67%), headache (10%), facial weakness (5%), and fever (1.67%).

We found mostly sclerotic mastoid on X-ray of diseased ear. The probable explanation for this correlation is the inhibitory effect of low grade infection on the osteoblastic activity of the mastoid bone. Roy et al studied 104 diseased ears and found that mastoid was pneumatized in 2, diploic in 20 and sclerotic in 82 ears that correlates with our findings.<sup>3</sup> Arora et al also observed that out of 100 cases of COM, complete sclerosis was found in 40%, air cells less than 3 square centimeters in 49% and air cells more than 3 square centimeters in 11% of cases.<sup>12</sup> Sade and Gomma et al reported the association of low or non-pneumatized mastoid with squamosal COM that is in consonance with our observations.<sup>12-14</sup> However contrary to this Isma et al found that the incidence of cellular mastoid was much higher in squamosal type of COM.<sup>15</sup>

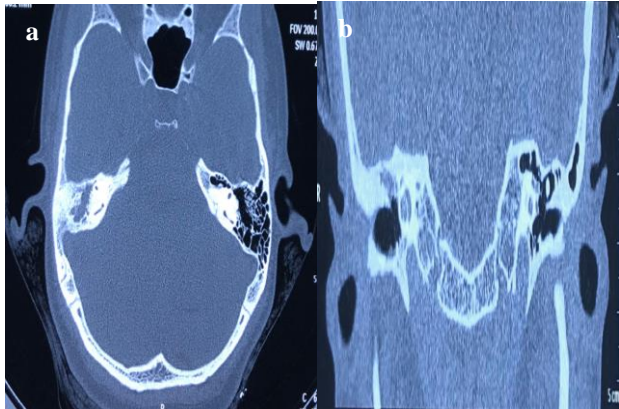


**Figure 3: X-ray mastoid Schuller's view showing sclerotic mastoid (a) diploic, (b) and (c) well cellular mastoid.**

Most of the participants had pneumatized mastoid on normal side. This was consistent with a study done by Mauricio who studied the pneumatization pattern of contralateral ears of severe COM and observed that

65.3% were well pneumatized, 6.7% diploic and 28% sclerotic.<sup>16</sup> Similar observations were made by Roy et al, who studied 70 healthy ears and found that mastoid was pneumatized in 42.86%, diploic in 31.43% and sclerotic in 25.71% ears.<sup>3</sup> In a study by Sethi et al, in the normal ear, 84% had well pneumatized mastoid air cell system and 16% had poor pneumatization on X-ray.<sup>17</sup>

Figure (3 and 4) shows the various pneumatization patterns obtained on X-ray mastoid Schuller's view and HRCT temporal bone, respectively.



**Figure 4: HRCT temporal bone axial cut (a) showing well pneumatized mastoid cavity left side and soft tissue density in mastoid right side and coronal cut (b) showing scutum erosion.**

While analyzing we found that out of 60 diseased ears subjected to HRCT, mastoid was found to be sclerotic in 51.67% followed by pneumatized mastoid in 40%. The findings of our study were in consonance with a study done by Sunitha et al who studied 54 diseased ears and found that HRCT temporal bone revealed pneumatized mastoid in 33.3%, diploic in 3.7%, sclerosed mastoid in 53.7%.<sup>18</sup> HRCT of contralateral healthy ear revealed that mastoid was predominantly pneumatized 76.67% followed by sclerotic mastoid in 15%. Only 5 cases had diploic mastoid. Thus, significantly more pneumatization was observed in contralateral healthy ear. Similar findings were also observed by Sunitha et al who studied HRCT temporal bone of 36 healthy ears and revealed pneumatized mastoid in 61.1%, diploic in 5.6%, and sclerosed mastoid in 33.3% cases.<sup>18</sup>

We found that, amongst diseased ears, out of 51 cases detected as sclerotic by X-ray mastoid, HRCT revealed 20 as pneumatized. The pneumatized mastoid was detected in 2 cases by X-ray that correlated well with HRCT. Whereas, out of 7 cases detected as diploic by X-ray, HRCT reported 2 of them as pneumatized.

Hence in our study similarity and difference between X-ray and HRCT findings in diseased ear was reported to be 63.33% and 36.67% respectively. The difference between X-ray and HRCT findings can be explained by the fact that HRCT provides a better resolution and detailed

evaluation of all the air cells. HRCT has the advantage that it shows the complete pneumatization with excellent resolution as observed by Virapongse et al.<sup>19</sup>

Amongst healthy ears, 41 cases reported as pneumatized in X-ray, HRCT labelled 40 as pneumatized and only 1 case was labelled as diploic. Detection of sclerosis of mastoid in X-ray and HRCT correlated well in all the 4 cases. Rest 15 cases detected as diploic on X-ray, HRCT reported 4 of them as diploic, 6 as pneumatized and rest 5 as sclerotic. Hence the similarity and difference between X-ray and HRCT findings in contralateral healthy ear was reported to be 80% and 20%, respectively.

## CONCLUSION

We conclude that the role of plain film radiography is limited to know the type of mastoid pneumatization as well as to detect the presence of any abnormality in dural plate, sigmoid plate and sino-dural angle. The extent of disease involving the mastoid air cells and mastoid antrum is well appreciated with HRCT. Improvements in radiological technique has definitely improved the study of temporal bone in patients with COM, which includes evaluation of the extent and sites of involvement and inter-relationships of the tympanomastoid compartment with adjacent neurovascular structures.

*Funding: No funding sources*

*Conflict of interest: None declared*

*Ethical approval: The study was approved by the Institutional Ethics Committee*

## REFERENCES

1. Yoon TH, Paparella MM, Schachern PA, Lindgren BR. Morphometric studies of the continuum of otitis media. *Ann Otol Rhinol Laryngol Suppl.* 1990;148:23-7.
2. Paparella MM, Kim CS, Goycoolea MV, Giebink S. Pathogenesis of otitis media. *Ann Otol Rhinol Laryngol.* 1977; 86(4-1):481-92.
3. Roy A, Deshmukh PT, Patil C. Pneumatization pattern in squamosal type of chronic otitis media. *Indian J Otolaryngol Head Neck Surg.* 2015;67(4):375-80.
4. Tos M. *Manual of middle ear surgery.* Thieme. 1995;2:50-61.
5. Schnabl J, Glueckert R. Sheep as a large animal model for middle and inner ear implantable hearing devices: a feasibility study in cadavers. *Otol Neurotol.* 2012;33(3):481-9.
6. Michio I, Akihiko I. Computerised assessment of developmental changes in the mastoid air cell system. *Int Congr Ser.* 2003;1254:487-91.
7. Ahmet K, Osman KA. Mastoid air cell system. *Otoscope.* 2004;4:144-54.
8. Allam AF. Pneumatization of the temporal bone. *Ann Otol Rhinol Laryngol.* 1969;78:48-64.



9. Roy A, Deshmukh PT, Patil C. Pneumatization pattern in squamosal type of chronic otitis media. *Indian J Otolaryngol Head Neck Surg.* 2015;67(4):375-80.
10. Memon MA, Matiullah S, Ahmed Z, Marfani MS. Frequency of unsafe chronic suppurative otitis media in patients with discharging ear. *JLUMHS.* 2008;7(2):102-5.
11. Arora MM, Sharma VL, Mehra YN. Mastoid pneumatization in chronic suppurative otitis media and its clinical significance. *J Laryngol Otol.* 1978;92(5):395-8.
12. Datta G, Baisakhiya N, Mendiratta V. Unsafe CSOM still a challenge in rural areas. *Otolaryngol Online J.* 2014;4(2):1-16.
13. Ueda T, Eguchi S. Distribution of pneumatization of the temporal bone in chronic otitis media seen during the age of antibiotic therapy. *J Otol Rhinol Laryngol.* 1961;64:1539-42.
14. Gomma MA, Karim ARAA, Ghany HSA, Elhiny AA, Saadek AA. Evaluation of temporal bone cholesteatoma and the correlation between high resolution computed tomography and surgical finding. *Clin Med Insights.* 2013;6:21-8.
15. Iqbal IZ, Watson C. A study of cholesteatoma and mastoid pneumatization. *Otolaryngol Head Neck Surg.* 2012;147(2):79.
16. Silva DMNL, Muller JS, Selaimen FA, Oliveira DS, Rosito SLP, Costa SSD. Tomographic evaluation of the contralateral ear in patients with severe chronic otitis media. *Braz J Otorhinolaryngol.* 2013;79(4):475-9.
17. Sethi A, Singh I, Agarwal AK, Sareen D. Pneumatization of mastoid air cells: role of acquired factors. *Int J Morphol.* 2006;24(1):35-8.
18. Sunitha M, Asokan L, Sambandan AP. A comparative study of plain X-ray mastoids with HRCT temporal bone in patients with chronic suppurative otitis media. *J Evolution Med Dent Sci.* 2015;4(30):5190-7.
19. Virapongse C, Sarwar M, Bhimani S, Sasaki C, Shapiro R. Computed tomography of temporal bone pneumatization. *AJR Am J Roentgenol.* 1985;145(3):473-81.

**Cite this article as:** Dhiman A, Gupta A, Sharma N, Prasad A. Comparative evaluation of mastoid pneumatization pattern using X-ray mastoid and high-resolution computed tomography temporal bone in unilateral squamosal chronic otitis media. *Int J Otorhinolaryngol Head Neck Surg* 2020;6:1469-73.