

## Cases Report

# The hybrid concept in lip reconstruction

**Badr M. I. Abdulrauf\***

Section of Plastic and Reconstructive Surgery, Department of Surgery, King Faisal Specialist Hospital and Research Center Jeddah, Saudi Arabia

**Received:** 13 April 2020

**Accepted:** 29 April 2020

**\*Correspondence:**

Dr. Badr M. I. Abdulrauf,

E-mail: badrplastics@gmail.com

**Copyright:** © the author(s), publisher and licensee Medip Academy. This is an open-access article distributed under the terms of the Creative Commons Attribution Non-Commercial License, which permits unrestricted non-commercial use, distribution, and reproduction in any medium, provided the original work is properly cited.

### ABSTRACT

Local tissues are best suited for lip reconstruction. The defect following cancer resection is often significant where standard methods are often suboptimal. Here we are presenting 3 such cases. Case 1, a 65 years old male post squamous cell carcinoma (SCC) resection with 50% defect of lower lip and a commissure, reconstructed with Estlander flap and a unilateral Karapandzik flap on opposite side. Case 2, a 35 years old male had a similar kind of defect, reconstructed with Estlander flap and step-plasty on opposite side. Case 3, a 70 years old female with 80% central lower lip defect post SCC resection, was reconstructed with bilateral Karapandzik flaps and an Abbe flap. Considering the significant size defect, all cases healed quite satisfactorily. They maintained their oral competence with negligent microstomia. The hybrid principle of combining various reconstructive techniques is highly recommended for major lip defects.

**Keywords:** Lip defect, Lip cancer, Flaps, Lip reconstruction, Major, Subtotal

### INTRODUCTION

Theoretically speaking, numerous flaps have been described for lip reconstruction. For defects up to 50 % of the lip, methods such as Karapandzik (K) rotation flaps or Johanson's step-plasty have been quite reliable techniques.<sup>1</sup>

Defects more than 50% are challenging. Methods such as may modification of Dieffenbach or Stranc-Robertson's steeple flaps result in functionally compromised and insensate lips.<sup>2</sup>

In this article we would like to present the hybrid concept, which depends on using more than one type of method of reconstruction, in 3 cases with significant lower lip defects following cancer resection.

### CASE REPORT

All 3 cases shown in this article were managed by multidisciplinary team, had lip tumor resection guided by frozen sections and neck dissection done initially by a colleague. They all received radiotherapy once their wounds and flaps healed optimally.

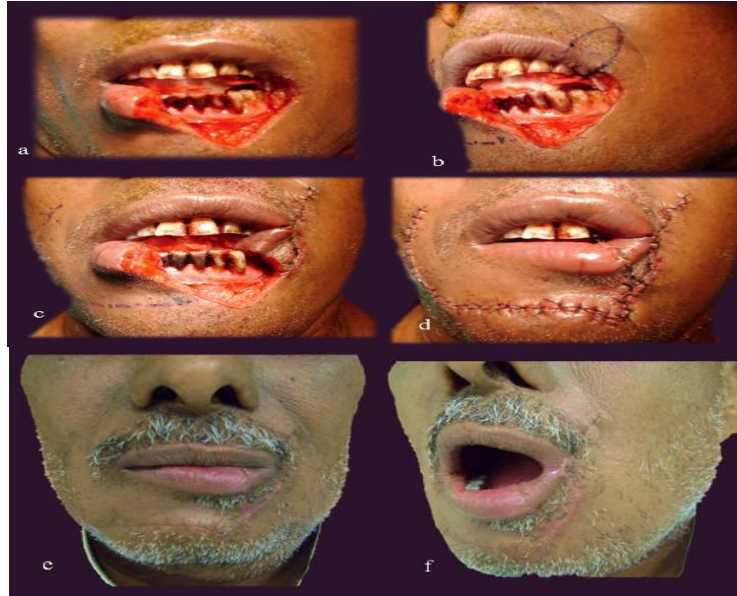#### Case 1

A 65 years old male diagnosed with squamous cell carcinoma (SCC) of lower lip with AJCC stage of T2 N1 M0. Patient had a 2.5 cm full thickness resection (about 50% of lip tissue) and a commissure, this case was ideal for a combination of Estlaner (E) flap for the commissure reconstruction and rotation of K flap from the contralateral side for the semi central defect. He healed quite nicely, maintained good size oral aperture and function (Figure 1).

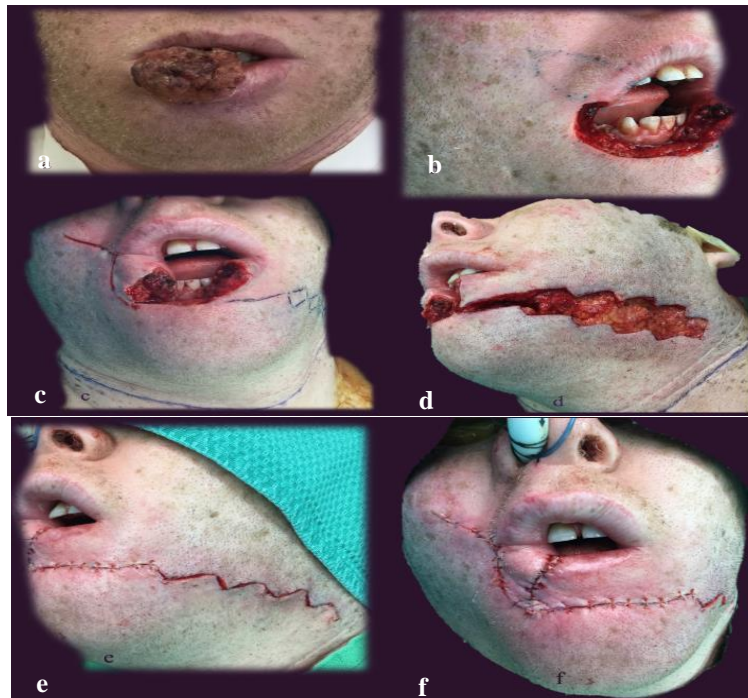**Case 2**

A 35 years old male diagnosed with SCC of lower lip, staged as T2 N1a M0. This young adult had 3.0 cm full thickness resection of his lower lip. Preop. inter commissure distance was 4.5 cm, which means he lost close to 70% of his lower lip tissue. Commissure was

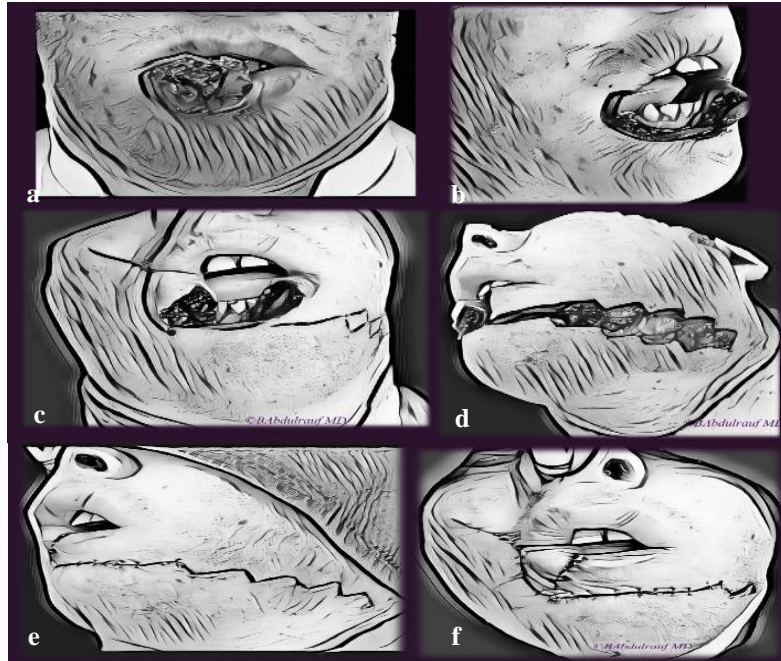
reconstructed with an E flap; the remaining lip was considered for an extended Johanson's step-plasty (Figure 2 and 3). His results following surgery and radiotherapy are shown one year later, there is minor element of microstomia but oral competence is very good (Figure 4).



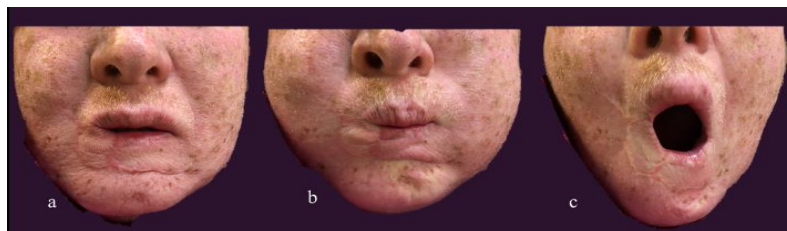**Figure 1: Case 1, (a) with 50% defect of lower lip and commissure, (b) plan marked, K flap on right side and E flap to left commissure, (c) E flap has been raised and transferred, (d) K flap been rotated, sutured to the E flap, completion of reconstruction, (e) 2 months postop, at rest and (f) optimum mouth opening.**



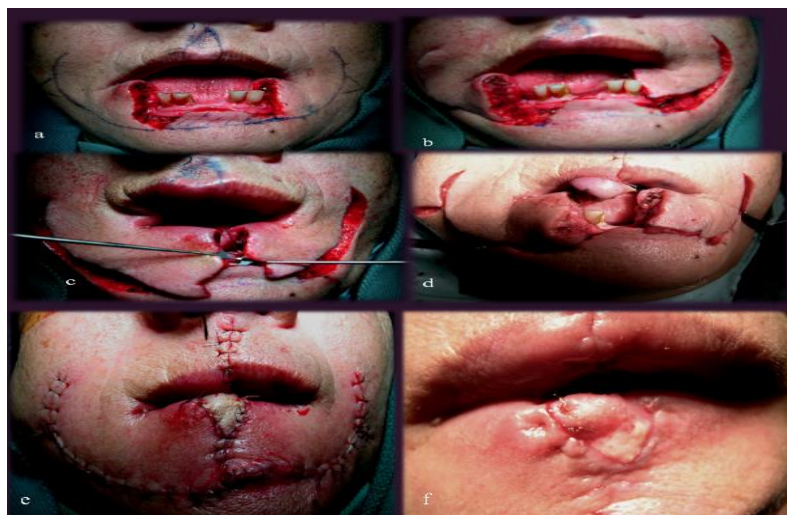**Figure 2: Case 2, (a) young adult with SCC, inter commissure distance of 4.5 cm, (b) 3.0 cm segment of lower lip and a commissure has been resected, E flap of good width been marked, (c) E flap has been raised and transferred, achieved a full commissure and reduced the gap considerably, an step-plasty has been marked on the contralateral side, (d) step-plasty planned from contralateral side, (e) closure donor site of the step plasty and (f) completion of reconstruction inter commissure distance 4.0 cm.**



**Figure 3 (a-f): Artist's depiction of the surgical maneuvers shown in case 2.**

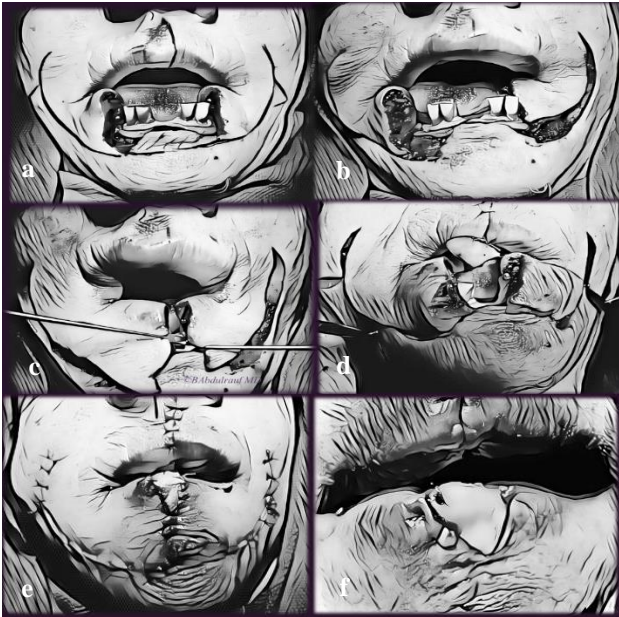


**Figure 4: (a) Results of case 2, a year post-surgery and radiotherapy, at rest, (b) good oral competence, and (c) minimal microstomia, inter commissure distance of 4.0 cm.**

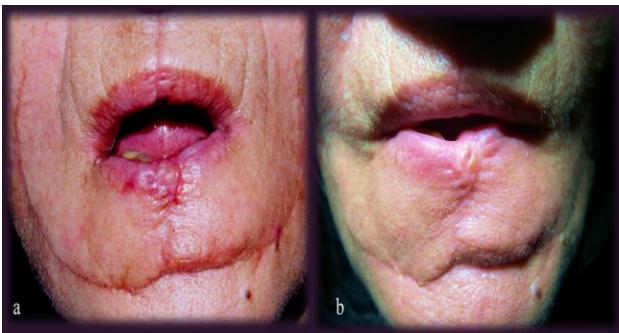

**Figure 5: Case 3, (a) central lower lip defect of 80%, planned for bilateral K flaps, and Abbe flap from upper lip philtrum, (b) K flaps being dissected and raised, (c) attempting to mobilize K flaps, the requirement for a lip sharing with an Abbe flap is demonstrated, (d) Abbe flap has been dissected and raised in a shield shape, hanging from philtrum of upper lip with a small hidden pedicle. Its donor site been closed, (e) Abbe flap is been flipped, secured to K flaps, the lips are held together centrally with a bridge of the labial vessels supplying the Abbe flap. Burrow's triangles were also excised on both cheeks to facilitate rotation, and (f) division of Abbe flap at 3 weeks postoperatively and revision to the mucosal wounds.**





**Figure 6 (a-f): Artist's depiction of the surgical maneuvers shown in case 3.**



**Figure 7: Case 3, (a) two months post-operative and (b) a year post-surgery and radiotherapy.**

### Case 3

A 70 years old woman diagnosed with SCC of lower lip staged as T3 N2c M0. Following tumor resection, she ended up with close to 80% full thickness defect.

Reconstructive plan included bilateral K flaps, and an Abbe flap from upper lip. All wounds healed satisfactorily. The Abbe flap was divided in approximately 3 weeks (Figure 5 and 6). Patient had minimal microstomia (Figure 7).

### DISCUSSION

It is unfortunate that many patients still present late with significant size tumors in their lips. The decision for surgical treatment of the tumor at our institute is made by the primary head and neck surgeon.

Many microsurgical reconstructive procedures for the lip have been described and evolved, but they mostly

produce a physical replacement with poor sensation, poor mobility and aesthetically poor mismatch to local tissues.<sup>3,4</sup> It is fortunate however the older patients with poor skin elasticity are the ones who usually undergo lip resection. It needs to be clarified that percentage of lip defects following resection is estimated as per the inter commissure distance for a particular patient, since it varies from one individual to another.<sup>5</sup>

K flaps depend on recruiting cheek tissues, whereas step plasty recruits upper cervical skin in step wise manner, a technique that does require a learning curve more so than other local flaps. Both are extremely useful maneuvers and known to preserve muscle function and lip sensation.<sup>2</sup> E flap is an exceptionally useful tool for the commissure area, as demonstrated in two of our cases in this article.

In case 2, the patient was unfortunately quite young with delay in referral as well. A bigger than average size E flap was used to provide a commissure and also to assist in reducing the remaining gap Figure 3 (b and c). Patient did not have lax cheek skin; therefore, K flap would not be a correct choice. An extended step plasty was considered in order to optimally reconstruct the lip.

Case 3 was almost a subtotal defect with intact commissures. Bilateral K flaps or step plasties are both viable options, the latter was used since this case was done early in our practice. If no further intervention done in such a case, significant microstomia is definite. The upper lip philtrum was the ideal donor site for an Abbe flap, not only to fill the gap but also to provide some harmony between upper and lower lips. It is a common observation following standard reconstructions with bilateral K flaps or step plasties, the opposing lip seems often crowded.

A word of caution that K flap dissection and mobilization on the side of which Abbe flap is based on has to be more conservative. We believe in cases such as presented above, it would be impossible to reconstruct the lip without improving added flaps, hence the title, 'Hybrid' concept in lip reconstruction.

*Funding: No funding sources*

*Conflict of interest: None declared*

*Ethical approval: Not required*

### REFERENCES

1. Neligan PC. Strategies in lip reconstruction. Clin Plast Surg. 2009;36(3):477-85.
2. Stranc MF. Reconstruction of the lips, chapter in Mastery of plastic surgery, Cohen M, Lippincott Williams and Wilkins; 1994.
3. Vansison C, Beckmann N, Smith A. Recent advances in lip reconstruction. Curr Opin Otolaryngology Head Neck Surg. 2019;27(3):219-26.

4. Sasaki K, Sasaki M, Oshima J, Aihara Y, Nishijima A. flap reconstruction for full thickness oral defects involving the oral commissure combined with oral modiolus reconstruction using a facial sling. *Microsurgery*; 2019.
5. Fogel ML, Stranc MF. Lip function: a study of normal lip parameters. *BJPS*. 1984;37:542-9.

**Cite this article as:** Abdulrauf BMI. The hybrid concept in lip reconstruction. *Int J Otorhinolaryngol Head Neck Surg* 2020;6:1183-7.