

Original Research Article

Clinicopathological profile of adenoid cystic carcinoma of minor salivary gland tumour: our experience at a tertiary care centre

Prakash Mylanahalli Doddrangaiah, Bharath Kanna Karunakaran,
Roopa S. Mallali, Afshan Fathima*

Department of ENT, Bangalore Medical College and Research Institute, Bangalore, Karnataka, India

Received: 04 April 2020

Revised: 17 June 2020

Accepted: 22 June 2020

*Correspondence:

Dr. Afshan Fathima,

E-mail: entbmc2020@gmail.com

Copyright: © the author(s), publisher and licensee Medip Academy. This is an open-access article distributed under the terms of the Creative Commons Attribution Non-Commercial License, which permits unrestricted non-commercial use, distribution, and reproduction in any medium, provided the original work is properly cited.

ABSTRACT

Background: Adenoid cystic carcinoma (ACC) is a rare malignant tumour originating from minor salivary glands. It is known for perineural spread, local recurrences and distant metastasis. The minor salivary gland tumour represents 3% of all head and neck neoplasms, whereas ACC constitutes about 0.5% of all malignant salivary gland neoplasms. This study was done to evaluate the clinical presentation and histopathological findings of minor salivary gland tumour.

Methods: This study was done in the department of ENT, Bangalore Medical College and Research Institute from May 2017 to July 2019. Of the 25 patients with minor salivary gland tumour, 10 patients with ACC were considered for the present study. A detailed clinical and histopathological evaluation was done. Results were documented and tabulated in excel sheet.

Results: We analysed data of 25 (16 female, 9 male) patients in the age group of 30-60 years, of which 10 patients had adenoid cystic carcinoma of minor salivary gland tumour. The most frequent site of tumour occurrence was noted in the hard palate (6 patients), followed by retromolar trigone (2 patients), floor of mouth (1 patient) and tongue (1 patient). The histopathological pattern noted most commonly in our study: cribriform pattern (6 cases), tubular (1 case) and solid (3 cases).

Conclusions: ACC of minor salivary glands is rare. The otorhinolaryngologist should bear this clinical entity in mind when encountered with a painless swelling over the hard palate. This would lead to an early diagnosis and prompt management in such patients.

Keywords: Adenoid cystic carcinoma, Minor salivary glands, Hard palate

INTRODUCTION

There are 800-1000 minor salivary glands located throughout the sub mucosa of the oral cavity situated in the buccal, labial, lingual mucosa, soft palate, lateral part of the hard palate and floor of the mouth. They are 1-2 mm in diameter and unlike the other glands they are not encapsulated by connective tissue but only surrounded by it. The gland is usually a number of acini connected in a tiny lobule. Their secretion is mainly mucus in nature and

innervated by facial nerve. The incidence of minor salivary gland tumours 2-4% of all the head and neck malignancies.¹

Adenoid cystic carcinoma (ACC) is a rare malignant tumour originating from minor salivary glands. These are known characteristically for perineural spread, local recurrences and distant metastasis.² The salivary gland tumours represent about 3% of all head and neck

neoplasms, whereas the ACC constitute about 0.5% of all malignant salivary gland neoplasms.³

ACC usually appears between the 3rd and 9th decade of life, with a peak incidence between 40 and 70 years of age. It does not show any gender predilection.⁴ ACC of minor salivary glands usually occurs in the soft/hard palate followed by lower lip, retromolar trigone, sublingual gland, buccal mucosa and floor of mouth.⁵⁻⁷

Till date, surgery and radiotherapy remains the modality of treatment for ACC. In spite of this the tumour is known for loco regional recurrences.³

The present study was carried out to know the percentages and clinical presentation and histopathology of minor salivary gland tumours. A detailed study with respect to percentage, clinical presentation and features of ACC was done.

METHODS

The present study was carried out in the department of ENT, Bangalore Medical College and Research Institute from May 2017 to July 2019. Sample size is 25 patients.

Study design: retrospective cohort study.

Inclusion criteria

Inclusion criteria were patients who were willing to give consent, patients with minor salivary gland tumours and histopathological confirmed cases of adenoid cystic carcinoma of minor salivary glands.

Exclusion criteria

Other histological types of minor salivary gland tumours were excluded.

Methods of data collection

The data was collected from the patients who presented to the outpatient department of ENT, Bangalore Medical College and Research Institute. Details including age, gender, anatomical site, symptomatology, gross features and histopathological diagnosis of each patient was recorded accordingly.

For histopathological study, slides containing 5 µm thick sections stained with haematoxylin and eosin were used. All cases were evaluated by light microscopy and classified according to the criteria proposed by the World Health Organization.⁸

Statistical analysis

The data was collected and tabulated in excel sheets.

RESULTS

We analysed data of 25 patients of which 10 patients showed features corresponding to adenoid cystic carcinoma of minor salivary gland tumours. There were 16 female and 9 male patients. The patients age ranged from 30-60 years with mean age of 50.8 years (Table 1) (Figure 1).

Table 1: Age distribution of study subjects.

Age range in years	Number of cases	Percentage
30-40	2	20
40-50	1	10
50-60	7	70

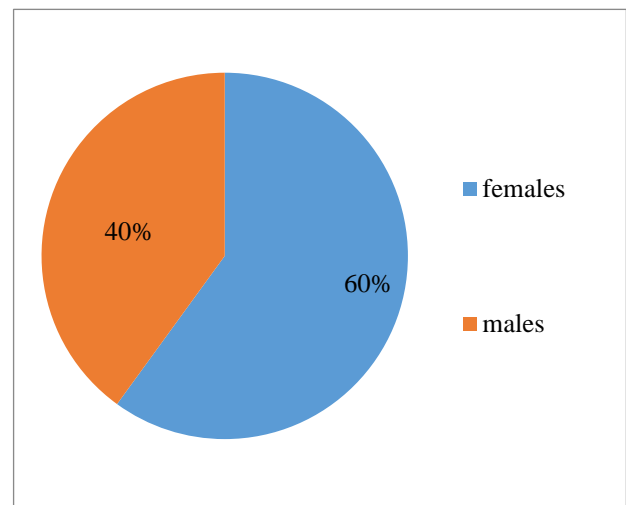


Figure 1: Sex distribution of study subjects.

The most frequent site of tumour was noted in the hard palate region (6 patients), followed by retromolar trigone (2 patients), floor of mouth (1 patient) and tongue (1 patient) (Table 2).

Table 2: Tumour distribution according to anatomical sites.

Anatomical site	Number of cases	Percentage
Hard palate	6	60
Retro molar trigone	2	20
Floor of mouth	1	10
Tongue	1	10

The most common presentation in our study was found to be a growth (8 cases), ulceration (1 case) and pain (1 case) (Figure 2).

The histopathological pattern noted most commonly in our study: cribriform pattern (6 cases) tubular (1 case) and solid (3 cases) (Table 3 and Figure 3).

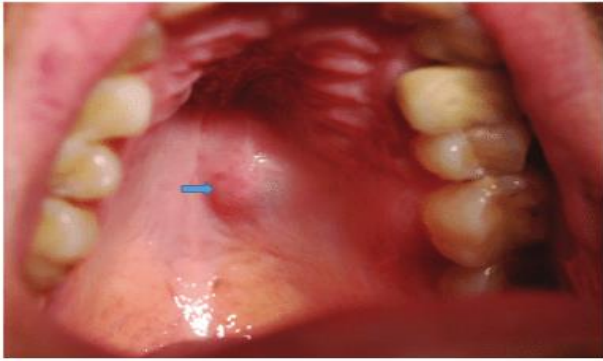


Figure 2: Clinical presentation of minor salivary gland tumour over hard palate.

Table 3: Histological pattern distribution of ACC.

Histological pattern	Number of cases	Percentage (%)
Cribriform	6	60
Tubular	1	10
Solid	3	30

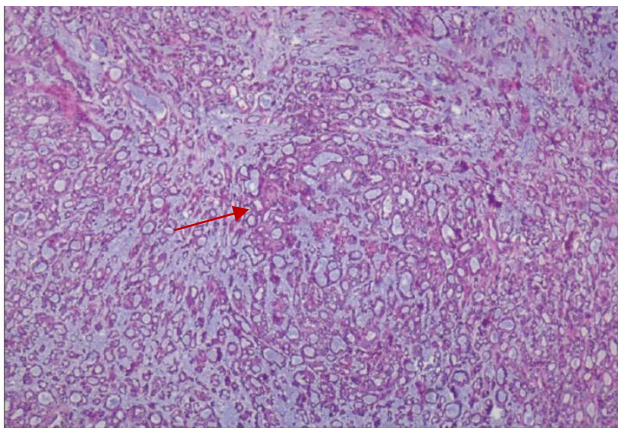


Figure 3: Histopathological slide representing adenoid cystic carcinoma and cribriform pattern with mucinous matrix; red arrow shows cribriform pattern with mucinous matrix.

DISCUSSION

Malignant neoplasms of minor salivary glands are rare and account for an estimated 2-4% of all head and neck neoplasms.¹ Among malignant neoplasms of minor salivary glands, ACC predominates. This tumour is characterized by an indolent clinical course and a slow progressive growth.³ A study conducted by Kruse et al on malignant neoplasms of minor salivary glands observed that adenoid cystic carcinoma was the most prevalent lesion.⁹

Studies conducted by Kokemuller et al and Avery et al showed that all age groups are affected but predominantly affected are the fourth to sixth decade of life.^{10,11} In our

study, mean age of the patients was 50.8 years. This was in accordance to the above-mentioned studies.

In our study, female patients 60% were affected more than male patients with a male: female ratio of 1:1.3. A study conducted by Martinez et al showed ACC was found to be more common among women 56.5% and the average age at diagnosis was 55.26 years.³

The diagnosis of ACC was done by the anatomical site of lesion and characteristic histopathological findings. A study by Darling et al showed that the hard palate was the most common site affected by ACC and comprised of 8.3% of all palatal tumours and 17.7% of palatal minor salivary gland tumours.¹² Similarly in our study the most common site of tumour involvement was hard palate in 60% of cases followed by the retromolar trigone 20%.

In our study 80% of cases presented with a painless swelling. A similar study by Abdullah et al showed that the painless mass in the palate was predominant presentation in 73% of patients.¹³ These findings were in accordance to our present study. ACC usually shows no specific signs and symptoms. It can present as an asymptomatic mass in the oral cavity with mild pain and discomfort with prolonged duration.

In the histopathological study of ACC, there are three recognised patterns - cribriform, tubular and solid. Bianchi et al showed in their study that the cribriform pattern was the most predominant 45%.¹⁴ In our study the predominant histological pattern was found to be cribriform 60% followed by solid 30% and tubular 10%.

CONCLUSION

Adenoid cystic carcinoma of minor salivary glands is rare. It has got an indolent clinical course. The commonest presenting symptom being a painless swelling which is predominantly noted in the hard palate. It is known for local and distant metastasis.

The otorhinolaryngologist should bear in mind this entity when encountered with a painless swelling over the hard palate, retromolar trigone etc for an early diagnosis and prompt management.

Funding: No funding sources
Conflict of interest: None declared
Ethical approval: The study was approved by the Institutional Ethics Committee

REFERENCES

- Speight PM, Barrett AW. Salivary gland tumors. Oral Diseases. 2002;8:229-40.
- Rodriguez MN, Berrocal LI, Alonso RL, Irimia AO, Gonzalez MJ. Epidemiology and treatment of adenoid cystic carcinoma of the minor salivary

- glands: a meta-analytic study. *Medicina Oral Pathología Oraly Cirugia Bucal*. 2011;884-9.
3. Leegaard T, Lindeman H. Salivary-gland tumors. Clinical picture and treatment. *Acta Otolaryngol Suppl*. 1969;263:155-9.
 4. Bradley PJ. Adenoid cystic carcinoma of the head and neck: a review. *Curr Opin Otolaryngol Head Neck Surg*. 2004;12:127-32.
 5. Bianchi B, Copelli C, Cocchi R. Adenoid cystic carcinoma of intraoral minor salivary glands. *Oral Oncology*. 2008;44:1026-31.
 6. Barnes L, Eveson JW, Reichart P, Sidransky D, editors, editors. *Pathology and genetics of head and neck tumors*. Lyon: IARC Press; 2005:209-228.
 7. MacIntosh R. Minor salivary gland tumors: Types, incidence and management. *Oral Maxillofac Surg Clin North Amer*. 1995;7:573-89.
 8. Triantafillidou K, Dimitrakopoulos J, Iordanidis F, Koufogiannis D. Management of Adenoid Cystic Carcinoma of Minor Salivary Glands. *J Oral Maxillofacial Surg*. 2006;64(7):1114-20.
 9. Kruse AL, Gratz KW, Obwegeser JA, Lubbers HT. Malignant minor salivary gland tumors: a retrospective study of 27 cases. *Oral Maxillofac Surg*. 2010;14(4):203-9.
 10. Kokemueller H, Eckardt A, Brachvogel P. Adenoid cystic carcinoma of the head and neck: a 20 years' experience. *Int J Oral Maxillofac Surg*. 2004;33:25-31.
 11. Avery CM, Moody AB, Kinna MFE. Combined treatment of adenoid cystic carcinoma of the salivary glands. *Int J Oral Maxillofac Surg*. 2000;29:277-79.
 12. Darling MR, Schneider JW, Phillips VM. Polymorphous low-grade adenocarcinoma and adenoid cystic carcinoma: a review and comparison of immunohistochemical markers. *Oral Oncology*. 2002;38(7):641-5.
 13. Dalgic A, Karakoc O, Aydin U, Hidir Y, Gamsizkan M, Karahatay S, et al. Minor Salivary Gland Neoplasms. *J Craniofacial Surg*. 2014;25(3):289-91.
 14. Bianchi B, Copelli C, Cocchi R, Ferrari S, Pederneschi N, Sesenna E. Adenoid cystic carcinoma of intraoral minor salivary glands. *Oral Oncol*. 2008;44:1026-31.

Cite this article as: Doddrangaiah PM, Karunakaran BK, Mallali RS, Fathima A. Clinicopathological profile of adenoid cystic carcinoma of minor salivary gland tumour: our experience at a tertiary care centre. *Int J Otorhinolaryngol Head Neck Surg* 2020;6:1460-3.