

Original Research Article

Oral submucous fibrosis: a study of qualitative and analytical treatment using intralesional injections: placental extract versus combination of steroid with hyaluronidase

Meena Vishwanath Kale*, Ninad Subhash Gaikwad

Department of ENT, TNMC and BYLCH Nair Hospital, Mumbai Central, Mumbai, Maharashtra, India

Received: 24 March 2020

Revised: 15 May 2020

Accepted: 16 May 2020

*Correspondence:

Dr. Meena Vishwanath Kale,

E-mail: meenakale33@gmail.com

Copyright: © the author(s), publisher and licensee Medip Academy. This is an open-access article distributed under the terms of the Creative Commons Attribution Non-Commercial License, which permits unrestricted non-commercial use, distribution, and reproduction in any medium, provided the original work is properly cited.

ABSTRACT

Background: One of the premalignant conditions in oropharynx is oral submucous fibrosis (OSMF). It is a chronic debilitating condition of unknown etiology leading to fibrosis of mucosa affecting the oropharynx, esophagus and thus causes decreased mouth opening and dysphagia respectively. The disease is of multifactorial etiology with having addictions and nutritional, micro elements and antioxidants deficiencies. In India males are more affected than females, due to their stress related excessive, irresponsible chewing habits. The available management is for symptomatic relief and at present there is no definitive treatment is available.

Methods: We have studied 60 cases diagnosed with OSMF with mild to moderate restricted mouth opening. Most of patients were between 17 to 55 years of age selected by randomized clinical trial. Its management was divided into 2 groups where group A was treated with a combined intralesional regimen of injection triamcinolone 40mg and hyaluronidase 1500 IU, while group B was treated with injection of 2ml placental extract. Each group was given a single dose intralesional injection per week for six weeks.

Results: It was a comparative study of improvement in effectiveness on mouth opening and reduction in burning sensation of oral cavity seen in group A regimen than group B. Those having persistent trismus, needed surgery.

Conclusions: No effective treatment available but along with intralesional injection can give symptomatic relief. In addition, cessation of habits, antioxidants oral hygiene helps in improvement of OSMF.

Keywords: Hyaluronidase, Oral submucous fibrosis, Placental extract, Triamcinolone, Trismus

INTRODUCTION

Diseases in a human body are mainly due to changes in life style and habits. Oral submucous fibrosis (OSMF) is a chronic debilitating disease caused due to the habit of chewing arecanut, chillies, misri and tobacco in many forms resulting in marked rigidity and progressive decrease in mouth opening.¹

WHO in 1978 defined OSMF as a slowly progressive multifactorial disease in which multiple fibrotic bands are

formed in oral mucosa ultimately leading to restriction of mouth opening and tongue movements, it mainly affects palate, cheek and facial pillars. The etiological role of chewing arecanut and its association with malignancy in OSMF has been noticed.^{2,3} The factors are as follows.

Prolonged local irritation

Tobacco and its chemical constituents are irritants while nicotine had a synergistic effect with arecoline and both of them inhibits collagen phagocytosis and decreases the

overall breakdown of collagen.^{4,5} This results in increased fibrosis due to increased collagen synthesis.¹ OSMF remains active even after cessation of the chewing habit, suggesting that components of the arecanut initiate OSMF and then affect gene expression in the fibroblasts, which then produce greater amounts of normal collagen.⁶ Arecanuts have shown to have a high copper which stimulates fibrogenesis through up-regulation of copper dependent lysyl oxidase activity.^{7,8}

Genetic and immunologic process

This may be due to exogenous antigenic stimulation which increases frequency of HLA factors production and thus reduces antifibrotic activity leading to alteration of tissue architecture and may be the cause of OSMF.^{6,9}

Nutritional deficiencies

Deficiencies of iron, vitamin B complex, micro elements and antioxidants can precipitate fibrotic activity and affect the integrity of the oral mucosa.^{10,11}

Clinical features

The clinical stage depends on features of the disease as per the progression of lesion is proposed is by More et al in 2012.^{12,13}

Stage 1

Stomatitis and vesiculation, erythematous mucosa, ulcers, melanotic mucosal pigmentation and mucosal petechiae. Burning sensation in mouth for spicy food.

Stage 2

Ruptured vesicles and ulcers healed by fibrosis. Circular and vertical fibrous bands appear around lips, oropharyngeal mucosa (Figure 1). Buccal mucosa (98%) is most common site.¹⁴

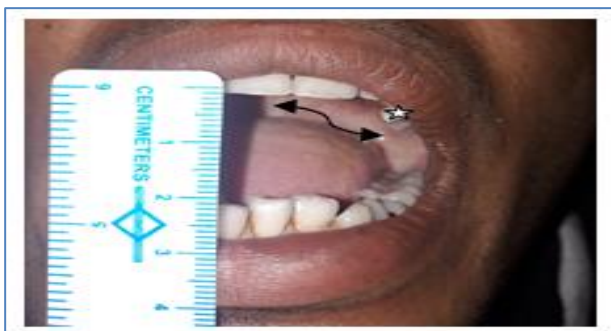


Figure 1: Fibrotic bands on bilateral soft palate, RMT, Anterior pillar with adequate mouth opening (↔) and shows tobacco stained teeth measurement of inter incisor distance with measuring scale (☆).

Specific findings include trimus, stiff and small tongue, fibrotic and depigmented gingiva, rubbery soft palate, decreased salivation, atrophic tonsil, shrunken bud like uvula. The fibrosis involves pyriform fossa but larynx is free hence respiration is not affected.

Stage 3

Sequelae and complication of speech, dysphagia and hearing defects due to fibrosis of tongue, esophagus and eustachian tube openings respectively.

Stage 4

Any of the above stage along with other potentially malignant lesions seen in India like leukoplakia, erythroplakia, squamous cell carcinoma (SCC) 7.6% incidence is found with OSMF.¹³ As per one study the traumatized mucosa in addicted person may concentrate more carcinogen and more susceptible to SCC.¹⁵

Treatment

The etiopathology and curative solution is not clear even now to the present medical science.¹⁶ Management of OSMF depends on the degree and stage of disease. In very early cases cessation of chewing habit was sufficient.¹⁷ In mild to moderate cases medical management may be sufficient.

Medical treatment

Along with multivitamins, antioxidant tablets and intralesional injections like combination of steroids with hyaluronidase or placental extracts and IFN- γ etc.

Steroids

Anti-inflammatory and immunosuppressant properties helps to prevent mucosal damage in early and moderate cases. Commonly used ones are dexamethasone, triamcinolone acetonide and betamethasone. Triamcinolone is more preferred as intralesional therapy.¹⁸

Contraindication

Hypersensitivity, active bacterial and fungal infection.

Side effects

Risks of infections, adrenal insufficiency, hyperglycemia, osteonecrosis, myopathy, peptic ulcer, hypokalemia, psychosis etc.

Adult doses

Dexamethasone 4 mg i.v., triamcinolone 40-80mg intralesional.

Hyaluronidase

It stimulates hydrolysis of hyaluronic acid, one of the chief ingredients of tissue cement. Distensibility of the mucosa reported with injection hyaluronidase.

Contraindication

Hypersensitivity, safety in pregnancy not established. Avoid injecting to inflamed and cancerous areas.

Steroids along with hyaluronidase gives synergistic effect and also shows better long-term results in combination of steroids with hyaluronidase.^{19,20}

Placental extracts

It has a proposed anti-inflammatory action and thus prevents mucosal damage. Intralesional injection of aqueous extract of human placental extracts (PE) showed marked improvement of the condition as it has biogenic stimulator action and it stimulates metabolism, increases the vascularity, promotes regeneration and recovery of the tissue.^{21,22}

In severe cases, surgical excision of fibrotic bands with coronoidectomy and bilateral temporalis myotomy and split thickness skin grafting along with continuous post-op physiotherapy has proven successful outcomes.⁵

Physiotherapy

Regular jaw muscle stretching exercises with Heinster mouth gag is helpful to prevent further limitation of mouth opening especially after intralesional treatment or surgery.²³

Follow up and further care: every patient should have a regular visit for early detection of dysplasia or carcinoma. Biopsy should be done from doubtful lesions of fibrosis with leukoplakia.²⁴

Government has started public health awareness campaign and de-addiction affiliated centre for awareness and knowledge of disadvantage of tobacco chewing habits and its association with malignancy. Its preventive and curative management for early cases and education regarding orodental hygiene and abstinence from various addictions.¹ All precaution needs to be taken for avoiding morbid conditions.

Aim of the study was to present the comparative therapeutic effect of placental extract vs the combination triamcinolone and hyaluronidase and also, to assess its efficacy in improvement of mouth opening, burning sensation of mouth in OSMF.

METHODS

We have done comparative study of 60 cases which was conducted in patients attending ENT OPD of tertiary care hospital from September 2015 to May 2019 by randomized clinical trial.

Inclusion criteria

60 cases who were clinically diagnosed as OSMF with age between 17-55 years were included. Interpretation was done with respect to measurement of inter incisor distance by measuring scale for the mouth opening and subjective grading of burning sensation in oral cavity before and after the course of intralesional agents.

Exclusion criteria

Patients who were having leukoplakia, erythroplakia, oral candidiasis and other causes of trismus like malignancy were excluded.

This study assessed the effectiveness of the given intralesional agents. After the clinical examination and provisional diagnosis, we had categorized the patients into two groups for treatment viz group A and B.

Group A

Consisted of first 30 patients who received combined injection triamcinolone 40 mg reconstituted with injection hyaluronidase (1500 IU).

Group B

Included other set of 30 patients who received 2 ml injection placental extract alone.

By using 2 ml syringe with a 26 G no needle injections were given intralesionally till blanching occurred. The same dose was repeated every 7th day and a total of six doses were given. At the same time all patients received oral antioxidants twice daily for three months along with jaw stretching exercises every day.

We have measured the mouth opening of upper and lower central inter incisor distance pre and post therapy and tabulated their results. The inter incisor distance of mouth opening is categorized into: stage I (>3 cm), stage II (2-3 cm) and stage III (<2 cm).

The improvement in food intake was also recorded by subjective measurement scale which was defined as >75% = good, 50-75% = moderate and <50% = poor.

Patients were reviewed after 3 months of subsequent follow-up for the same parameters with the ancillary treatment modalities remaining the same.

Microsoft office 2007 was used to make tables and graphs. Descriptive statistical analysis like percentages, mean was used to interpret the data and conclude the results.

RESULTS

The 30 patients of each groups, after sixth course of intralesional injection were followed regularly once in a month till three months. The findings with improvements and side effects were noted by direct patient interview and observation.

Group A

Patients who received combination of triamcinolone with hyaluronidase injection

The 30 patients were treated with a combination of intralesional injections of triamcinolone 40 mg with hyaluronidase 1500 IU given in each sitting once a week for 6 weeks (Figure 2).

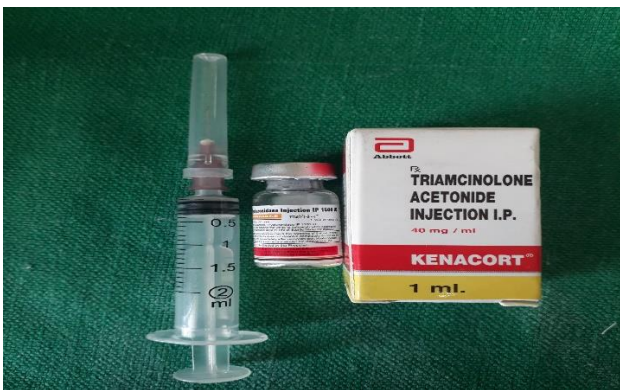

Figure 2: Injection triamcinalone 40 mg and hyaluronidase 1500IU with 2 ml syringe.

Improvement in mouth opening varied from 0.6-1.4 cm with an average of 1cm with good subjective improvement for burning sensation for hot and spicy food. Twenty-one patients showed more than 75% improvement and seven patients between 50-75%.

Among these thirty patients there were no side effects except for two patients (23 years and 40 years old female) who had complaints of slight facial puffiness after sixth dose which later subsided spontaneously.

Group B

Patients who received placental extract injection

For the other 30 patients; intralesional injection of one vial of 2 ml of placental extract in each sitting once a week for 6 weeks, the improvement in mouth opening varied from 0.4 to 1.0 cm with an average of 0.7 cm and also with good subjective improvement for burning sensation (Table 1). Fourteen patients showed more than

75% improvement and eleven patients between 50-75% improvement. In general, the results were tabulated as follows.

Table 1: Result of intralesional regimen treatment at 3 months.

Intralesional agent	Increase in mouth opening in centimeter	>75% improvement of burning sensation N (%)
Triamcinolone with hyaluronidase	1.0	21 (70)
Placental extract	0.7	14 (46.6)

Age groups

The study groups patients vary from 17-55 years, with majority, 55% belongings to 17-30 age groups and 31.66% were of 31-45 age groups and 13.33% were of more than 45 year of age.

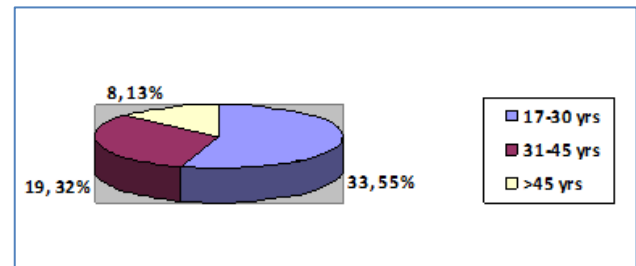


Figure 3: Age distribution.

Sex

In these sixty patients; 43 were males and 17 were females. i.e. (71.66% and 28.33% respectively) were affected by OSMF. Some studies having conflicting result may be due to the in-chewing habits and oral hygiene among gender.

Table 2: Sex distribution.

Sex	Male	Female
N (%)	43 (71.66)	17 (28.33)

Major symptoms distribution, out of sixty patients, forty 66.67% had burning sensation and decreased mouth opening since, 1-3 years duration. Seventeen (28.33%) patients had complaints of more than 3 years. But three (5%) patients had history of less than 1 year.

Some of the patients were habituated to multiple chewing products. Almost all patients had exposure to these chewing habits for more than two years with an average of 4-5 times a day but out of these sixty only four patients had surprisingly history of chewing habits of less than one year.

Table 3: Duration and distribution of symptoms.

Duration of symptoms in year	<1	1-3	>3
Burning sensation of mouth (no. of patients)	3	40	17
Decreased mouth opening (no. of patients)	3	40	17

Table 4: No. of cases with addictions.

Habits	No. of cases
Tobacco with or without paan	34
Betelnut and prepacked commercial preparation	27
Gutka	18
Misri	8
Alcohol consumption	7
Smoking	9
Goava	5

DISCUSSION

Nowadays worldwide commercially available prepacked betelnut preparation can give rise to a greater number of cases than individually prepared tobacco. These commercial preparations are cheap, easily available in every nook and corner of India with no age restriction for its sale. Hence in our study the most common age group of presentation is 17-30 years 55%, compared to Pindborg et al 75% to be of 30-60 years while Aziz et al were 45-54 years as major age groups.^{13,25}

Out of the sixty patients 71.66% were males and 28.33% were females that is 2.53:1 ratio noted in this study, compared to Pindborg (1:1), Aziz (1:2.3).^{13,25} Males were more predominantly affected than females and found in all socioeconomic strata may be due to outdoor stress with excessive chewing habits and longtime keeping intraoral quid at work.²⁶

It is noted in this study that many patients had long standing chewing habit with more with frequency more than 5-6 times per day developed OSMF earlier than four patients who had an exposure less than one year.

In our study, addiction of tobacco chewer 56.6% (34 patients), betelnut and its commercial prepacked preparation users 45% (27 patients), guthka 30% (18 patients) were users and 13.33% were (8 patients) MISRI users. There was no patient without any chewing habits. Due to its carcinogenic effect, it has chances of developing OSMF.

Both the groups were treated with oral antioxidants and physiotherapy simultaneously along with intralesional injections.

For the first group A thirty patients with combined injection of triamcinolone 40 mg with hyaluronidase 1500IU intralesionally like Shah et al study, we had improvement in mouth opening with an average of 1cm

and with good subjective improvement for burning sensation for hot and spicy foods.²¹ Twenty-one patients showed more than 75% improvement for burning sensation with nearly similar effects in study of James et al.¹⁹ Only two female patients had facial puffiness after sixth dose of injection, which was subsided spontaneously in contrast with the study of Singh et al, in which no significant side effects were noted while study by Goswami et al noted post-injection pain reduced with analgesics.^{27,28}

The group B another thirty patients was given intralesional 2ml placental extract every 7th day for six weeks. Gupta and others study came up with nearly same results as our study.^{16,21,22} The improvement seen in our study in mouth opening after six courses of intralesional PE injection with an average of 0.7cm and also with good improvement in burning sensation for hot and spicy foods. Fourteen patients had more than 75% improvement. No side effects were noted in our and Gupta et al study.¹⁶

Although injection placental extract is reasonably cheaper than combined regimen injection triamcinolone and hyaluronidase. The effectiveness of both the injections showed not much difference which is also seen in study of Shah PH.²¹ Still we preferred comparatively superior therapeutic effect with i.e. combined intralesional regimen over placental extract.^{19,28} In severe cases of trismus due to OSMF, surgery will be required.⁵

Every care should be taken for good nutrition and good orodental hygiene. Patients should be counselled regarding importance of discontinuing the chewing habits. Public health campaign and de-addiction government centers available to improve knowledge and awareness of side effects and reduction of chewing habits.

CONCLUSION

Oral submucous fibrosis is a precancerous condition of oral mucosa. OSMF purely lifestyle habit related condition which can be preventable. OSMF has no definitive treatment but comparatively effective improvement was seen in major symptoms more with a combined regimen of intralesional triamcinolone 40mg with hyaluronidase 1500IU intralesionally than placental extract. Added with continuous physiotherapy and oral antioxidants will helps in improvement of OSMF.

ACKNOWLEDGEMENTS

We are grateful to the Dean Sir, Dr R. N. Bharmal, TN Medical College and BYL Nair Charitable Hospital, Mumbai Central, Mumbai for allowing us to publish this article.

Funding: No funding sources

Conflict of interest: None declared

Ethical approval: The study was approved by the Institutional Ethics Committee

REFERENCES

- Aziz SR. Oral submucous fibrosis: an unusual disease. *J N J Dent Assoc.* 1997;68(2):17-9.
- Lal D. Diffuse Oral Submucous Fibrosis. *J All India Dent Assoc.* 1953;26:1-3.
- Paymaster JC. Cancer of the buccal mucosa. A clinical study of 650 cases in Indian patients. *Cancer.* 1956;9(3):431-5.
- Shieh DH, Chiang LC, Lee CH, Yang YH, Shieh TY. Effects of arecoline, safrole, and nicotine on collagen phagocytosis by human buccal mucosal fibroblasts as a possible mechanism for oral submucous fibrosis in Taiwan. *J Oral Pathol Med.* 2004;33(9):581-7.
- Canniff JP, Harvey W, Harris M. Oral submucous fibrosis: its pathogenesis and management. *Br Dent J.* 1986;160(12):429-34.
- Haque MF, Meghji S, Khitab U, Harris M. Oral submucous fibrosis patients have altered levels of cytokine production. *J Oral Pathol Med.* 2000;29(3):123-8.
- Trivedy CR, Warnakulasuriya KA, Peters TJ, Senkus R, Hazarey VK, Johnson NW. Raised tissue copper levels in oral submucous fibrosis. *J Oral Pathol Med.* 2000;29(6):241-8.
- Arakeri G, Brennan PA. Oral submucous fibrosis: an overview of the aetiology, pathogenesis, classification, and principles of management. *Br J Oral Maxillofac Surg.* 2013;51(7):587-93.
- Jayanthi V, Probert CS, Sher KS, Mayberry JF. Oral submucosal fibrosis: a preventable disease. *Gut.* 1992;33(1):4-6.
- Guruprasad R, Nair PP, Singh M, Singh M, Singh M, Jain A. Serum vitamin c and iron levels in oral submucous fibrosis. *Indian J Dent.* 2014;5(2):81-5.
- Wang YP, Wu YC, Cheng SJ, Chen HM, Sun A, Chang JY. High frequencies of vitamin B12 and folic acid deficiencies and gastric parietal cell antibody positivity in oral submucous fibrosis patients. *J Formos Med Assoc.* 2015;114(9):813-9.
- More CB, Das S, Patel H, Adalja C, Kamatchi V, Venkatesh R. Proposed clinical classification for oral submucous fibrosis. *Oral Oncol.* 2012;48:200-2.
- Pindborg JJ, Bhonsle RB, Murti PR, Gupta PC, Daftary DK, Mehta FS. Incidence and early forms of oral submucous fibrosis. *Oral Surg Oral Med Oral Pathol.* 1980;50(1):40-4.
- Dionne KR, Warnakulasuriya S, Zain RB, Cheong SC. Potentially malignant disorders of the oral cavity: current practice and future directions in the clinic and laboratory. *Int J Cancer.* 2015;136(3):503-15.
- Shih YH, Wang TH, Shieh TM, Tseng YH. Oral Submucous Fibrosis: A Review on Etiopathogenesis, Diagnosis, and Therapy. *Int J Mol Sci.* 2019;20(12):2940.
- Gupta J, Shrinivasan SV, Daniel JM. Efficacy of betamethasone, placental extract and hyaluronidase in the treatment of OSMF: a comparative study. *E J Dentistry.* 2012;2(1):132-5.
- Rajendran R. Oral submucous fibrosis. *J Oral Maxillofac Pathol.* 2003;7:1-4.
- Tilakaratne WM, Ekanayaka RP, Herath M, Jayasinghe RD, Sitheequ M, Amarasinghe H. Intralesional corticosteroids as a treatment for restricted mouth opening in oral submucous fibrosis. *Oral Surg Oral Med Oral Pathol Oral Radiol.* 2016;122(2):224-31.
- James L, Shetty A, Rishi D, Abraham M. Management of oral submucous fibrosis with injection of hyaluronidase and dexamethasone in grade III oral submucous fibrosis: a retrospective study. *J Int Oral Health.* 2015;7(8):1-4.
- Daga D, Singh RK, Pal US, Gurung T, Gangwar S. Efficacy of oral colchicine with intralesional hyaluronidase or triamcinolone acetonide in the Grade II oral submucous fibrosis. *Natl J Maxillofac Surg.* 2017;8(1):50-4.
- Shah PH, Venkatesh R, More CB, Vassandacoumara V. Comparison of Therapeutic Efficacy of Placental Extract with Dexamethasone and Hyaluronic Acid with Dexamethasone for Oral Submucous Fibrosis - A Retrospective Analysis. *J Clin Diagn Res.* 2016;10(10):63-6.
- Katharia SK, Singh SP, Kulshreshtha VK. The effects of placenta extract in management of oral submucous fibrosis. *Indian J Pharmacol.* 1992;24:181-3.
- Srikrishna NK, Kumar V. Role of Physiotherapy in the Management of Oral Submucous Fibrosis: A Case Control Study. *Int J Contemporary Med Res.* 2019;6(1):22-4.
- Kumar KK, Saraswathi TR, Ranganathan K, Devi UM, Elizabeth J. Oral submucous fibrosis: a clinico-histopathological study in Chennai. *Indian J Dent Res.* 2007;18(3):106-11.
- Aziz, Shahid R. Coming to America: Betel nut and oral submucous fibrosis. *J Am Dent Association.* 2010;141(4):423-8.
- Mathew AL, Pai KM, Sholapurkar AA, Vengal M. The prevalence of oral mucosal lesions in patients visiting a dental school in Southern India. *Indian J Dent Res.* 2008;19(2):99-103.
- Singh M, Niranjana HS, Mehrotra R, Sharma D, Gupta SC. Efficacy of hydrocortisone acetate/hyaluronidase vs triamcinolone acetonide/hyaluronidase in the treatment of oral submucous fibrosis. *Indian J Med Res.* 2010;131:665-9.
- Goswami R, Gangwani A, Bhatnagar S, Singh D. Comparative study of oral nutritional supplements Vs. intralesional triamcinolone and hyaluronidase in oral submucous fibrosis. *Int J Med Res Rev.* 2014;2(2):114-8.

Cite this article as: Kale MV, Gaikwad NS. Oral submucous fibrosis: a study of qualitative and analytical treatment using intralesional injections: placental extract versus combination of steroid with hyaluronidase. *Int J Otorhinolaryngol Head Neck Surg* 2020;6:1320-5.