

Original Research Article

Clinicopathological study of thyroid swellings

Anchal Gupta*, Padam Singh Jamwal

Department of ENT, Head and Neck Surgery, SMGS Hospital, Government Medical College, Jammu, Jammu and Kashmir, India

Received: 15 March 2020

Accepted: 31 March 2020

***Correspondence:**

Dr. Anchal Gupta,

E-mail: anchalsachit@gmail.com

Copyright: © the author(s), publisher and licensee Medip Academy. This is an open-access article distributed under the terms of the Creative Commons Attribution Non-Commercial License, which permits unrestricted non-commercial use, distribution, and reproduction in any medium, provided the original work is properly cited.

ABSTRACT

Background: Diseases of the thyroid continue to be a common clinical problem having a prevalence rate of 4 to 7% in the general population.

Methods: This retrospective study was conducted in the Department of ENT, Head and Neck Surgery, SMGS Hospital, Jammu from January 2018 to January 2020. A thorough history taking, meticulous clinical examination, routine hematological and biochemical investigations were done in all the patients. General examination of the patient was done and looked for thyroid functional abnormality followed by local examination was carried out to locate and identify the site of the swelling, shape, size and consistency of the thyroid swelling and clinical diagnosis was made. All thyroid swelling cases were subjected to fine needle aspiration cytology (FNAC). The type of thyroidectomy is based on the size and type of thyroid whether neoplastic or non-neoplastic. All the specimens were sent for histopathological examination.

Results: Out of 60 patients in the study, 56 were females and only 4 were males. The most common age group was 31 to 40 years seen in 24 (40%) patients. The most common presenting symptom was swelling in the neck seen in 58 (96.67%) patients. The most common diagnosis on FNAC was colloid goiter seen in 40 (66.67%) patients. The most common was benign nodular colloid goiter seen in 35 (58.33%) patients.

Conclusions: Fine needle aspiration is a very useful and indispensable test in the diagnosis of thyroid lesions.

Keywords: FNAC, Thyroid, Swelling

INTRODUCTION

Thomas Wharton first coined the term “thyroid” because of the organ’s close proximity to the thyroid cartilage (120-200 A.D). The word thyroid is derived from the Greek “thyros” meaning “shield” because it was originally considered to protect the larynx.¹

Normal thyroid gland is impalpable. Enlargement of thyroid gland is the most common manifestation of thyroid disease. The enlargement may be either generalized or localized which again may be toxic or nontoxic. The nontoxic goiter is further divided on etiological basis as endemic goiter and sporadic goiter.

The endemic goiter is defined as one where more than 10% of population shows thyroid enlargement.² Lesion of thyroid are predominantly confined to females in the ratio of 5:1. The fine needle aspiration method for studying the thyroid was first developed in Sweden in the Rudiunhelmet Hospital of Stockholm in the 1950s.³ Frable et al used the fine needle aspiration cytology (FNAC) as a means of diagnosing most thyroid masses as either neoplasm or goitre nodules.⁴ Treatment modalities of thyroid swellings depend on the clinical presentation and pathological evaluation of thyroid swellings.

The main aim of the study is to analyze the clinical presentation of thyroid swellings and to study the role of FNAC in the diagnosis of thyroid swelling.

METHODS

This retrospective study was conducted in the Department of ENT, Head and Neck Surgery, SMGS Hospital, Jammu from January 2018 to January 2020. A thorough history taking, meticulous clinical examination, routine hematological and biochemical investigations were done in all the patients. General examination of the patient was done and looked for thyroid functional abnormality followed by local examination was carried out to locate and identify the site of the swelling, shape, size and consistency of the thyroid swelling and clinical diagnosis was made.

All thyroid swelling cases were subjected to FNAC as out-patient procedure after explaining the details of the procedure to the patient and taking an informed written consent.

All patients were explained about the lesions based on the FNAC report and were advised surgery. Patients who were willing for surgery were included in the study. The type of thyroidectomy is based on the size and type of thyroid whether neoplastic or non-neoplastic.

All the specimens were fixed in 10% buffered formalin and sent for histopathological examination.

The collected data was analysed using Microsoft Excel and presented in number and percentages.

RESULTS

60 patients were included in the study.

Age and sex distribution of patients

Out of 60 patients in the study, 56 were females and only 4 were males. The youngest patient in our study was 14 years old and eldest patient was 68 years old. The most common age group was 31 to 40 years seen in 24 (40%) patients. The overall average age was 32.5 years. In females it was 33.4 years whereas in males it was 28 years.

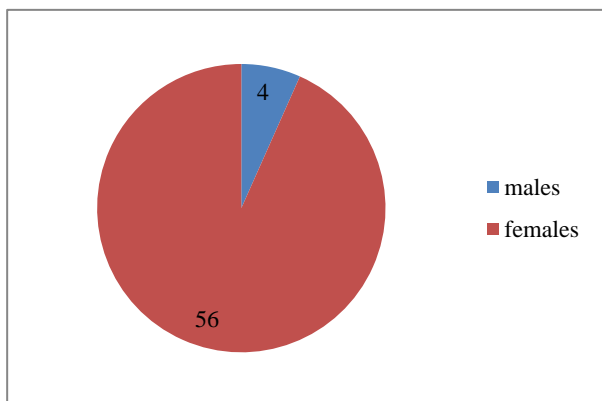


Figure 1: Gender wise distribution of patients.

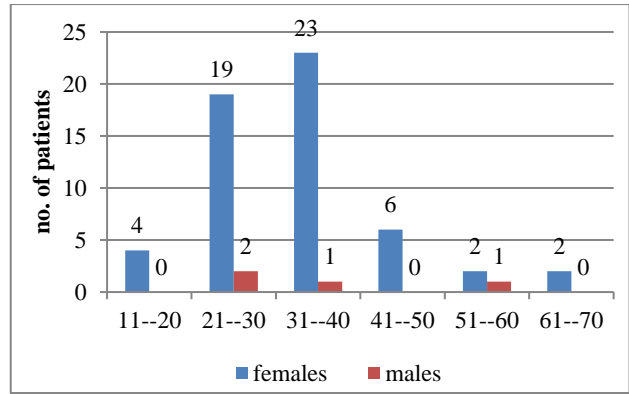


Figure 2: Age wise and gender wise distribution of patients.

Clinical presentation of patients

The most common presenting symptom was swelling in the neck seen in 58 (96.67%). Next most common symptom was pressure symptoms seen in 4 (6.67%) patients. 3 (5%) patients presented each with pain and neck nodes whereas 1 (1.67%) each presented with dysphagia and voice change (Figure 3).

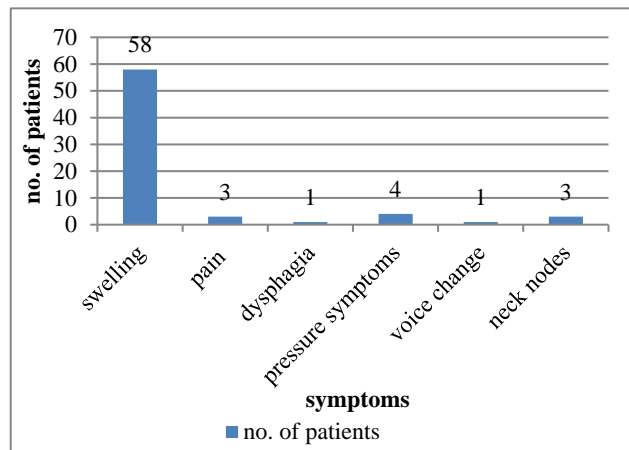


Figure 3: Distribution of patients according to symptoms.

Table 1: Distribution of patients according to FNAC findings.

FNAC findings	No. of patients	%
Colloid goiter	40	66.67
Thyroid cyst	3	5
Thyroiditis	2	3.33
Follicular neoplasm	8	13.33
Atypical adenoma	4	6.67
Papillary carcinoma	3	5

FNAC findings

After thorough general and local examination FNAC was done in all the 60 patients. The most common diagnosis

was colloid goiter seen in 40 (66.67%) patients. Next most common diagnosis was follicular neoplasm followed by atypical adenoma, thyroid cyst, carcinoma and thyroiditis respectively in decreasing order (Table 1).

Type of surgery

All the 60 patients included in the study underwent thyroidectomy. 3 patients who were diagnosed as papillary carcinoma on FNAC underwent total thyroidectomy along with neck dissection depending on levels of lymph nodes involved. Figure 4 shows distribution of patients according to type of thyroidectomy they underwent.

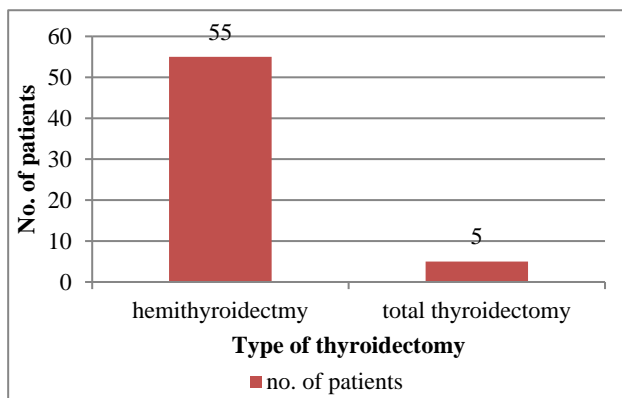


Figure 4: Type of thyroidectomy.

Histopathological diagnosis

All the thyroidectomy specimens were sent for histopathological examination. Table 2 shows distribution of patients according to histopathological diagnosis.

The most common was benign nodular colloid goiter seen in 35 (58.33%) patients followed by thyroiditis seen in 12 (20%) patients, follicular adenoma seen in 8 (13.33%) patients, papillary carcinoma seen in 3 (5%) patients and follicular carcinoma seen in 2 (3.33%).

Table 2: Distribution of patients according to histopathological diagnosis.

Histopathological diagnosis	No. of patients	%
Benign nodular colloid goiter	35	58.33
Thyroiditis	12	20
Follicular adenoma	8	13.33
Papillary carcinoma	3	5
Follicular carcinoma	2	3.33

DISCUSSION

Thyroid lesion usually presents with swelling of thyroid gland with or without hyper or hypofunction of thyroid

gland. The incidence of thyroid lesions is increasing in recent years. Thyroid surgery is nowadays associated with low morbidity and extremely low mortality. Out of 60 patients in the study, 56 were females and only 4 were males with female: male ratio of 14:1. The most common age group was 31 to 40 years seen in 24 (40%) patients. There is a wide variation of this ratio among different studies, Likhari et al had a ratio of 11.5:1, whereas Sengupta et al had a ratio of 3.8:1.^{5,6} This is in agreement with the study conducted by Sengupta et al with mean age of 35.39 years and maximum incidence among age group 31 to 40 years.⁶

The most common diagnosis was colloid goiter seen in 40 (66.67%) patients. Next most common diagnosis was follicular neoplasm followed by atypical adenoma, thyroid cyst, carcinoma and thyroiditis respectively in decreasing order.

The most common histopathological diagnosis was benign nodular colloid goiter seen in 35 (58.33%) patients followed by thyroiditis seen in 12 (20%) patients, follicular adenoma seen in 8 (13.33%) patients, papillary carcinoma seen in 3 (5%) patients and follicular carcinoma seen in 2 (3.33%). These findings are similar to findings by Rout et al and Wahid et al.^{7,8}

CONCLUSION

Thyroid swellings are common in females they occur in 3rd and 4th decade most commonly. FNAC is very useful in the diagnosis.

Funding: No funding sources

Conflict of interest: None declared

Ethical approval: The study was approved by the Institutional Ethics Committee

REFERENCES

1. Medvei VC. A history of endocrinology. In: Kovacs K, Asa Science; 1998.
2. Maitra A. Thyroid gland. In: Kumar V, Abbas AK, Fausto N, Aster JC, editors. Robbins and Cotran Pathological Basis of Disease. 8th Ed. Philadelphia: Saunders Co; 2010: 1107-1126.
3. Galera-Davidson, Gonzalez-Campora R. Thyroid. In: Bibbo M, Wilbur D, editors. Comprehensive Cytopathology. 3rd ed. Philadelphia: Saunders Elsevier; 2008: 633
4. Frable WJ, Frable MA. Thin needle aspiration biopsy: The diagnosis of head and neck tumours revisited. Cancer. 1979;43:1541-8.
5. Likhari KS, Hazari RA, Gupta Sg, Shukla U. Diagnostic accuracy of fine needle aspiration cytology in thyroid lesions: A hospital based study. Thyroid Res Pract. 2013;10(2):68-71.
6. Sengupta A, Pal R, Kar S, Zaman FA, Sengupta S, Pal S. Fine needle aspiration cytology as diagnostic

tool in thyroid enlargement. *J Nat Sci Biol Med.* 2011;2(1):113-8.

7. Rout K, Ray CS, Behera SK, Biswal R. A comparative study of FNAC and histopathology of thyroid swellings. *Indian J Otolaryngol Head Neck Surg.* 2011;63(4):370-2.
8. Wahid FI, Hussain M, Khan A, Ahmadkhan I. Diagnostic yield of fine needle aspiration cytology in the diagnosis of Thyroid Nodule and its

comparison with national and international studies. *ISRA Med J.* 2012;4(4):230-4.

Cite this article as: Gupta A, Jamwal PS. Clinicopathological study of thyroid swellings. *Int J Otorhinolaryngol Head Neck Surg* 2020;6:974-7.