

Original Research Article

Traumatic facial nerve palsy: evaluation and surgical management

Chaitry K. Shah, Shalu Gupta*, Bela J. Prajapati, Devang P. Gupta, Viral Prajapati

Department of Otorhinolaryngology, B. J Medical College, Ahmedabad, Gujarat, India

Received: 22 March 2020

Revised: 14 April 2020

Accepted: 15 April 2020

***Correspondence:**

Dr. Shalu Gupta,

E-mail: Shalz.581989@gmail.com

Copyright: © the author(s), publisher and licensee Medip Academy. This is an open-access article distributed under the terms of the Creative Commons Attribution Non-Commercial License, which permits unrestricted non-commercial use, distribution, and reproduction in any medium, provided the original work is properly cited.

ABSTRACT

Background: Acute facial paralysis can result from various causes, among which intra temporal facial palsy is relatively common. Of all the cranial nerves, the facial nerve is most susceptible to injury due to its long course within the skull. Diagnosis of facial palsy is usually made by a good clinical history, examination and radiological investigations. Electrophysiological tests are important for prognosis and optimal time for surgery. The aim is to study the evaluation and surgical management in traumatic cause of facial nerve palsy.

Methods: This prospective cross-sectional study was carried out in 50 patients presented with facial nerve palsy due to trauma in civil hospital Ahmedabad over a period of 1 year from May 2018 to 2019. Patients were examined and graded using House and Brackmann grading system. All the patients were evaluated and treated by surgical decompression. Follow up was carried out upto 6 months.

Results: The cause of facial nerve palsy in all 50 patients was accidental head trauma. All the patients were managed by surgical decompression. 46 out of 50 patients managed surgically had good recovery with restoration of complete facial nerve function. 4 out 50 patients had poor recovery due to late presentation.

Conclusions: Early initiation of treatment is important for favorable recovery of facial nerve function after trauma. Surgical treatment is indicated in suspected bony impingement of nerve. Surgical decompression if done early usually results in very good recovery.

Keywords: Trauma, Facial paralysis, Surgical decompression

INTRODUCTION

Facial nerve palsy following trauma, is an uncommon condition which occurs in 1.5% patients of skull base fractures, majority of them due to road traffic accidents causing temporal bone fractures.¹ Of all the cranial nerves, the facial nerve is most susceptible to injury due to its long course within the skull as facial nerve is the only nerve which travels through bony canal hence is very much prone to fracture of bony canal and edema of nerve within the canal causing compression of facial nerve.² These fractures are classified as longitudinal and transverse fractures with respect to the long axis of petrous pyramid.³ Facial nerve palsy usually develops in transverse fracture.¹ Early diagnosis and intervention of

facial nerve injuries is essential for better prognosis. Treatment of facial nerve injury depends on onset of facial weakness and extent of facial weakness.¹ Facial nerve decompression via trans mastoid approach is suitable for patients whose nerve injury lies distal to geniculate ganglion.⁴

Indication and timing of facial nerve decompression for facial paralysis and anatomical extent of decompression has been a subject of controversy for years.⁵ The aim of this study is to present prospective review of 50 patients with facial paralysis after trauma who underwent surgical decompression of facial nerve via trans mastoid approach.

METHODS

This prospective cross-sectional study was carried out in 50 patients presented with facial nerve palsy due to trauma in civil hospital Ahmedabad over a period of 1 year from May 2018 to 2019. Patients were examined and graded using House and Brackmann grading system.⁶ All the patients were evaluated and treated by surgical decompression via trans mastoid approach.

Inclusion criteria

Inclusion criteria were traumatic facial nerve palsy caused by road traffic accidents and intra-temporal trauma to facial nerve.

Exclusion criteria

Exclusion criteria were all other causes of facial nerve palsy were excluded from study, extratemporal trauma to facial nerve and patients managed conservatively.

Out of 50 patients 38 were males and 12 were females. Age group of patients was from 15 to 55 years. Mode of injury was road traffic accidents. Other causes of facial nerve palsy were excluded from the study. All the patients treated for facial nerve palsy underwent auditory assessment (pure tone audiometry), high resolution CT scan of temporal bone, Schirmers test and electrophysiological workup consisting of electro-myography and electroneurography. Patients presenting between 3 days and 3 weeks' time were evaluated by ENoG (EMG was performed in cases showing >90% degeneration), while those presenting after 3 weeks were evaluated by EMG alone. In cases where history was not known, both serial ENoG and EMG were performed. All patients were given broad spectrum systemic antibiotics for 10 days and corticosteroids (prednisolone 1 mg/kg body weight) for 10 days in tapering dose postoperatively. All patients were advised facial physiotherapy post operatively. Follow up was carried out up to 6 months. Microsoft excel software was used to analyze the data.

RESULTS

Fifty patients underwent surgical decompression of facial nerve following facial nerve palsy post trauma. Out of 50 patients 38 (76%) were males and 12 (24%) were females. Mean age group of patients was 35 (15-55 years). Thirty-two (64%) patients had right side facial palsy while 18 (36%) patients had left side facial palsy. According to House Brackman (H-B) grading 8 (16%) patients presented with H-B grade 3, 40 (80%) patients with H-B grade 4, and 2 (4%) patients with H-B grade 5. On HRCT temporal bone 38 (76%) patients found to have transverse fracture while 12 (24%) patients had longitudinal fracture. Thirty-seven (74%) patients had immediate onset paralysis that is facial palsy developed within 3 days of trauma whereas 13 (26%) patients had

delayed onset paralysis. Intra-operatively tympanic segment of facial nerve was found to be involved in 35 (70%) patients, mastoid segment in 10 (20%) patients, first genu was involved in 3 (6%) patients and fracture line was found to be extending upto second genu in 2 (4%) patients. Intraoperative findings included temporal bone fracture line extending onto fallopian canal, impinging bony spicules, hematoma, edema, and fibrotic bands along the facial nerve. On ENoG, there was <90% degeneration in 40 (80%) patients performed within 21 days post trauma while >90% degeneration was seen in 10 (20%) patients. All the patient's surgical decompression of facial nerve via trans mastoid approach was done. Postoperatively after 3 months follow up 35 (70%) patients showed recovery of H-B grade 1 and 5 (10%) patients showed recovery of H-B grade 2. Ten (20%) patients showed no recovery upto post-operative 6 months follow up.

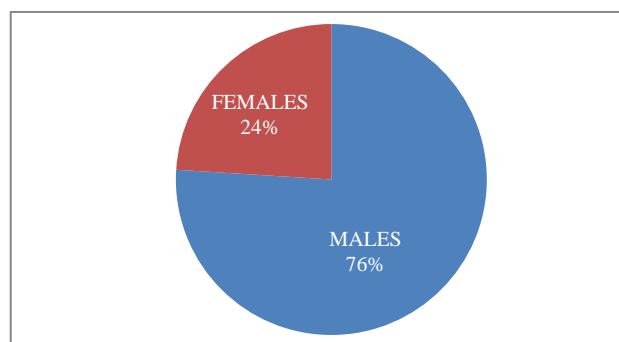


Figure 1: Sex distribution of patients.

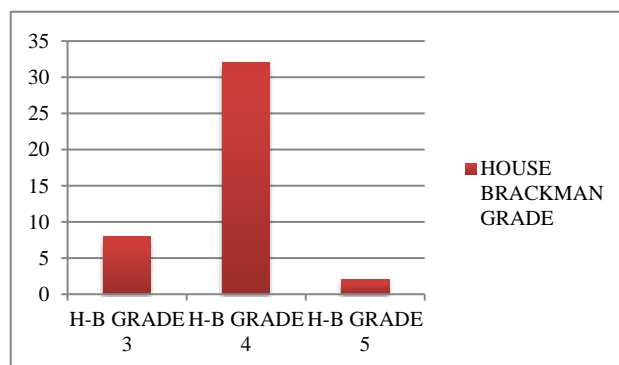


Figure 2: H-B grading distribution of patients preoperatively.

All the patients underwent general anaesthesia for the surgery. Post aural wilde's incision kept and skin, subcutaneous tissue cut and separated. Periosteum is elevated, posterior canal wall skin is then cut. Tympanomeatal flap is elevated, exposing the middle ear. Fracture line is identified and traced. Antrum is opened and wide cortical mastoidectomy is done. Incudomalleolar and incudostapedial joints are inspected for any discontinuity. Horizontal and vertical facial canal exposed. Dehiscence of facial canal is identified. Decompression of facial nerve is done 1cm proximal and

1 cm distal to dehiscent segment. Tympanomeatal flap was repositioned back. Wound was closed in layers.

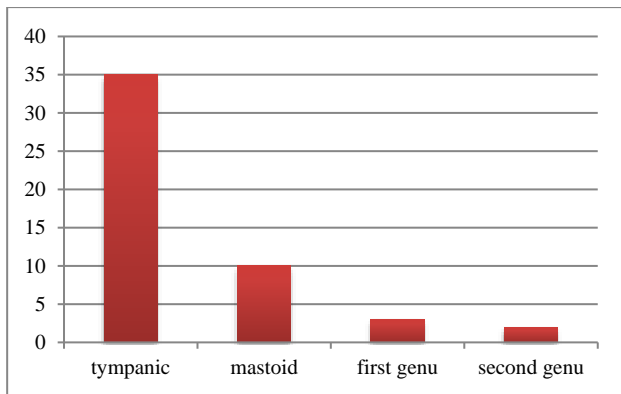


Figure 3: Distribution of segment of facial nerve involved.

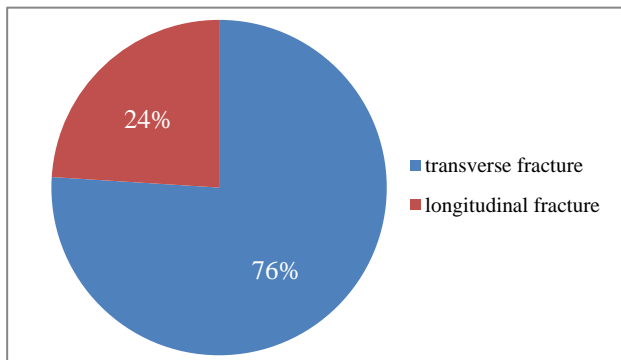


Figure 4: Distribution of type of fracture on HRCT temporal bone.

DISCUSSION

In traumatic facial nerve palsy, degeneration of 90% or more of facial nerve within 6 days of onset of complete paralysis is predictive of complete paralysis until surgical decompression is performed.⁷ Prognosis of facial nerve decompression depends upon various factors including extent of paralysis, timing of onset of paralysis, electroneurography, and timing of presentation of patient.⁸ Number of males were more than females in our study which was similar to the study done by Yadav et al.⁸ No association was observed for the various age group and required intervention for the treatment which was similar to the study done by Xu et al.⁹ In our study it was found that transverse fractures of temporal bone causes immediate onset facial paralysis in almost all the patients and longitudinal fracture causes delayed onset paralysis which was similar to the study done by Puvanendran et al.¹⁰ Tympanic segment of facial nerve was found to be involved in maximum number of patients i.e., 35 out of 50 patients which was similar to the study done by Bhatt et al. ENoG is performed between 3 to 21 days post trauma because wallerian degeneration does not become apparent until 48-72 hours after acute injury to

nerve.¹¹ After 21 days nerve degeneration is complete and the nerve excitability is lost. ENoG may be interfered by possible degeneration of nerve tubules which begins at 2-3 weeks.¹¹ EMG is done after 3 weeks. Fourteen days post onset, fibrillation potentials or positive sharp waves seen on EMG can confirm the degeneration of facial nerve.¹² In our study it was found that >90% degeneration on ENoG within first 2 weeks of trauma, the injury is severe and the recovery of function is poor and in patients whose degeneration does not reach 90% on ENoG during the first 3 weeks of paralysis, have an excellent chances of complete recovery, which was similar to the study done by Fisch and Esleen et al.^{13,14} In our study we found that early exploration within 2 weeks of trauma showed improvement in 40 (80%) patients which was similar to the study done by chang and Cass et al and Hato et al.^{15,16} Fisch advocated immediate exploration in a patient with delayed onset facial paralysis, showing >90% degeneration of fibers within 6 days of onset, with the view that evacuation of intraneural hematoma will improve the nerve function.¹⁴ On the other hand study done by Lieberherr et al showed that the patients who were operated late were found to have better facial recovery.¹⁷

CONCLUSION

Form our study we conclude that early diagnosis and surgical intervention plays a significant role in improved outcome of facial palsy post trauma. Electrodiagnostic tests were most useful in indicating prognosis very early in the disease. The trans mastoid approach for facial nerve decompression can be utilized when trauma is clearly localized to the tympanic or mastoid segment of facial nerve.

Funding: No funding sources

Conflict of interest: None declared

Ethical approval: The study was approved by the Institutional Ethics Committee

REFERENCES

1. Turel, Keki E. Post traumatic facial paralysis treatment options and strategies. Indian J Neurotrauma. 2005;2(1):33-4.
2. Dulak, Dominika, Naqvi IA. Neuroanatomy, Cranial Nerve 7 (Facial). Stat Pearls Publishing; 2018.
3. Ghorayeb, Bechara Y, Yeakley JW. Temporal bone fractures: longitudinal or oblique? The case for oblique temporal bone fractures. Laryngoscope. 1992;102(2):129-34.
4. Kahinga, Aloyce A, Han JH, Moon S. Total transcanal endoscopic facial nerve decompression for traumatic facial nerve palsy. Yonsei Med J. 2018;59(3):457-60.
5. Yetiser S. Total facial nerve decompression for severe traumatic facial nerve paralysis: a review of 10 cases. Int J Otolaryngol. 2012;2012:607359.

6. Yen TL, Driscoll CL, Lalwani AK. Significance of House-Brackmann facial nerve grading global score in the setting of differential facial nerve function. *Otol Neurotol.* 2003;24(1):118-22.
7. Gordin, Eli. Facial nerve trauma: evaluation and considerations in management. *Craniofacial Trauma Reconstruction.* 2015;8(1):1-13.
8. Yadav, Sanjeev. Surgery for post-traumatic facial paralysis: are we overdoing it. *European Archives Oto-Rhino-Laryngology.* 2018;275(11):2695-703.
9. Xu, Peng. Surgical timing for facial paralysis after temporal bone trauma. *Am J Otolaryngol.* 2017;38(3):269-71.
10. Puvanendran K, Vitharana M, Wong PK. Delayed facial palsy after head injury. *J Neurol Neurosurg Psychiatr.* 1977;40(4):342-50.
11. Patnaik, Uma, Upreti G, Nilakantan A. Surgical management of traumatic intratemporal facial nerve paralysis: Looks matter. *Indian J Otol.* 2019;25(1):11.
12. Robinson, Lawrence R. Traumatic injury to peripheral nerves. *Muscle Nerve: Official J Am Association Electrodiagnostic Med.* 2000;23(6):863-73.
13. Esslen E. Electrodiagnosis of facial palsy. In: *Surgery of the Facial Nerve.* Miehke A, ed. Philadelphia: WB Saunders; 1973: 45-51.
14. Fisch U. Total facial nerve decompression and electroneuronography. *Neurological Surg.* 1977:21-33.
15. Chang CY, Cass SP. Management of facial nerve injury due to temporal bone trauma. *Am J otology.* 1999;20(1):96-114.
16. Hato, Naohito. Facial nerve decompression surgery in patients with temporal bone trauma: analysis of 66 cases. *J Trauma Acute Care Surg.* 2011;71.6:1789-93.
17. Lieberherr U, Schwarzenbach D, Fisch U. Management of severe facial nerve paralysis in the temporal bone: a review of 82 cases. *Proceedings of the Sixth International Symposium on the facial nerve.* Amsterdam: Kugler Ghedini Publications; 1990.

Cite this article as: Shah CK, Gupta S, Prajapati BJ, Gupta DP, Prajapati V. Traumatic facial nerve palsy: evaluation and surgical management. *Int J Otorhinolaryngol Head Neck Surg* 2020;6:1111-4.