

Original Research Article

Septoplasty and septoplasty with inferior turbinoplasty in the management of nasal septal deviation with inferior turbinate hypertrophy

K. Rajashekhar, K. Parameshwar*, K. P. Goud

Department of ENT, MNR Medical College and Hospital, Sangareddy, Telangana, India

Received: 11 March 2020

Accepted: 10 April 2020

***Correspondence:**

Dr. K. Parameshwar,

E-mail: parameshent2013@gmail.com

Copyright: © the author(s), publisher and licensee Medip Academy. This is an open-access article distributed under the terms of the Creative Commons Attribution Non-Commercial License, which permits unrestricted non-commercial use, distribution, and reproduction in any medium, provided the original work is properly cited.

ABSTRACT

Background: Nasal obstruction is a highly prevalent problem caused by nasal septal deviation, with or without inferior turbinate hypertrophy. Nasal septoplasty and inferior turbinoplasty can improve the nasal airways. This study was designed to assess the efficacy of septoplasty alone and septoplasty with inferior turbinoplasty in cases having nasal septal deviation with inferior turbinate hypertrophy.

Methods: A total 70 cases clinically diagnosed with the deviated nasal septum and inferior turbinate hypertrophy were randomly divided into two groups. Group 1 cases were under septoplasty alone and group 2 cases were under septoplasty with inferior turbinoplasty. Symptom improvement scores was assessed by sino nasal outcome test-20 (SNOT-20).

Results: The mean reduction symptom score of nasal obstruction was 1.73 in septoplasty with inferior turbinoplasty group, while in septoplasty group it was 1.06. The mean reduction symptom score in group 2 was statistically significant. All the cases of group 2 had adequate first pass diagnostic nasal endoscopy (DNE). While in group 1, majority cases had inadequate first pass DNE.

Conclusions: First pass DNE findings were favourable in the cases under septoplasty with inferior turbinoplasty. Septoplasty with inferior turbinoplasty is effective in the reduction of nasal obstruction, facial pain, sleep difficulty, decrease in attentiveness and irritability in cases having deviated nasal septum with inferior turbinate hypertrophy.

Keywords: Deviated nasal septum, Nasal obstruction, Septoplasty, Inferior turbinoplasty

INTRODUCTION

Nasal septal deviation and turbinate hypertrophy are the main causes of nasal obstruction. A large number of therapeutic options available for the nasal obstruction irrespective of its origin. However, when therapeutic care is not enough to provide good nasal permeability, surgical treatment should be indicated.¹ Septoplasty and inferior turbinoplasty are ideal procedures in the management of nasal obstruction, but they can also use as an adjunct procedure for obstructive sleep apnea, epistaxis, chronic rhinosinusitis.² Cases undergo septoplasty as treatment choice for nasal septal deviation

complain of nasal obstruction because of inferior turbinate hypertrophy.³ The present study was designed to assess the efficacy of septoplasty alone and septoplasty with inferior turbinoplasty in cases having nasal septal deviation with inferior turbinate hypertrophy.

METHODS

The present prospective study was conducted in the Department of ENT, MNR Medical College and Hospital, Sangareddy during April 2018 to October 2019. A total 70 cases clinically diagnosed with the deviated nasal septum and inferior turbinate hypertrophy between

age group 21-45 years were recruited. Cases without allergy to the nose, vasomotor rhinitis, deviated nasal septum with inferior turbinate hypertrophy were included. Cases with cardiovascular complications, hypertension, diabetes and cases who are not willing to participate were excluded. Informed consent was obtained from all the cases and study protocol was approved by institutional ethics committee.

Study participants were randomly divided into two groups. Cases of group 1 undergone by septoplasty alone and cases of group 2 undergone by septoplasty with inferior turbinoplasty. All the study participants were undergone to CT paranasal air sinuses, Total haemogram

and diagnostic nasal endoscopy. A zero-degree Hopkins rod lens endoscope was used, after infiltration without applying decongesting cotton patties, septoplasty done by making a Freer's incision on the nasal septum on the side where there is caudal dislocation of nasal septum. 3-5 ml of 2% lignocaine with 1:100000 adrenalin solution was administered into sub mucoperichondrial layer of the septum and to the submucosa of both inferior turbinates.

RESULTS

Among two study groups, males (62.8% in group 1, 71.4% in group 2) were more than female cases (37.14% in group 1 and 28.5% in group 2) (Table 1).

Table 1: Gender wise distribution of study participants.

Variables	Male		Female	
	Number	Percentage	Number	Percentage
Group 1	22	62.8	13	37.14
Group 2	25	71.4	10	28.5

Table 2: Status of clinical symptoms before and after surgery.

Variables	Before surgery	After surgery
	Mean±SD	Mean±SD
Nasal obstruction		
Group 2	3.74±0.32	2.01±0.22
Group 1	3.55±0.52	2.49±0.43
P value		0.002
Facial pain		
Group 2	3.68±0.28	2.02±0.44
Group 1	3.14±0.41	2.08±0.45
P value		0.001
Sleeping difficulty		
Group 2	3.41±0.50	1.98±0.41
Group 1	3.38±0.52	2.54±0.43
P value		0.001
Decrease in attentiveness		
Group 2	3.01±0.58	1.72±0.60
Group 1	2.85±0.58	1.98±0.53
P value		0.003
Irritability		
Group 2	3.25±0.50	2.83±0.28
Group 1	2.92±0.57	2.78±0.33
P value		0.001
Total symptom score		
Group 2	17.05±1.45	9.65±1.81
Group 1	16.24±1.83	11.98±1.65
P value		0.001

In group 2, the mean reduction symptom score of nasal obstruction was 1.73, whereas in group 1 it was 1.06. Facial pain showed mean reduction score 1.43 in group 2 and 1.06 in group 1. The mean reduction symptom score

of sleeping difficulty in group 2 was 1.43, while in group 1 was 0.84.

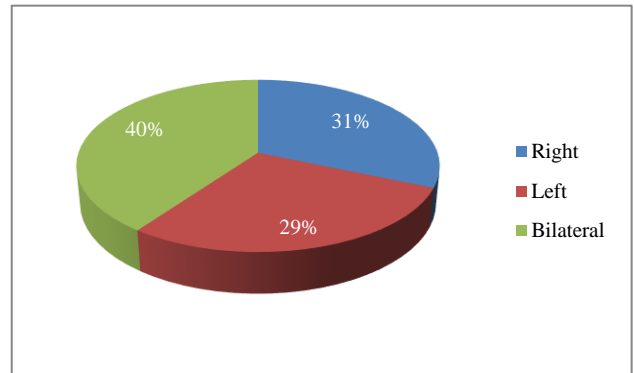


Figure 1: Number of cases undergone turbinoplasty with septoplasty (study group).

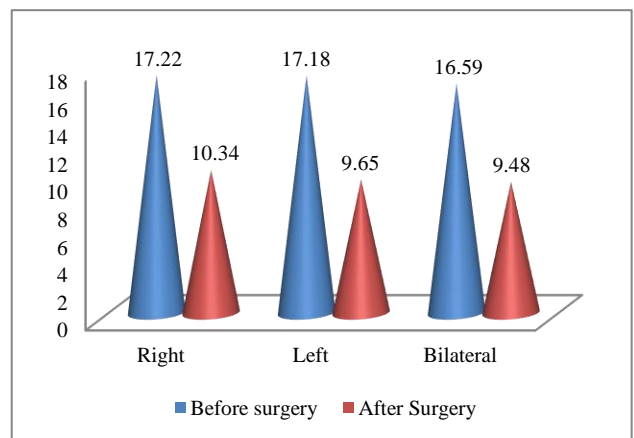


Figure 2: Mean total symptom score of cases undergone turbinoplasty with septoplasty before and after surgery.

Table 3: Comparison of DNE first pass adequacy and inadequacy among two study groups.

Side	Adequate		Inadequate	
	Group 1 (n=35) N (%)	Group 2 (n=35) N (%)	Group 1 (n=35) N (%)	Group 2 (n=35) N (%)
Right	08 (22.85)	-	10 (28.57)	-
Left	11 (31.42)	-	07 (20)	-
Bilateral	-	35 (100)	18 (51.43)	-

Attentiveness score was improved 1.29 in group 2 and 0.87 in group 1. The symptom score of irritability was reduced 0.42 in group 2 and 0.14 in group 1 (Table 2).

In the cases of group 2, after septoplasty with inferior turbinoplasty the first pass in diagnostic nasal endoscopy (DNE) is adequate and none of the cases had inadequate first pass DNE.

While in group 1, 8 cases and 10 cases had adequate and inadequate first pass DNE on right side and 11 cases and 7 cases had adequate and inadequate first pass DNE on left side respectively (Table 3).

DISCUSSION

Deviated nasal septum and inferior turbinate hypertrophy are the commonest causes for nasal obstruction.⁴ Septoplasty is ideal procedure in the management of nasal obstruction but has complaints of recurrence.⁵ This study was aimed to assess the efficacy of septoplasty alone and septoplasty combine with inferior turbinoplasty in the management of deviated nasal septum. A total 70 cases diagnosed with deviated nasal septum and inferior turbinate hypertrophy between age group 21-45 years were included. Study participants were randomly divided into two groups. Cases of group 1 undergone septoplasty alone and cases of group 2 undergone septoplasty with inferior turbinoplasty. Among two study groups, males (62.8% in group 1, 71.4% in group 2) were more than female cases (37.14% in group 1 and 28.5% in group 2) (Table 1).

In this study, in group 2, the mean reduction symptom score of nasal obstruction was 1.73, whereas in group 1 it was 1.06. Velasco et al, in their study on post-operative evaluation of nasal obstruction found that septoplasty with or without turbinoplasty had same improvement of all symptoms.⁶ Study by Lee et al, found an overall improvement in nasal obstruction by 91% and also stated that powered endoscopic turbinoplasty is an ideal procedure to manage chronic hypertrophic rhinitis in adjunct to endoscopic septoplasty.⁷ Study by Bandos et al, stated that improvement in relief of nasal obstruction was seen in 90% cases undergone by septoplasty with partial inferior turbinectomy.⁸ Study by Stolzel et al, stated that septoplasty with turbinectomy is an ideal treatment choice in relief of nasal obstruction symptoms

than septoplasty alone.⁹ Study by Elwany et al, Bambirra et al reassessed their study cases one year after PIT, obtained 82.72% and 75% improvement in nasal obstruction respectively.^{10,11}

Facial pain showed mean reduction score 1.43 in group 2 and 1.06 in group 1. The mean reduction symptom score of sleeping difficulty in group 2 was 1.43, while in group 1 was 0.84. Attentiveness score was improved 1.29 in group 2 and 0.87 in group 1. The symptom score of irritability was reduced 0.42 in group 2 and 0.14 in group 1. The total improvement in symptom score in group 2 cases was 7.40, while cases of group 1 has improvement symptom score 4.26 (Table 2). in the management of deviated nasal septum than septoplasty alone. Moore and Eccles, in their review stated that septal surgery improves nasal patency and airflow.¹² In this study, all the cases of group 2 had adequate first pass DNE. While in group 1, majority cases had inadequate first pass DNE (Table 3).

Bhandarkar et al, stated that inferior turbinate surgery is an effective method in the management of turbinate hypertrophy, which is not responsive to medical therapy.¹³ Study by Kumar et al, stated that septoplasty with turbinectomy is an ideal treatment method in the management of deviated nasal septum than septoplasty alone.¹⁴ Study by Karodpati et al, stated that septoplasty with turbinectomy is efficient in the treatment of symptomatic deviated nasal septum and cases had significant reduction in symptoms of nasal blockage, breathing, sleep disturbances and nasal congestion.¹⁵ The findings of present study showed significant reduction in symptoms of nasal obstruction, facial pain, sleep difficulty, decrease in attentiveness and irritability.

CONCLUSION

The results of this study conclude that septoplasty with inferior turbinoplasty is effective in the reduction of nasal obstruction, facial pain, sleep difficulty, decrease in attentiveness and irritability in cases having deviated nasal septum with inferior turbinate hypertrophy. Septoplasty alone has minimal efficacy in reducing symptoms post operatively.

Funding: No funding sources

Conflict of interest: None declared

Ethical approval: The study was approved by the Institutional Ethics Committee

REFERENCES

1. Schmelzer B, Katz S, Vidts G. Long-term efficacy of our surgical approach to turbinate hypertrophy. *Am J Rhinol.* 1999;13(5):199-201.
2. Shamanna K, Godse A. Comparative Study on Outcome of Septoplasty with or without Turbinoplasty Based on NOSE Score. *Res Otolaryngol.* 2018;7(3):55-9.
3. Courtiss EH. Management of inferior turbinate hypertrophy. *Plast Reconstr Surg.* 1999;104:1197-98.
4. Egeli E, Demirci L, Yazycy B, Harputlouglu U. Evaluation of the inferior turbinate in patients with deviated nasal septum by using computed tomography. *Laryngoscope.* 2004;114(1):113-7.
5. Han JK, Stringer SP, Rosenfeld RM, Archer SM, Baker DP, Brown SM, et al. Clinical Consensus Statement: Septoplasty with or without Inferior Turbinate Reduction. *Otolaryngol Head Neck Surg.* 2015;153(5):708-20.
6. Velasco L. Assessment of symptom improvement following nasal Septoplasty with or without turbinectomy. *Brazilian J Otorhinolaryngol.* 2011;77(5):577-83.
7. Lee CF, Chen TA. Power microdebrider-assisted modification of endoscopic inferior turbinoplasty: A Preliminary Report. *Chang Gung Med J.* 2004;27:359-65.
8. Bandos RD, Mello VRD, Ferreira MDS, Rossato M, Lima WTA. Clinical and ultrastructural study after partial inferior turbinectomy. *Rev Bras Otorrinolaringol.* 2006;72(5):609-16.
9. Stolzel K, Bandelier M, Szczepek AJ, Olze H, Dommerich S. Effects of surgical treatment of hypertrophic turbinates on the nasal obstruction and the quality of life. *Am J Otolaryngol.* 2017;38(6):668-72.
10. Elwany S, Harrison R. Inferior turbinectomy: comparison of four techniques. *J Laryngology Otol.* 1990;104:206-9.
11. Bambilra S. *Cirurgia da Obstrucao Nasal: uma avaliacao clinica e histologica pre e pos-operatoria.* 1993, 122f. Dissertacao (Mestrado em Otorrinolaringologia). Faculdade de Medicina de Ribeirao Preto, Universidade de Sao Paulo. 1993.
12. Moore M, Eccles R. Objective evidence for the efficacy of surgical management of the deviated septum as a treatment for chronic nasal obstruction: a systematic review. *Clin Otolaryngol.* 2011;36:106-13.
13. Bhandarkar ND, Smith TL. Outcomes of surgery for inferior turbinate hypertrophy. *Curr Opin Otolaryngol Head Neck Surg.* 2010;18(1):49-53.
14. Kumar DR, Rajashekar M. Comparative Study of Improvement of Nasal Symptoms Following Septoplasty with Partial Inferior Turbinectomy Versus Septoplasty Alone in Adults by NOSE Scale: A Prospective Study. *Indian J Otolaryngol Head Neck Surg.* 2016;68(3):275-84.
15. Karodpati N, Ingale M, Rawat S, Kuradagi V. Comparing the outcome of septoplasty and septoplasty with turbinectomy in patients with deviated nasal septum. *Int J Otorhinolaryngol Head Neck Surg.* 2019;5:1185-9.

Cite this article as: Rajashekhar K, Parameshwar K, Goud KP. Septoplasty and septoplasty with inferior turbinoplasty in the management of nasal septal deviation with inferior turbinate hypertrophy. *Int J Otorhinolaryngol Head Neck Surg* 2020;6:960-3.