

Case Report

Sub-glottic cysts causing upper airway obstruction

Swathi Chigicherla*, Shruti Tewari, Rahul Deo Sharma, Rajesh Nathani

Department of Pediatric Surgery, Lilavati Hospital and Research Centre, Mumbai, Maharashtra, India

Received: 03 March 2020

Revised: 12 April 2020

Accepted: 07 May 2020

***Correspondence:**

Dr. Swathi Chigicherla,

E-mail: swati9.chigicherla@gmail.com

Copyright: © the author(s), publisher and licensee Medip Academy. This is an open-access article distributed under the terms of the Creative Commons Attribution Non-Commercial License, which permits unrestricted non-commercial use, distribution, and reproduction in any medium, provided the original work is properly cited.

ABSTRACT

Wigger and Tang reported the first case of a sub-glottic cyst (SGC) in 1968. SGC are rare but potentially reversible causes of upper airway obstruction, in previously intubated children. These children present with respiratory distress and stridor, and the diagnosis is confirmed by direct laryngoscopy. The management depends on the size of the cysts and the severity of the symptoms. We are presenting two cases of SGCs who were born prematurely and were intubated for a prolonged period. They presented with stridor and were diagnosed to have sub-glottic cysts at bronchoscopy.

Keywords: Sub-glottic cyst, Stridor, Laser ablation

INTRODUCTION

The pediatric airway is funnel-shaped, and the narrowest part is at the bottom of the funnel at the level of the cricoid cartilage, because of the complete cartilaginous ring. Subglottic trauma is one of the inciting factors in the pathophysiology of subglottic cysts. If an endotracheal tube is too large, it can injure the subglottis.¹⁻³ Also, infants have a higher quantity of submucous glands than adults in their subglottis, which can then undergo cystic changes leading to subglottic cysts. The incidence of sub-glottic cyst (SGC) in the pediatric group presenting with stridor undergoing direct laryngoscopy and bronchoscopy is 6.8% to 7.2%.⁴

CASE REPORT

Case 1

A preterm baby (34 weeks of gestation) with low birth weight (1.8 kg) was ventilated for three days at the time of birth, for respiratory distress. At one year of age, the child developed a lower respiratory tract infection and

required difficult intubation. It was difficult to wean her off the ventilator, and she remained on a ventilator for all of 20 days. Following this, the child had recurrent respiratory tract infections requiring nebulizations. At 1.5 year of age, the child presented with noisy breathing for seven days with increased respiratory work for one day. It was decided to intubate and ventilate the patient. During intubation, the child desaturated. The baby was shifted to Lilavati Hospital for further management. On presentation at Lilavati Hospital, the child had tachycardia and tachypnea with stridor and bilateral basal crepitations with subcostal, intercostal retractions. CT scan of the neck and chest showed 9×1×5 mm narrowing below the vocal cords.

During the intubation procedure, the child went into desaturation due to severe bronchospasm, so emergency tracheostomy was done. After the tracheostomy, a bronchoscopy was attempted. This revealed splayed arytenoids and edematous vocal cords and trap door (fish mouth) appearance, with sub-glottic narrowing 6 mm in length, 1.5 cm below the vocal cords. On repeat bronchoscopy, we also found a SGC on the right side,

and the cyst was aspirated. After that, deroofing of the cyst was done using a CO₂ laser with a microlaryngoscope. After two weeks, bronchoscopy showed a raw area at the operated site with mild vocal cord edema. After a few days, a 3.5 Fr. tracheostomy tube was changed to 3 Fr. Later decannulation of the tracheostomy tube was done, and the baby is doing well.

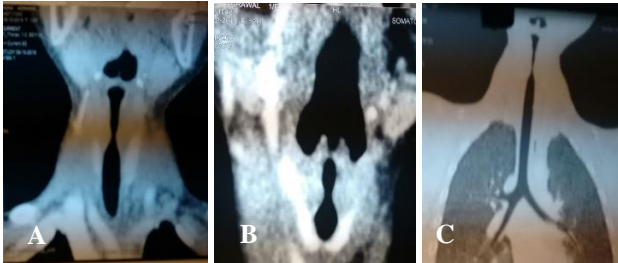


Figure 1 (A-C): CT scan of neck and chest shows narrowing below the vocal cords for about 1 cm in length.

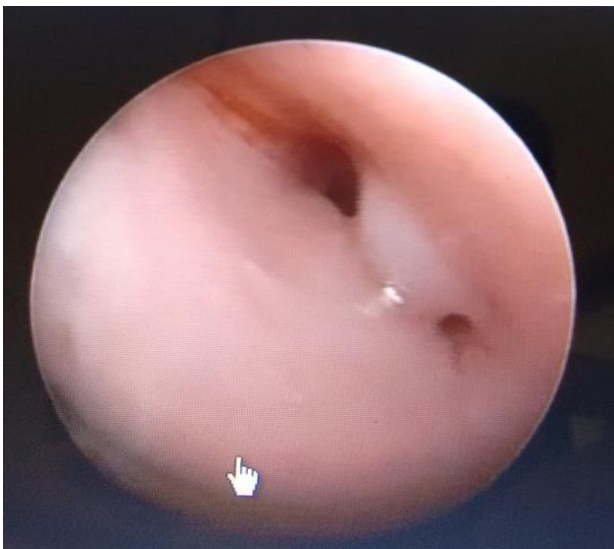

Figure 2: Pre-operative bronchoscopy: a sub-glottic-cyst was seen.

Case 2

Preterm (26.4 weeks of gestation) with extremely low birth weight (800 gm), delivered through lower segment caesarean section, because of leaking PV. The baby required a ventilator for eight days. Then kept on continuous positive airway pressure and weaned off completely by at 2 months. The baby was kept in neonatal intensive care unit for 69 days. The baby was well until seven months of age. The baby had an intermittent cough and post-tussive vomiting treated as gastro-esophageal reflux (GER) with ranitidine and metoclopramide. At eight months, the baby had noisy breathing, tachypnea, and mechanically ventilated. Bronchoscopy was done, which showed multiple cystic lesions below the vocal cords. So, to decrease edema of the airway, the baby was kept on adrenaline and budocort

nebulization. After ten days, the child was admitted with tachypnea and decreased activity. Computed tomography scan of the airway showed multiple tiny 3 to 4 mm size nodular soft tissue in the sub-glottic region 5 to 6 mm from the vocal cords causing significant narrowing of the sub-glottic airway measuring approximately 8 to 9 mm in length. Tracheostomy was done to relieve obstruction and planned for deroofing of the SGCs after one month. Microlaryngoscopic CO₂ laser was used for the ablation of cysts. One cyst was very deep, 2 cm below the glottis, planned for second stage deroofing. Check bronchoscopy was done; fortunately, the size of the previous cyst had decreased. There was a granuloma above the tracheostomy site, which was removed partially with optical forceps. Airway sized from 2.5 to 4 no endotracheal tube. The child had no respiratory distress and cyanosis while blocking of the tube by speaking valve. Check bronchoscopy was done at 14 months of age before the removal of the tracheostomy tube. Currently, the child is doing well.

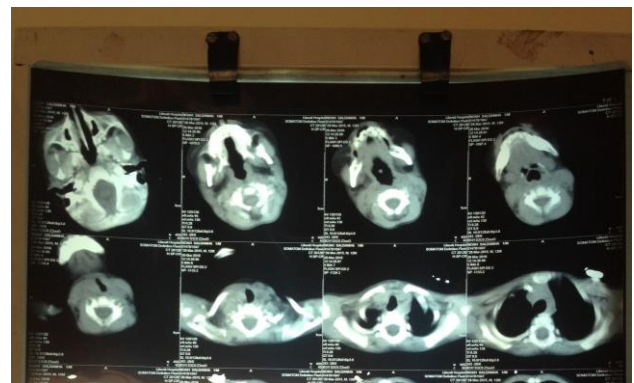


Figure 3: CT scan of neck and chest showing narrowing below the vocal cords.

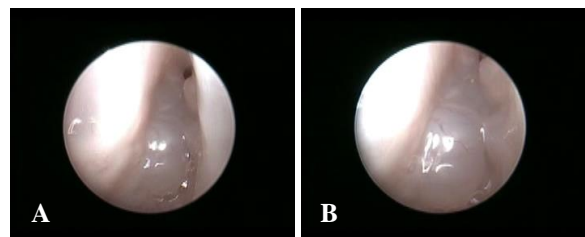


Figure 4 (A and B): Pre-operative bronchoscopy: multiple sub-glottic- cysts were seen.

DISCUSSION

SGC are a relatively rare, non-malignant cause of airway obstruction. They are seen in premature babies with neonatal intubation. In our study, both the babies were preterm required neonatal intubation. Stridor following weeks or months of prolonged endotracheal intubation is due to fibrotic narrowing of the sub-glottic lumen, and subglottic stenosis is well recognized. Both the patients presented with stridor after few months (7 to 8 months) of intubation. It is surprising to know that SGCs arise even

with standard endotracheal tube size for the age of the child and traumatic intubation for less than 24 hours. The cyst formation does not depend on the duration of the intubation and size of the endotracheal tube. Cyst formation results from obstruction of native mucous glands due to subepithelial fibrosis and squamous metaplasia in the healing process⁵ of the traumatic intubation. It is difficult to establish the diagnosis of a SGC as the symptom's mimic features of lower respiratory tract infections and GERD. Early identification of the cysts with flexible bronchoscopy is important since airway compromise may progress, and surgical intervention may be life-saving. They can be managed conservatively or with marsupialization by forceps, CO₂ laser, micro laryngeal debrider.^{2,4} Both the babies were managed with microlaryngoscopic CO₂ laser. Cysts were lysed with the edge of the rigid bronchoscope as the bronchoscope entered or passed through the subglottis. Treatment of the cysts will relieve respiratory distress allowing successful extubation or decannulation of a tracheostomy. As there is a 12.5% to 70% chance of recurrence(s) of cysts after initial treatment, so follow up for a minimum of 6 months is required.^{4,6} Follow up bronchoscopies were normal in both the patients.

Halimi et al studied acquired SGCs and their management.⁷ They reported that among 17 children, 98% were premature and all patients were intubated during the neonatal period, for a mean duration of 14 days.

Johnson et al studied acquired SGCs in preterm and reported eleven patients were diagnosed with SGC by microlaryngoscopy and bronchoscopy.⁸ All of them had a history of prematurity with intubation in the perinatal period.

CONCLUSION

Preterm babies who were intubated for a long time are at risk of the development of subglottic cysts and stenosis. These cysts are diagnosed by bronchoscopy and can either be managed endoscopically, if mild and diagnosed

early, or may require surgical procedures to correct the associated subglottic stenosis.

Funding: No funding sources

Conflict of interest: None declared

Ethical approval: Not required

REFERENCES

1. Downing GJ, Hayen LK, Kilbride HW. Acquired subglottic cysts in the low birth-weight infant. Characteristics, treatment, and outcome. *Am. J. Dis. Child.* 1993;147:971-4.
2. Lim J, Hellier W, Harcourt J, Leighton S, Albert D. Subglottic cysts: the Great Ormond Street experience. *Int J Pediatr Otorhinolaryngol.* 2003;67:461-5.
3. Agada FO, Bell J, Knight L. Subglottic cysts in children: a 10-year review. *Int. J. Pediatr. Otorhinolaryngol.* 2006;70:1485-8.
4. Watson GJ, Malik TH, Khan NA, Sheehan PZ, Rothera MP. Acquired pediatric subglottic cysts: a series from Manchester. *Int J Pediatr Otorhinolaryngol.* 2007;71:533-8.
5. Couriel JM, Phelan PD. Subglottic cysts: a complication of neonatal endotracheal intubation? *Pediatrics.* 1981;68:103-5.
6. Ransom ER, Antunes MB, Smith LP, Jacobs IN. Microdebrider resection of acquired subglottic cysts: case series and review of the literature. *Int J Pediatr Otorhinolaryngol.* 2009;73:1833-6.
7. Caroline Halimi, Jerome Nevoux, Françoise Denoyelle, Erea-Noel Garabedian. Acquired subglottic cysts: Management and long-term outcome: *Int J Pediatr Otorhinolaryngol.* 2012;76:589-92
8. Johnson LB, Rutter MJ, Shott SR, Cotton RT. Acquired subglottic cysts in preterm infants. *J. Otolaryngol.* 2005;34:75-8.

Cite this article as: Chigicherla S, Tewari S, Sharma RD, Nathani R. Sub-glottic cyst causing upper airway obstruction. *Int J Otorhinolaryngol Head Neck Surg* 2020;6:1203-5.