

Original Research Article

Profile of parotid tumors visiting tertiary health care facility in North India

Manish Munjal^{1*}, Nitika Tuli¹, Porshia Rishi¹, Harjinder Singh¹, Shivam Talwar¹,
Salony Sharma¹, Shubham Munjal²

¹Department of ENT, ²Department of Anatomy, Dayanand Medical College Ludhiana, Punjab, India

Received: 26 February 2020

Revised: 09 April 2020

Accepted: 10 April 2020

***Correspondence:**

Dr. Manish Munjal,

E-mail: manishmunjaldr@yahoo.com

Copyright: © the author(s), publisher and licensee Medip Academy. This is an open-access article distributed under the terms of the Creative Commons Attribution Non-Commercial License, which permits unrestricted non-commercial use, distribution, and reproduction in any medium, provided the original work is properly cited.

ABSTRACT

Background: Neoplastic lesions of head and neck presenting in a tertiary care facility were analyzed. This study is proposed to examine the epidemiological pattern of parotid tumors, histopathology correlations and relation of facial nerve with the parotid tumors.

Methods: This is a retrospective study of patients with head and neck neoplasms who presented to the ENT tumour clinic of Dayanand Medical College and Hospital over a period of 2 years i.e., from January 2018 to December 2019. Patients' demographic profile, histopathological reports and pre-operative fine needle aspiration cytology reports were studied.

Results: Total number of cases of head and neck neoplasms were 273 over a period of 2 years. Parotid tumours constituted 9.1% of the total head and neck neoplasm. Predominant age group in case of benign parotid tumors was 40-50 years, whereas in case of malignant neoplasms was 50-60 years. Posterior belly of digastric along with tragal pointer are the most consistent and reliable landmarks for Identification of facial nerve.

Conclusions: Identification of trunk of facial nerve using anatomical landmarks is the keystone for parotid surgery. Posterior belly of digastric along with tragal pointer are the most consistent and reliable landmarks for Identification of facial nerve.

Keywords: Head and neck neoplasm, Parotid, Facial nerve

INTRODUCTION

Salivary gland tumors are rare and most cases are referred to the head and neck clinics. Neoplasia of the parotid is the commonest amongst the salivary gland with 20 % being malignant and 80% benign.¹ There is female preponderance in all tumors with exception of Warthin which is more common in males. The anatomical relation of tumor with the facial nerve (or its branches) in parotid is nearly always intimate. Knowledge of the anatomical relation of parotid gland with facial nerve can help in improving the outcome of parotid surgeries.

This study proposed to examine the epidemiological pattern of salivary gland tumors, histopathology correlations and relation of facial nerve with the parotid tumors

Anatomical landmarks which facilitate identification of facial nerve during superficial parotidectomy.² Inferior portion of cartilaginous EAC (tragal pointer) facial nerve lies 1cm inferior and deep to it. Tympanomastoid suture - facial nerve lies immediately deep and inferior to this at its point of exit from the skull. Anterior border of posterior belly of digastric-facial nerve leaves the skull immediately anterior to attachment of this muscle.

Styloid process-lies deep to exit of facial nerve from the skull.

Objective

Study of incidence and demographic profile of parotid tumors in north Indian population and histopathological correlation of parotid tumors with fine needle aspiration cytology (FNAC) reporting. Markers used for facial nerve identification in parotid surgery.

METHODS

This is two years (January 2018 to December 2019) retrospective study of all salivary gland tumor biopsies received at our head and neck clinic, tertiary health care center, Ludhiana. Biodata (age, sex, histopathological examination (HPE) report) was taken from histopathology report of excised tumors. All specimen was fixed in 10% formalin and then processed into paraffin embedded sections and stained with hematoxylin and eosin special stains were used occasionally.

Inclusion criteria

Patients presenting with parotid swelling confirmed as parotid pathology (both benign and malignant) on fine need aspiration cytology exclusion criteria. Patients amenable with medical therapy.

Intraoperative facial nerve anatomy and its relation to parotid gland was studied. 273 cases presented in our head and neck clinic with complaint of swelling in parotid area out of these 25 patients (9.1%) presented with parotid swelling. Preoperative FNAC was done in all patients (including USG guided). Postoperatively all specimen were sent for HPE.

All statistical calculations were done using statistical package of social sciences (SPSS) 17 version statistical program for microsoft windows (SPSS Inc. released 2008. SPSS statistic for windows, version 17.0, Chicago). Ethical approval of the study was taken from the Institutional Ethics Committee.

RESULTS

Incidence of parotid tumors is more common in 14 females (56%) as compared to 11 males (44%). Predominant age group in case of benign parotid tumors was 40-50 years, whereas in case of malignant neoplasms was 50-60 years.

Benign lesions included pleomorphic adenoma and warthin tumor. Malignant lesions included adenoid cystic, mucoepidermoid, acinic cell carcinomas and miscellaneous (e.g., lymphoma).

Among benign lesions male female ratio was 2:3, whereas it was 1:1 in malignant lesions. Peak incidence

was noted in age group 40-60 years with benign lesions being most common in age group of 40-50 years, and malignant being most common in age group of 50-60 years.

Pleomorphic adenoma (12 cases) showed the highest incidence of 48%, followed by mucoepidermoid carcinoma (3 cases) with incidence of 12%.

Table 1: Parotid neoplasms constituted 9% of total head and neck neoplasms.

Variables	Number of patients
Head and neck tumors	273
Parotid neoplasms	25 (9.1%)

Table 2: Gender preponderance.

Type of tumors	Males	Females	Ratio
Benign	6	9	2:3
Malignant	5	5	1:1

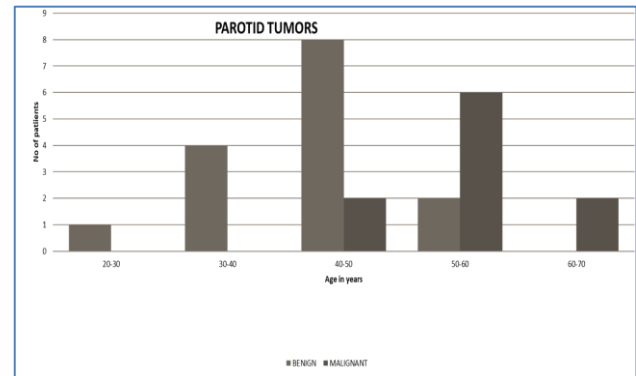


Figure 1: Age distribution of parotid neoplasms (both benign and malignant).

Table 3: Number of patients with types of neoplasms, pleomorphic adenoma showing highest incidence.

S. no.	Type of neoplasm (based on HPE)	No. of patients
1	Pleomorphic adenoma	12
2	Warthins tumor	3
3	Adenoid cystic carcinoma	2
4	Mucpepidermoid carcinoma	3
5	Acinic cell carcinoma	1
6	Miscellaneous (HL and NHL)	4

Two patients among 25, showed absence of FNAC and HPE correlation. Both patients were females which were reported as benign pathology on FNAC which was finally reported as mucoepidermoid carcinoma and adenoid cystic carcinoma on HPE.

Posterior belly of digastric along with tragal pointer were found out to be the most reliable marker for identifying the facial nerve trunk intraoperatively (Figure 2),

intraoperative relation of main facial trunk with cartilaginous pointer (shown by black line in Figure 2a). Figure 2b, shows facial nerve lying 1cm inferior to cartilaginous pointer.

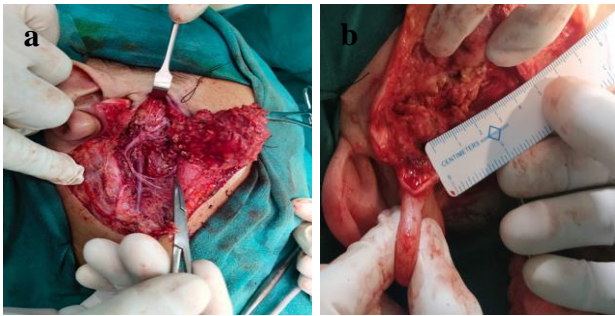


Figure 2 (a and b): Relation of facial nerve trunk with tragal pointer.

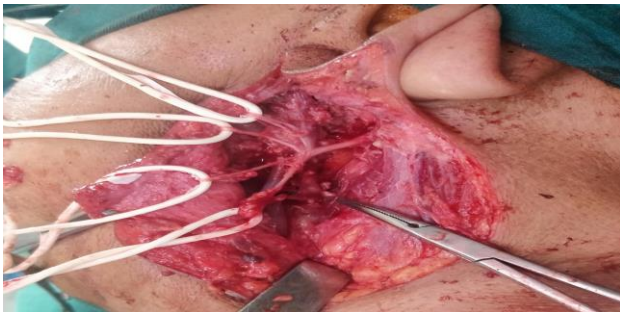


Figure 3: Deep lobe of parotid being taken out retracting the branches of facial nerve.

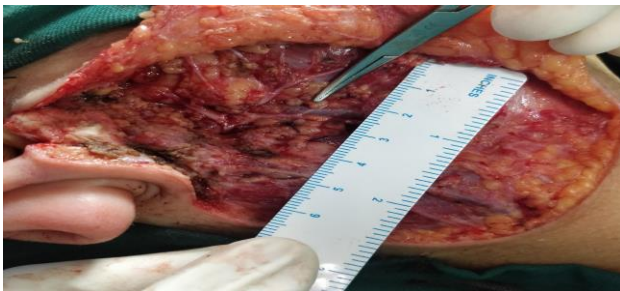


Figure 4: Relation of facial nerve with anterior border of posterior belly of digastric (shown by black line).

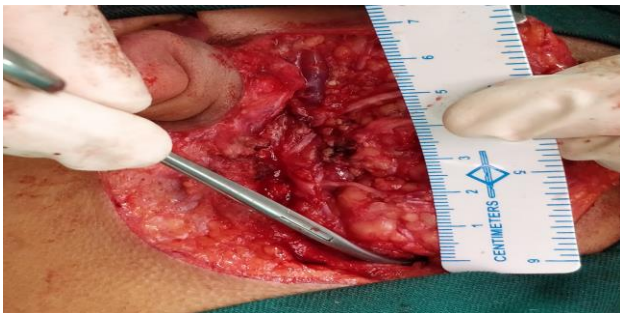

Figure 5: Rami mandibularis, 1 cm above the angle of mandible (shown by arrow).

DISCUSSION

In our study incidence of parotid tumours in head and neck clinic was found to be 9.1% (25/273 cases). Female patients outnumbered the male patients with ratio being 1.26:1 this was in consistence with study by Srinivas et al (2019).³ Mean age was noted to be 49.3 years, with benign tumours being most common in 4th decade and malignant lesions occurring mostly in 5th decade which matches the results of studies of Eveson (1985) and study by Fito et al (2005).^{4,5} Majority of tumours (60%) were found to be benign and 40% were found to be malignant with ratio being 3:2, which is in concordance with study done by Takahama et al (July-August 2009).⁶ We found that females predominated in benign tumours (60%) which is similar to study done by Takahama et al.⁶ In contrast to most studies which show that males predominated in malignant lesions our study shows that male female ratio was 1:1 in cases of malignant tumours. Pleomorphic adenoma was most common among benign tumours (48%) followed by Warthin tumour.

Our study showed FNAC and HPE correlation in 23 patients in 2 patients FNAC was suggestive of benign lesions but one of them came out to be a Warthin's tumour, and second was diagnosed as mucoepidermoid carcinoma on histopathology. Both of these patients were female, thus FNAC showed PPV of 92% which is similar to study done by Arul et al (June 2015).⁸

Table 5: Comparison between studies done.

Variables	Takahama et al ⁶	Sardar et al ⁷	Our study (2020)
Predominant age group (yrs)	60-70	60-70	50-60
Gender	F>M	F>M	F>M
Benign tumors (%)	44.8	49.3	60
Malignant tumors (%)	55.2	50.7	40
FNAC and HPE relation	Yes	Yes	Absent in two patients

CONCLUSION

Benign lesions are more common than the malignant and pleomorphic adenoma being the commonest. Mucoepidermoid carcinoma was most common among the malignant. Posterior belly of digastric along with tragal pointer are the most consistent and reliable landmarks for Identification of facial nerve.

Funding: No funding sources

Conflict of interest: None declared

Ethical approval: The study was approved by the Institutional Ethics Committee

REFERENCES

1. Eneroth CM. Salivary gland tumors in the parotid gland, submandibular gland, and the palate region. *Cancer.* 1971;27(6):1415-8.
2. Saha S, Pal S, Sengupta M, Chowdhury K, Saha VP, Mondal L. Identification of facial nerve during parotidectomy: a combined anatomical and surgical study. *Indian J Otolaryngol Head Neck Surg.* 2014;66(1):63-8.
3. Venkatesh S et al. Parotid Gland Tumors: 2 years Prospective Clinicopathological Study. *Annals Maxillofacial Surg.* 2019;9(1):103-9.
4. Eveson JW, Cawson RA. Salivary gland tumours. A review of 2410 cases with particular reference to histological types, site, age and sex distribution. *J Pathol.* 1985;146:51-8.
5. Ito FA, Ito K, Vargas PA, Almeida DOP, Lopes MA. Salivary gland tumors in a Brazilian population: a retrospective study of 496 cases. *Int J Oral Maxillofacial Surg.* 2005;34(5):533-6.
6. Junior TAL, Almeida OP, Kowalski LP. Parotid neoplasms: analysis of 600 patients attended at a single institution; 2009.
7. Sardar MA, Ganvir SM, Hazarey VK. A demographic study of salivary gland tumors. *SRM J Res Dent Sci.* 2018;9:67-73.
8. PA, CA, Masilamani S, Jonathan S. Diagnosis of Salivary Gland Lesions by Fine Needle Aspiration Cytology and Its Histopathological Correlation in A Tertiary Care Center of Southern India. *J Clin Diagn Res.* 2015;9(6):7-10.

Cite this article as: Munjal M, Tuli N, Rishi P, Singh H, Talwar S, Sharma S, et al. Profile of parotid tumors visiting tertiary health care facility in North India. *Int J Otorhinolaryngol Head Neck Surg* 2020;6:835-8.