

Case Report

Acinic cell carcinoma of ascending ramus mandible: a rare case report

Manish Munjal^{1*}, Porshia Rishi¹, Nitika Tuli¹, Harjinder Singh¹, Shivam Talwar¹,
Salony Sharma¹, Shubham Munjal²

¹Department of ENT, ²Department of Anatomy, Dayanand Medical College Ludhiana, Punjab, India

Received: 25 February 2020

Revised: 09 April 2020

Accepted: 10 April 2020

*Correspondence:

Dr. Manish Munjal,

E-mail: manishmunjaldr@yahoo.com

Copyright: © the author(s), publisher and licensee Medip Academy. This is an open-access article distributed under the terms of the Creative Commons Attribution Non-Commercial License, which permits unrestricted non-commercial use, distribution, and reproduction in any medium, provided the original work is properly cited.

ABSTRACT

Acini cell carcinoma are low grade tumors of the salivary glands with a rare occurrence in the axial or appendicular skeleton. The parotid, submandibular and the minor salivary glands are sites of involvement in that order. Painless swelling is the usual presentation with a lytic appearance on radiology and imaging, CT or MRI, FNAC can to some extent differentiate between a benign or malignant lesion thereby dictating the likely extent of excision. On histopathological examination of resected specimens, acinic cell carcinoma shows tumor cells arranged as papillary clusters, acinar pattern and dispersed population with individual tumor cells displaying moderate nuclear pleomorphism, anisonucleosis, round nuclei and moderate amount of ill-defined granular cytoplasm. A unique intraosseous presentation of acinic cell carcinoma, in an elderly male, necessitated a segmental partial mandibulectomy and a comprehensive neck dissection. The tumour area was widely excised from the second premolar region to the coronoid process, and radical neck dissection was performed.

Keywords: Acinar cell carcinoma, Mandible, Salivary gland cancer

INTRODUCTION

Nasse in 1892 described for the first time an uncommon low-grade malignant tumor i.e., acinic cell carcinoma of salivary glands.¹ This acinic cell carcinoma is an unusual, low-grade, malignant salivary gland tumor with approximately almost 90% arising in the parotid gland central ACC of the jaw is an extremely rare neoplasm and exhaustive literature review could reveal only 8 such cases.¹

CASE REPORT

A 77 years elderly male presented in the otorhinolaryngology outpatient clinic of Dayanand Medical College and Hospital with an oval swelling on the cheek on the right side of 5 months duration (Figure 1).

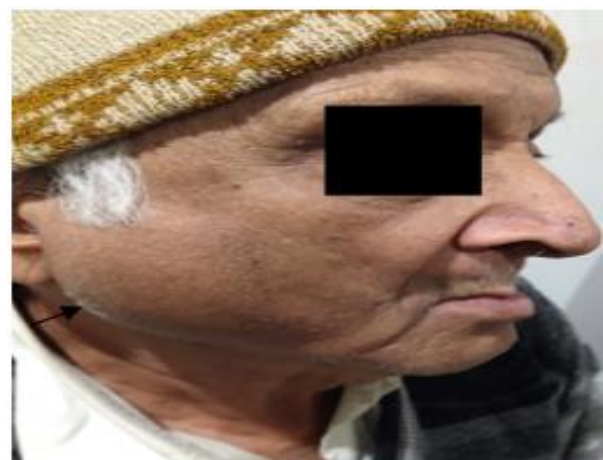

Figure 1: Arrow showing the swelling over ascending ramus of mandible.

The swelling was localized to the region of the ascending ramus of the mandible about 3x2 cm in size and was soft on palpation. The overlying skin on the extrinsic and the buccal mucosa on intrinsic examination was freely mobile. There was no accompanying trismus. The neck was clinically negative for any neck nodes. Patient's medical history was unremarkable. There was no history of any substance abuse or addictions.

The computed tomography was reported as a lytic expansile lesion involving the body and ramus of the right mandible with a large associated soft tissue component. Thin bony fragments seen at the periphery of the soft tissue. The right parotid gland was separate from the lesion (Figure 2 a and b).

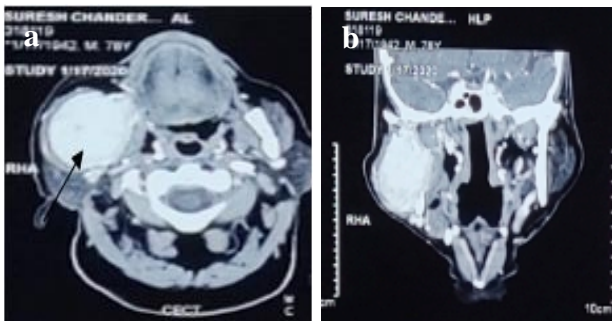


Figure 2: (a) Axial CT section showing expansile lesion at the ramus of mandible right side and (b) coronal CT section showing expansile lesion at the ramus of mandible right side.

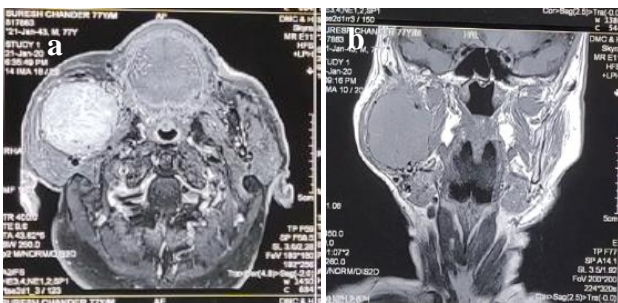


Figure 3: (a) Axial MRI with contrast section showing expansile lesion at the ramus of mandible right side and (b) coronal MRI with contrast section showing expansile lesion at the ramus of mandible right side.

Magnetic resonance imaging with contrast reported a large well defined lobulated lesion appearing hypointense on t_2 weighted imaging seen in the masseteric space extending into infratemporal fossa measuring 7.1 x 4.4 x 4 cm in size, showing diffusion restriction with destruction of the ramus of the mandible, altered signal intensity appearing hypointense on t_1 and showing post contrast enhancement involving body of mandible on right side. Masseter muscle was displaced laterally by the lesion and right parotid gland was separate from the lesion and was compressed by the mass (Figure 3a and b).

Fine needle aspiration of the swelling reported as malignant aspirate - category vi - possibly acinic cell carcinoma (Milan system of reporting). The smear showed tumor cells arranged as papillary clusters, acinar pattern and dispersed population with individual tumor cells displaying moderate nuclear pleomorphism, anisonucleosis, round nuclei and moderate amount of ill-defined granular cytoplasm.

He was taken up for comprehensive neck dissection with clearance of level I to level v lymph nodes. The ascending ramus of the mandible beyond the first premolar was found to be eroded by the tumour and removed, along with the coronoid process.

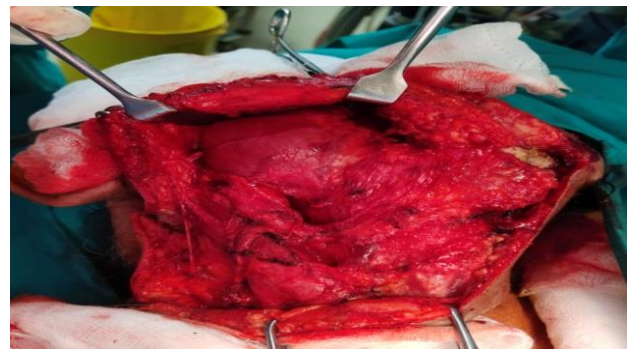


Figure 4: Tumour over the ascending ramus of mandible.

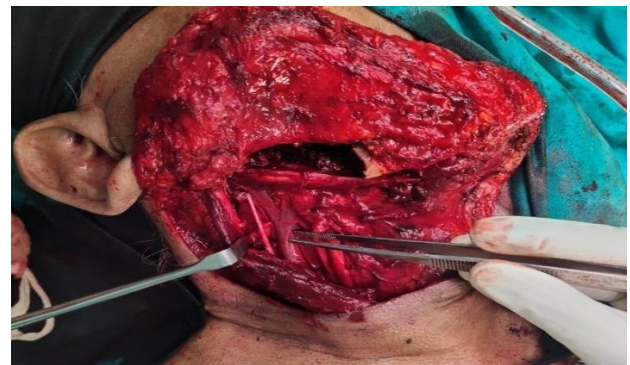

Figure 5: Defect created after removal of tumour and ascending ramus of mandible and neck dissection.

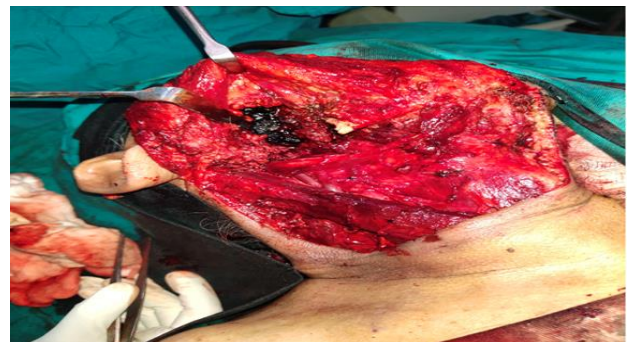


Figure 6: Infratemporal fossa.

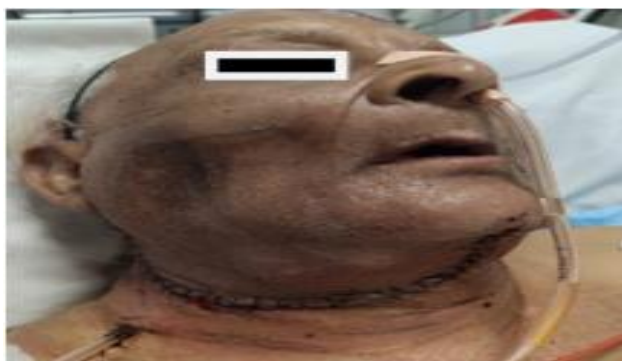

Figure 7: Post-operative suture line of the patient.

Haemostasis was achieved by ligating the inferior alveolar artery and bipolar diathermy of the pterygoid venous plexus of infratemporal fossa (Figure 5).

The buccal mucosa and buccinator were not breached. The defect so created was left as such and wound sutured over an indwelling drain.

DISCUSSION

2% of the salivary gland tumors arise from the acinic cells. This Acinic cell carcinoma is an unusual, low-grade, malignant salivary gland tumor with approximately almost 90% arising in the parotid gland. The rest involve the submandibular and the minor salivary gland.¹

Acinic cell carcinoma was first described by Godwin et al in 1954.² Origin of this entity primarily in maxillofacial bony skeleton is rare. This Acinic cell carcinoma has been seen in the mandible more as compared to other sites. Mandibular intraosseous presentation of acinic cell salivary gland carcinoma has an incidence of about 75% with a peak age in the 5th and 6th decade of life Though all age groups may be affected.³

Local complaints of pain and swelling of the involved area is usually the presenting symptom. The present case was a 77 years old male with a swelling on the cheek minus any pain for which he underwent partial mandibulectomy and a comprehensive neck dissection.

Acinic cell carcinoma in the mandible has female predilection as reported by Hiremath et al, Nakazawa et al.^{4,5} Hence our finding in the 77 years old male is rare. Barnes et al described two theories for the central salivary gland neoplasms; one suggests a neoplastic transformation in developmentally entrapped salivary

gland tissue in the bone and the other suggests a metaplasia of epithelial lining of an odontogenic cyst.⁶ The present case belonged to the first category.

Surgery is the treatment of choice for central acinic cell carcinoma and postoperative radiotherapy may be useful for recurrent, undifferentiated cases of acinic cell carcinoma, positive margins and advanced tumours with cervical node spread the present case was treated surgically.⁷

Funding: No funding sources

Conflict of interest: None declared

Ethical approval: Not required

REFERENCES

1. Bajpai, Manas. Central Acinic Cell Carcinoma of the Mandible Simulating as Benign Odontogenic Lesion: A Case Report. Iranian J Med Sci. 2018;43(2):223.
2. Godwin JT, Foote FW, Frazell EL. Acinic cell adenocarcinoma of the parotid gland: report of 3 cases and literature review. Revista portuguesa de estomatologia, medicinadentaria e cirurgia Maxillofacial. 2010;51:5-11.
3. Hara I, Ozeki S, Okamura K, Toshitani K, Taniguchi K, Honda T, et al. Central acinic cell carcinoma of the mandible, Case report. J Craniomaxillo Fac Surg. 2003;31:378-82.
4. Hiremath V, Mishra N, Patil SG. Intraosseous acinic cell carcinoma. Niger J Clin Pract. 2013;16:386.
5. Nakazawa M, Ohnishi T, Iwai S, Sakuda M. Central acinic cell carcinoma of the mandible. Report of a case. Int J Oral Maxillofac Surg. 1998;27:448-50.
6. Barnes L, Eveson JW, Reichart P, Sidransky D. World Health Organization Classification of Tumours: Pathology and Genetics of Head and Neck Tumours. Lyon: IARC Press; 2005.
7. Oliveira LR, Soave DF, Costa JPO, Silva RA. Acinic cell carcinoma of parotid gland: Report of three cases and literature review. Revista Portuguesa de Estomatologia, Medicina Dentaria e Cirurgia Maxilofacial. 2010;51:5-11.

Cite this article as: Munjal M, Rishi P, Tuli N, Singh H, Talwar S, Sharma S, et al. Acinic cell carcinoma of ascending ramus mandible: a rare case report. Int J Otorhinolaryngol Head Neck Surg 2020;6:1013-5.