

Original Research Article

Dacrocystography: a pre requisite to endoscopic dacrocystorhinostomy

Manish Munjal^{1*}, Amanjot Kaur¹, G. S. Bajwa², Hitant Vohra³,
Akashdeep Sohi⁴, Shubham Munjal³

¹Department of ENT, ²Department of Eye, ³Department of Anatomy, ⁴Department of Surgery, Dayanand Medical College, Ludhiana, Punjab, India

Received: 20 February 2020

Revised: 18 March 2020

Accepted: 19 March 2020

***Correspondence:**

Dr. Manish Munjal,

E-mail: manishmunjaldr@yahoo.com

Copyright: © the author(s), publisher and licensee Medip Academy. This is an open-access article distributed under the terms of the Creative Commons Attribution Non-Commercial License, which permits unrestricted non-commercial use, distribution, and reproduction in any medium, provided the original work is properly cited.

ABSTRACT

Background: Dacryocystography is a simple radiological procedure in which a radiographic water-soluble dye like iohexal or neohydriol is injected into the lacrimal system and free flow of dye is noted from the eyes into the nose and any restriction in the flow of indicates obstruction and site of the same.

Methods: This is a prospective study of role of dacryocystography in 31 cases of dacryocystitis who presented to the ENT outpatient clinic of Dayanand Medical College and Hospital over a period of 1.5 years i.e. from June 2016 to December 2017 who were planned for dacrocystorhinostomy. Patient was placed in dorsal decubitus position and local anaesthesia was administered. No. 15 catheter was connected to a syringe containing contrast medium and its ends are introduced into both lacrimal puncta. Head of the patient is fixed and the contrast medium was administered through both the puncta simultaneously and serial radiographs were obtained

Results: The role of dye study, prior to endoscopic dacrocystorhinostomy dacrocystography was studied in 31 subjects. Of the 22 subjects who underwent surgical intervention, 18 (81.8%) had a complete obstruction while 4 (18.2%) had a partial block.

Conclusions: Dacryocystography is a useful and cost-effective investigation to delineate the obstruction in the nasolacrimal system. It aids in confirmation of clinical diagnosis as well as making a diagnosis in doubtful cases.

Keywords: Dacrocystography, Dacryocystitis, Obstruction

INTRODUCTION

Epiphora has been a major concern for ophthalmologists since long. Many investigations were developed to investigate a patient with epiphora. The introduction of Jones dye tests made it possible to determine the precise cause of excessive watering from the eyes.¹ Syringing and probing were used to locate the site of obstruction as well as used therapeutically in children with nasolacrimal duct obstruction.²⁻⁵ The procedure is effective in the cases of membranous obstruction but with poor results in hard obstruction.⁶ However the success rate of syringing and probing decreases with increasing age.

Dacryocystography is helpful to diagnose functional as well as mechanical obstruction.⁷ It is a simple radiological procedure in which a radiographic water soluble dye like iohexal or neohydriol is injected into the lacrimal system and free flow of dye is noted from the eyes into the nose and any restriction in the flow of indicates obstruction and site of the same. It is a relatively inexpensive investigation which is easy to perform and it helps to locate the site of obstruction the aim of this study is to study the role of dacryocystography in patients with dacryocystitis undergoing endoscopic dacrocystorhinostomy.

METHODS

Dacryocystography was studied in 31 cases of dacryocystitis at a ENT outpatient clinic of Dayanand Medical College and Hospital over a period of 1.5 years ie from June 2016 to December 2017. The inclusion criteria included patients with significant nasolacrimal duct obstruction presenting as epiphora who underwent endoscopic dacryocystorhinostomy.

Procedure

Patient was placed in dorsal decubitus position and local anaesthesia was administered. No. 15 catheter was connected to a syringe containing contrast medium and its ends are introduced into both lacrimal puncta. Head of the patient is fixed and the contrast medium was administered through both the puncta simultaneously and serial radiographs were obtained.

The statistical analysis of the results of the study was described in terms of range, mean, frequencies (no of cases) and relative frequencies (%) as appropriate. All statistical analysis was performed using Microsoft Excel and Statistical Package of Social Sciences (SPSS) version 17 for Microsoft Windows (SPSS Inc. Released 2008. SPSS Statistic for windows, version 17.0, Chicago).

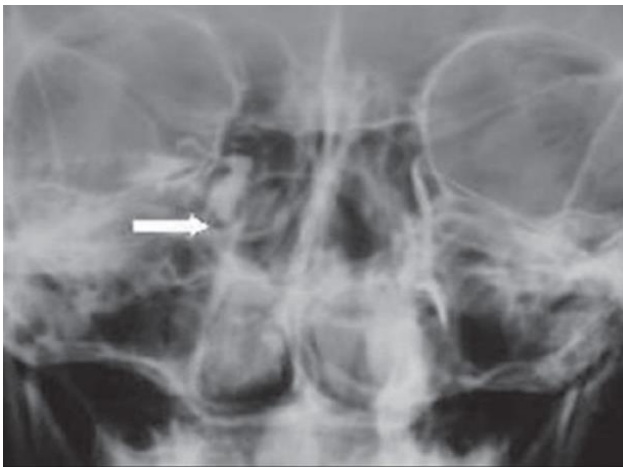


Figure 1: Conventional dacryocystogram showing obstruction at the level of right valve of Krause.

RESULTS

Dacryocystography was performed in 22 patients (70.96%) in our study.

Table 1: Dacryocystography (n=31).

Dacryocystography	No. of patients	% of patients
Done	22	70.96
Not done	9	29.03
Total no. of patients	31	100

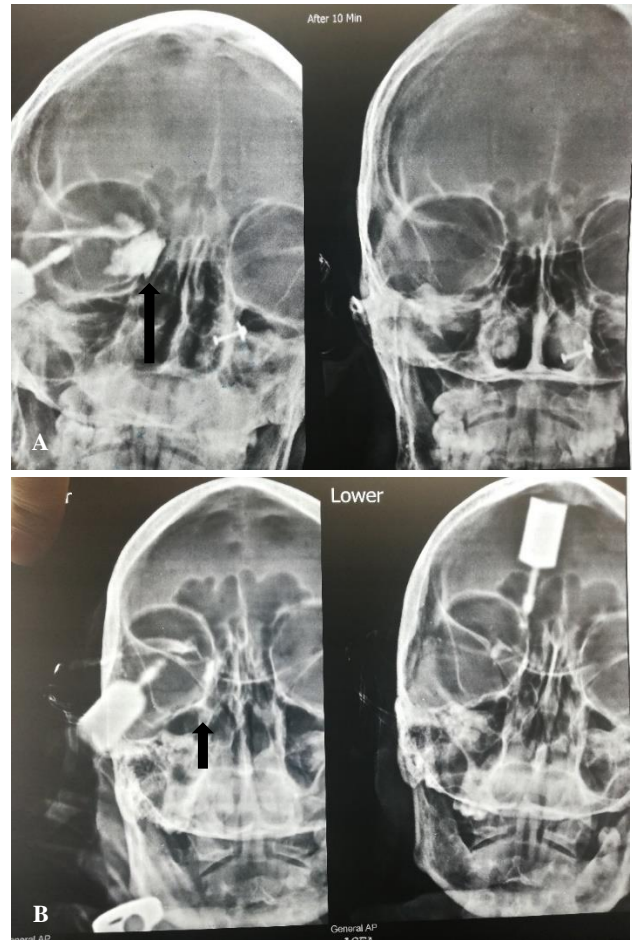

Figure 2 (A and B): Dacryocystographs (arrow marking the level of obstruction).

Table 2: Dacryocystography findings (n=22).

Dacryocystography findings	No. of patients	% of patients
Complete obstruction	18	81.8
Partial obstruction	4	18.2
Total number of patients	22	100

In 18 patients (81.8%) there was complete obstruction and in 4 patients (18.2%) there was partial obstruction. Most of the obstructions were at the level of valve of Krause.

DISCUSSION

Endonasal dacryocystorhinostomy is a highly rewarding procedure for the management of chronic dacryocystitis when the epiphora does not respond to repeated syringing or medical management. It is a simple and less time consuming surgery. Dacryocystography is a relatively inexpensive investigation which is easy to perform and it helps to locate the site of obstruction upto some extent. Functional obstruction was diagnosed with

dacryocystography if there was residual contrast in the lacrimal sac or nasolacrimal duct in the delayed radiographs

In this study dacryocystography was performed in 22 patients (70.96%) and in 3 patients dacryocystography was not undertaken because CT scan was done in them to get additional information about the neighbouring structures. In the rest of the 6 patients, dacryocystography was not undertaken due to financial constraints.

In 18 patients (81.8%) there was complete obstruction and in 4 patients (18.2%) there was partial obstruction. Most of the obstructions were at the level of valve of Krause.

Wearne et al examined 45 lacrimal systems with nasolacrimal duct obstruction by using dacryoscintigraphy and dacryocystography and concluded that the combination of both the investigations give the highest sensitivity with maximum anatomical and physiological information. However, it is reasonable to perform dacryocystogram initially and proceed with dacryoscintigraph later.⁷

Siddiqui et al performed dacryocystography in 131 eyes with chronic dacryocystitis and found that on dacryocystography complete block was present in 78.8% cases and partial block was present in 21.2% cases.⁸ Valve of Krause was blocked in 60.30% cases and Valve of Hasner was blocked in 22.90%. common canalicular obstruction was present in 16.79% cases.

In our study computed tomography (CT) was undertaken in 3 patients to know the status of the surrounding structures as there was history of facial trauma and nasal surgery in these cases.

However, no significant alteration due to above pathologies was noted in the nasolacrimal system in these cases and hence dacryocystorhinostomy was performed in these patients. CT scan is also useful to delineate any intrinsic pathology of the nasolacrimal system like any solid or cystic mass which could affect the treatment protocol. Performing CT scan before giving lacrimal contrast is also useful to delineate calcifications such as dacryoliths.

Udhay et al performed CT dacryocystography in 13 patients and were able to observe mass lesion in 5 cases, nasolacrimal duct obstruction in 6 cases and mucocele in 2 cases.⁹ Hence mass lesion in performed in 5 cases, dacryocystorhinostomy in 7 cases and primary silicone tube intubation was carried out in 1 case.

We performed dacryocystography in 22 out of 31 patients in our study and noted complete obstruction in 18 patients and incomplete obstruction in 4 patients.

maximum obstructions were at the level of valve of Krause.

CONCLUSION

Dacryocystography is a useful and cost-effective investigation to delineate the obstruction in the nasolacrimal system. It aids in confirmation of clinical diagnosis as well as making a diagnosis in doubtful cases.

Funding: No funding sources

Conflict of interest: None declared

Ethical approval: The study was approved by the Institutional Ethics Committee

REFERENCES

1. Toti A. Nuovo Metodoconservatore dicuraradicaledellesuppura zionecroniche del saccolacrimal (dacricistorhinostomia). *ClinModerna (Firenze)*. 1904;10:385.
2. Cassady JV. Developmental anatomy of the nasolacrimal duct. *Arch Ophthalmol*. 1952;47:141-58.
3. Grossman TH, Putz R. Uber die angeborenetranengangstenose der neugeborenen, ihreanatomie, ihrefolgen und behandlung. *Klin Monatsbl Augenheilkd*. 1972;160:563-74.
4. Schwartz M. Congenital atresia of the naso-lacrimal canal. *Arch Ophthalmol*. 1935;13:301-2.
5. MacEwen CJ, Young JD, Barras CW, Ram B, White PS. Value of nasal endoscopy and probing in the diagnosis and management of children with congenital epiphora. *Br J Ophthalmol*. 2001;85:314-8.
6. Perveen S, Sufi AR, Rashid S, Khan A. Success Rate of Probing for Congenital Nasolacrimal Duct Obstruction at Various Ages. *J Ophthalmic Vis Res*. 2014;9:60-9.
7. Wearne MJ, Pitts J, Frank J, Rose GE. Comparison of dacryocystography and lacrimal scintigraphy in the diagnosis of functional nasolacrimal duct obstruction. *Br J Ophthalmol*. 1999;83:1032-5.
8. Siddiqui DP. Chronic Dacryocystitis - It's Evaluation and Management by Various Investigative and Diagnostic Test. *IOSR Journal of Pharmacy (IOSRPHR)*. 2013;03:28-33
9. Udhay P, Noronha OV, Mohan RE. Helical computed tomographic dacryocystography and its role in the diagnosis and management of lacrimal drainage system blocks and medial canthal masses. *Indian J Ophthalmol*. 2008;56:31-7.

Cite this article as: Munjal M, Kaur A, Bajwa GS, Vohra H, Sohi A, Munjal S. Dacryocystograph: a pre requisite to endoscopic dacryocystorhinostomy. *Int J Otorhinolaryngol Head Neck Surg* 2020;6:661-3.