

Original Research Article

A comparative analysis between intralesional 5-fluorouracil versus surgical excision with intralesional triamcinalone acetone in keloid excision

Vasim Ismail Patel, Ritty Ann Thomas*

Department of Otolaryngology, Navodaya Medical College and Research centre, Raichur, Karnataka, India

Received: 04 February 2020

Revised: 30 March 2020

Accepted: 31 March 2020

*Correspondence:

Dr. Ritty Ann Thomas,

E-mail: annritty@gmail.com

Copyright: © the author(s), publisher and licensee Medip Academy. This is an open-access article distributed under the terms of the Creative Commons Attribution Non-Commercial License, which permits unrestricted non-commercial use, distribution, and reproduction in any medium, provided the original work is properly cited.

ABSTRACT

Background: Keloids are characterized by an uncontrolled proliferation of fibrous tissue after injury of the skin and has been treated by various modalities. Recently, newer therapeutic modalities have been studied including intralesional 5-FU, verapamil, laser therapy, cryotherapy, silicone sheet dressings, irradiation, retinoids, tacrolimus, imiquimod and combination therapy. The aim of this study is to analyse the response of intralesional 5-FU alone with that of intralesional triamcinalone acetone with surgical excision thus to provide the best possible treatment modality to patients.

Methods: Sixteen patients having keloid in head and neck region were taken into the study and divided into two groups after a routine blood check-up. Group A intralesional 5-FU once in three weeks for six sessions. Group B surgical excision followed by intralesional triamcinalone acetone once weekly for six sessions. Patients were followed up for one year.

Results: In group A, 7 patients came for review regularly. Aesthetic improvement was excellent for 6 but was considerably painful for all. In group B, 8 patients came for regular review, 6 had minimal scarring and all patients complained of mild pain post operatively.

Conclusions: Intralesional 5-FU can be a very effective treatment modality for keloids, with no recurrence noted, except for its poor tolerability owing to side effects such as pain, nausea and vomiting. Classical method of surgical excision followed by intralesional steroids is better tolerated but has higher recurrence rates.

Keywords: Keloids, Intralesional 5-FU, Intralesional triamcinalone acetone

INTRODUCTION

Keloid is an area of benign overgrowth of fibrous tissue that usually develops after healing of a skin injury, and extends beyond the original defect.¹ Keloids clinically manifest as raised, hyper-pigmented, erythematous nodules or plaques, with an irregular border, making them visible and distinct from the surrounding skin. Patients with darker skin have a higher prevalence for keloid than lighter skin.² Keloids may occur anywhere,

but the most common locations are the shoulder, presternal area, neck and upper arms.

Several strategies were suggested for keloid therapy, including combination of various modalities but, to date, no optimal algorithm for management has been proposed. Recently, newer intralesional drugs have been studied widely and found to be quite effective, including verapamil, bleomycin, methotrexate, 5-FU. The main drawback of most of the treatment methods is the

inability to curb its recurrence. This study aims at analysing effectiveness of a newer intralesional drug introduced that is 5-FU and to compare its effectiveness with the age-old technique of surgical excision followed by intralesional steroid injection. Most commonly used steroid for intralesional use is triamcinolone acetonide (TAC) which is the same steroid studied herein.

METHODS

A prospective case control study conducted over a period of 1 year from December 2018 to November 2019 and included patients with keloid in head and neck region who presented to the department of otorhinolaryngology, Navodaya medical college, Raichur, Karnataka, India.

A total of 16 patients were studied and sample size was taken considering the local prevalence of keloids to be 45% and applying the formula.

$$n = \frac{4p(1-p)}{L^2}$$

Where, n=sample size, p=prevalence, L=permissible error.

Patients were categorized into two study groups, Group A (8 patients) - Intralesional 5-FU once in three weeks for six sessions. Group B (8 patients) surgical excision followed by Intralesional Triamcinolone acetonide once weekly for six sessions. The surgery was performed under local anaesthesia. Local anaesthetic (2% lignocaine with 1:100,000 epinephrine) was infiltrated around the keloid. Incision was given over the keloid and skin of the keloid was filleted from keloid mass as a flap and the keloid mass was completely removed. The removal of entire keloid mass was confirmed by palpating the remaining earlobe tissue. First dose of Intralesional triamcinolone acetonide was administered. Bleeding was meticulously controlled; electrocautery to control bleeding was sparingly used, to avoid possible flap necrosis. Keloid flaps were closed with 5-0 nylon after trimming to get the perfect contour. Pressure dressing was applied to the ear and suture removed on 9th to 10th day, followed by second dose of steroid injection.

Patient were followed up for one year from the day of 1st intervention. Comparison was done based on pain (which was analysed using a visual analogue scale), post-operative appearance (which was analysed based on a verbal survey and scored using a Likert's scale from 0-5), recurrence and hyperpigmentation. Fisher's exact probability test was used to compare the outcomes.

Written informed consent was taken and patients in Group A were informed that 5 FU is a chemotherapeutic agent. Routine blood investigations including CBC, RFT, RBS were also done for all patients.

Inclusion criteria

Age group between 18-50, were willing for the study and 1 year follow up. Patients with keloid scars involving head and neck region only.

Exclusion criteria

Previous history of treatment for the same lesion. History of systemic illnesses.

RESULTS

In group A, out of the 8 patients included, only 7 turned up for regular sessions and follow up, hence compliance was only 88%. One patient discontinued after 3 sessions due to complaint of nausea and vomiting after injection. Significant aesthetic improvement was noted in 6 out of 7 patients, based on Likert's scale analysis with an average score of 4, which was statistically significant ($p < 0.05$). No recurrence of lesion or increase in scar size was noted. All 7 patients had complaints of pain which was assessed using a visual analogue scale and graded to be mild to moderate, which was statistically significant ($p < 0.05$). No hyperpigmentation was noted in any patient.

In group B, all patients who were studied were compliant for regular follow ups, hence compliance was 100%. Significant aesthetic improvement was noted in all 8 patients but scarring was a major concern for 6 of them and hence the Likert's scale analysis showed an average score of 3. One patient had scar thickening, after 9 months of surgery, which gave a recurrence rate of 12.5%. However, it did not attain statistical significance ($p > 0.05$). Pain was scored to be mild for all patients. No hyperpigmentation was noted in any patient.

The pain scores of the patients in both groups and the visual analogue scale that was used to analyse the score have been depicted in (Table 1 and Figure 1) respectively below. This pain wise analysis showed that 3 and 4 patients had mild and moderate pain in Group A respectively and all 8 patients had mild pain in Group B and the statistical analysis showed a significant value ($p < 0.05$).

A summary of other features analysed such as compliance, recurrence, and hyperpigmentation has been depicted in (Table 2). A bar chart showing difference in compliance and recurrence rates is depicted in (Figure 6). The compliance rates were 88% and 100% for groups A and B respectively, however it did not attain statistical significance ($p > 0.05$). The recurrence rates were 0 and 12% respectively for groups A and B but had failed to attain statistical significance again ($p > 0.05$). No hyperpigmentation was noted in any of the patients in our study.

Figure 1, depicts the Likert's scale that was used to numerically score the aesthetic improvement noted by the

patients. Average scores were 4 and 3 for groups A and B respectively, which showed statistical significance ($p < 0.05$). The reduced score in group B was mainly attributed to the initial scarring.



Figure 1: Likert's scale used for scoring post-operative appearance.

Table 1: Analysis of pain scores of both groups based on visual analogue scale.

| Pain score | No. of patients (group A) | No. of patients (group B) |
|------------|---------------------------|---------------------------|
| No pain | 0 | 0 |
| Mild | 3 | 8 |
| Moderate | 4 | 0 |
| Severe | 0 | 0 |

| VISUAL ANALOGUE SCALE | | | | | | | | | | |
|-----------------------|---|---|-----------------|---|--------------------------|---|-------------------|---|---|-------|
| 0 | 1 | 2 | 3 | 4 | 5 | 6 | 7 | 8 | 9 | 10 |
| NOPAIN | | | | | | | | | | |
| | | | Annoying (mild) | | | | | | | |
| | | | | | Uncomfortable (moderate) | | | | | |
| | | | | | | | Horrible (severe) | | | |
| | | | | | | | | | | WORST |

Figure 2: Visual analogue scale used for quantifying pain.

Table 2: Comparative analysis of average pain scores, compliance, recurrence and hyperpigmentation between the two groups.

| Feature analysed | Group A (total 8) | Group B (total 8) |
|--------------------|-------------------|-------------------|
| Average pain score | Mild to moderate | Mild |
| Compliance | 88% | 100% |
| Recurrence | 0% | 12.5% |
| Hyperpigmentation | 0% | 0% |

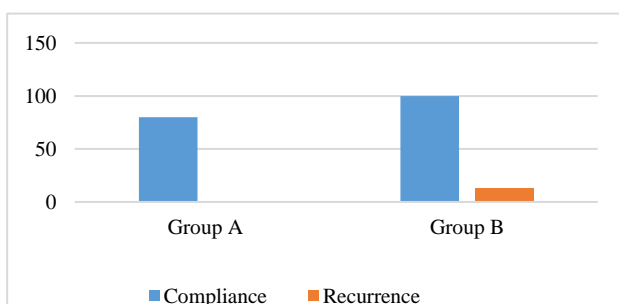


Figure 3: Comparison of compliance and recurrence rates between the two groups.

DISCUSSION

Keloids are hypertrophic-appearing scars that continue to evolve over time without a quiescent or regressive phase in the process of wound healing.^{3,4} They are benign hyper proliferative growths of dermal collagen that usually result from excessive tissue response to skin trauma⁵. They do not spontaneously regress, often continuing to grow over time. Current therapeutic approaches fall into three broad categories: alteration of the inflammatory response; modification collagen metabolism; surgical and physical manipulation of the keloid scar. Therapeutic approaches include surgical excision, Intralesional injection of steroids, verapamil, 5-fluorouracil (5-FU), cryotherapy, laser therapy (fractionated CO₂ laser, Nd: YAG laser, pulsed-dye laser), silicone sheet dressings, irradiation, retinoids, tacrolimus, imiquimod and combination therapy.

Since keloids are notoriously characterized by a high recurrence rate after surgical excision, nonsurgical approaches are recommended for primary treatment. The most common approach is intralesional corticosteroid injection alone or in combination with other treatment modalities. Triamcinolone acetonide (TAC) is the most commonly used intralesional corticosteroid. Despite its benefits, intralesional steroid injections may cause several adverse side effects, both local, such as telangiectasias, skin and subcutaneous fat atrophy, pigmentary changes (hypopigmentation and hyperpigmentation), skin necrosis and ulcerations, and systemic effects, such as Cushing's syndrome.⁶

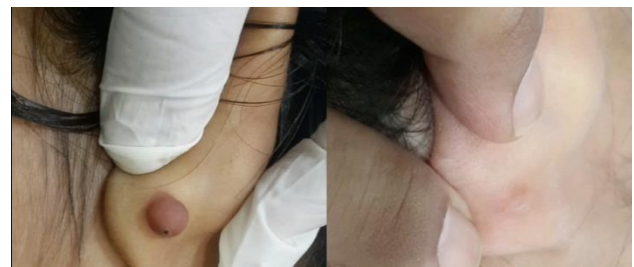


Figure 4: Before and after intralesional 5-FU injection.

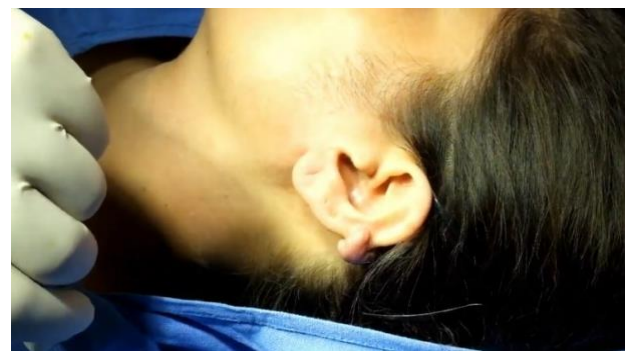

Figure 5: Before surgical excision followed by intralesional triamcinolone acetonide injection.

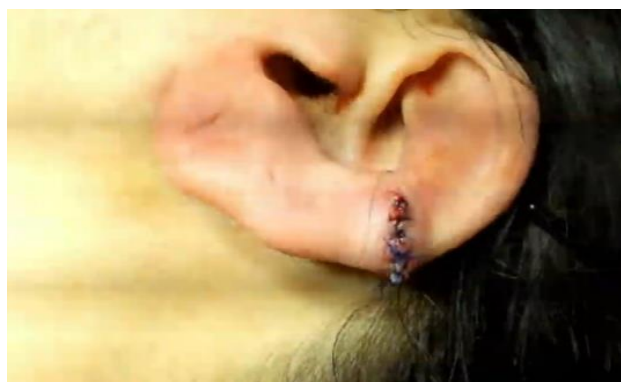

Figure 6: After surgical excision followed by intralesional triamcinolone acetone injection.

Several antineoplastic agents have been tried. Bleomycin has been used both intralesionally and with a multipuncture technique with good results.^{7,8} Methotrexate has also been used but without benefit. Five-fluorouracil (FU), is a pyrimidine analogue with antimetabolite activity with promising results⁹. It has also been tried as a monotherapy in keloids but histologic evaluation and long-term follow-up were not available. Recent studies have evaluated 5-FU both clinically and histologically only in a limited number of patients with keloids and hypertrophic scars.¹⁰

As Uppal et al demonstrated in their study that macrophage numbers and function are not altered by 5-FU, therefore, there is no predisposition for tissue infection¹¹. It has been found that 5-FU delivered intralesionally once weekly or once every 2 weeks in keloids and hypertrophic scars is effective.¹²⁻¹⁴ In our study we had given once in three weeks for six sessions.

Bran et al developed an auricular compression device in 2012 made of two transparent subunits fabricated with acrylate and custom made for every patient. They treated seven auricular keloids with surgical excision and TAC intralesional injection followed by the application of the auricular compression device overnight for at least five nights per week until the scar level matched the level of the surrounding healthy skin. They observed no recurrence during a mean 24 months follow-up time. This device had the advantage of controlling adequately intralesional blood circulation during treatment, thanks to its transparency.¹⁵ In our current study we had given a regular compression dressing with Dynaplast tape.

CONCLUSION

At the end of our study, we have concluded that 5-FU, as evaluated by previous studies has very less recurrence rate, but side effects such as nausea, vomiting and pain at the site of injection can be a burden to treatment and compliance of patients. Classical treatment of surgical excision followed by intralesional steroid injection has a comparatively higher recurrence rate and is associated

with pain and poorer aesthetic appeal due to scarring but is usually well tolerated by patients.

Funding: No funding sources

Conflict of interest: None declared

Ethical approval: The study was approved by the Institutional Ethics Committee

REFERENCES

1. Burrows NP, Lovell CR. Disorders of connective tissue. Burns T, Breathnach S, Cox N, Griffiths C, editors. Rook's textbook of dermatology. 2004;8:45-1.
2. Flore LIC. Misconceptions regarding elective plastic surgery in the black patient. J of the National Medical Association. 1980;72(10):947.
3. Slemp AE, Kirschner RE. Keloids and scars: a review of keloids and scars, their pathogenesis, risk factors, and management. Current opinion in pediatrics. 2006;18(4):396-402.
4. English RS, Shenefelt PD. Keloids and hypertrophic scars. Dermatologic Surgery. 1999;25(8):631-8.
5. Kelly AP. Medical and surgical therapies for keloids. Dermatologic therapy. 2004;17(2):212-8.
6. Coppola MM, Salzillo R, Segreto F, Persichetti P. Triamcinolone acetone intralesional injection for the treatment of keloid scars: patient selection and perspectives. Clinical, cosmetic and investigational dermatology. 2018;11:387.
7. Bodokh I, Brun P. Treatment of keloid with intralesional bleomycin. In Annales de dermatologie et de venereology. 1996;123(12):791-4.
8. Espana A, Solano T, Quintanilla E. Bleomycin in the treatment of keloids and hypertrophic scars by multiple needle punctures. Dermatologic Surg. 2001;27(1):23-7.
9. Pollack SV, Goslen J. The surgical treatment of keloids. J of Dermatologic Surgery and Oncology. 1982;8(12).
10. Kontochristopoulos G, Stefanaki C, Panagiotopoulos A, Stefanaki K, Argyrakos T, Petridis A, et al. Intralesional 5-fluorouracil in the treatment of keloids: an open clinical and histopathologic study. J Am Acad Dermatol. 2005;52(3):474-9.
11. Uppal RS, Khan U, Kakar S, Talas G, Chapman P, Grouther MAD. The effects of a single dose of 5-fluorouracil on keloid scars: a clinical trial of timed wound irrigation after extralesional excision. Plastic Reconstructive Surg. 2001;108(5):1218-24.
12. Fitzpatrick RE. Treatment of inflamed hypertrophic scars using intralesional 5-FU. Dermatol Surg. 1999;25(3):224-32.
13. Gupta S, Kalra A. Efficacy and safety of intralesional 5-fluorouracil in the treatment of keloids. Dermatology. 2002;204(2):130-2.
14. Manuskatti W, Fitzpatrick RE. Treatment response of keloidal and hypertrophic sternotomy scars: comparison among intralesional corticosteroid, 5-

fluorouracil, and 585-nm flashlamp-pumped pulsed-dye laser treatments. *Arch Dermatol.* 2002;138(9):1149-55.

15. Bran GM, Brom J, Hormann K, Stuck BA. Auricular keloids: combined therapy with a new pressure device. *Arch Facial Plastic Surg.* 2012;14(1):20-6.

Cite this article as: Patel VI, Thomas RA. A comparative analysis between intralesional 5-fluorouracil versus surgical excision with intralesional triamcinalone acetonide in keloid excision. *Int J Otorhinolaryngol Head Neck Surg* 2020;6:904-8.