

Original Research Article

Managing laryngotracheal trauma: 3 year experience at a tertiary hospital in North India

Manish Munjal¹, Japneet Kaur^{2*}, Porshia Rishi¹, Harjinder Singh¹,
Nitika Tuli¹, Shubham Munjal³

¹Department of Otorhinolaryngology, ^{1,3}Dayanand Medical College and Hospital, Ludhiana, Punjab, India

²Amcare Hospital, Zirakpur, Punjab, India

Received: 20 January 2020

Revised: 05 February 2020

Accepted: 06 February 2020

*Correspondence:

Dr. Japneet Kaur,

E-mail: drjapneetkaur@gmail.com

Copyright: © the author(s), publisher and licensee Medip Academy. This is an open-access article distributed under the terms of the Creative Commons Attribution Non-Commercial License, which permits unrestricted non-commercial use, distribution, and reproduction in any medium, provided the original work is properly cited.

ABSTRACT

Background: Laryngotracheal trauma includes life threatening injuries that are encountered by emergency care physicians, trauma surgeons and ENT surgeons. These injuries can occur in the most remote areas or in the busiest metropolitan setting. Earlier intervention is vital in order to reduce the mortality and morbidity associated with insult to the aerodigestive tract and surrounding structures.

Methods: This is a retrospective study of 21 patients who presented to the emergency department of Dayanand Medical College and Hospital, Ludhiana, for management of injuries to aerodigestive tract over a period of 3 years from January 2016 to December 2019.

Results: Twenty-one patients were seen with acute injuries to the airway in the emergency department. There were 12 males and 9 female patients out of which there were 10 men and 5 women, 3 girls and 2 boys ranging in age from 9 to 60 years. Although most of these injuries occurred as a result of blunt trauma, 6 were due to penetrating injuries out of which 2 were due to homicidal assault. Stridor was the most common finding followed by surgical emphysema. Twelve patients were in acute respiratory distress requiring emergency procedures to secure the airway. All patients underwent successful repair of the injuries. All patients except 1 had a good airway.

Conclusions: Laryngotracheal injury is rare but very crucial and life-threatening surgical emergency. Timely intervention is crucial in the management of laryngotracheal trauma in order to prevent complications.

Keywords: Airway, Larynx, Stent, Tracheobronchial injury

INTRODUCTION

Laryngotracheal (LT) trauma is a rare entity. Only 0.5% of patients with multiple injuries, who are managed in modern trauma centers, are diagnosed with tracheobronchial injuries.¹ While 3% to 6% of penetrating neck injuries consist of injuries of cervical trachea, such rate is less than 1% in penetrating chest trauma.^{2,3} In general, 1% to 2% of patients with thoracic trauma also have penetrating trachea-bronchial trauma.^{2,4} However, it is associated with increased mortality and morbidity, being the second most common cause of death

in patients with head and neck injuries after intracranial trauma.⁵ Laryngeal trauma has a high mortality rate (9% to 40%), with many patients dying before reaching the emergency room because of severe airway or multiple organ injury.⁶ The primary objective in treating laryngeal trauma is maintaining the airway patency. Early airway management and aggressive physiologic compensation performed in the initial phase are an important determinant in the laryngeal trauma mortality.

Non displaced fractures can be managed conservatively, while surgical reduction of laryngeal framework should

be performed in patients with displaced fractures.^{1,6} The timing of such repair is subject of debate but many studies suggests that early treatment within 48 hours resulted in a higher recovery rate in patients who were treated earlier than those in the delayed treatment group.^{7,8}

This study was conducted in tertiary care hospital in Northern India, which is also a referral centre for various remote areas in the northern region.

The aim of this study was to describe the clinical presentation, management, and outcomes in patients who presented with laryngotracheal trauma due to various injuries to head and neck region over a 3-year period.

METHODS

Retrospective analysis of 21 patients who presented to the emergency department of Dayanand Medical College and Hospital, Ludhiana, for management of injuries to aerodigestive tract over a period of 3 years from January 2016 to December 2019 was done.

All the patients who presented to the emergency department with tracheobronchial injuries were included in this study whereas patients with burn injuries, caustic ingestion, injuries superficial to the platysma were excluded from the study. Patients underwent a thorough physical examination, endoscopic examination of the larynx, radiographic investigations, and management for their condition depending upon Schaeffer grading. Continuous variables including age were tested for normality using the Kolmogorov-Smirnov (KS) test. Categorical variables including gender, type of injury, mode of injury, clinical presentation, and laryngoscopic findings were reported as percentages or proportions. All statistical analysis was performed using Microsoft Excel and Statistical Package of Social Sciences (SPSS) version 17 for Microsoft Windows (SPSS Inc. Released 2008. SPSS Statistic for windows, version 17.0, Chicago).

Ethical approval

All procedures performed in studies involving human participants were in accordance with the ethical standards of the institutional and national research committee and with the 1964 Helsinki declaration and its later amendments or comparable ethical standards.

RESULTS

Demographic data

Majority of the patients were males 12 out of 21 (57.1%), indicating a male preponderance compared to 9 out of 21 female patients (42.8). Male:female gender ratio was 1.33:1.

Highest number of patients were in the younger age group 21 to 30 years. The eldest patient was 75 years of age. young adult group (10 to 30 years) had higher incidence (71%) of LT trauma than elderly age group. Mean age was 28.28 years.

Type of injury

Majority of the patients with LT injuries who presented to the emergency with were due to blunt trauma (12 out of 21) followed by penetrating injury (6 out of 21), while 3 patients presented with clothesline injury to the neck.

Mode of injury

The most common mode of injury was due to road traffic accidents which was more common in men as compared to women. Homicidal injuries were more commonly noted in men. Accidental injuries more commonly seen in women including fall from height, hand pump injury and domestic abuse (Table 1).

Table 1: Mode of injury.

Mode of injury	No. of patients (%)	No. of patients (%)	Females
Road traffic accident	6 (28.57)	4	2
Homicidal	2 (9.52)	2	-
Suicidal	2 (9.52)	1	1
Accidental	9 (42.85)	4	5
Sports injury	2 (9.52)	1	1

Presenting features

The most common presenting symptom at the time of the initial assessment was respiratory distress in the form of breathing difficulties and stridor, which was seen in 12 patients (57.1%), followed by subcutaneous emphysema (28.57%) (Table 2).

Table 2: Presenting features.

Presenting features	Number of patients (%)
Bleeding from the site	3 (14.2)
Open neck wound	5 (23.80)
Dyspnoea (breathing difficulty)	5 (23.80)
Stridor	7 (33.33)
Surgical emphysema/crepitus	6 (28.57)
Bruising	5 (23.80)
Hoarseness of voice	2 (9.52)
Oesophageal injury	4 (19.04)

Laryngoscopic findings

All patients underwent fiberoptic flexible endoscopic examination, the most common laryngeal finding seen was laryngeal odema in 14 (66.67%) patients (Table 3).

Table 3: Laryngoscopic findings.

Laryngoscopic findings	Number of patients (%)
Arytenoid dislocation	2 (9.52)
Laryngeal oedema	14 (66.67)
Oesophageal injury	4 (19.04)
Haematoma vocal cord	2 (9.52)
Unilateral vocal cord palsy	1 (4.76)

Severity of injury Schaeffers grading

All the 21 patients went assessment of severity of injury based on Schaeffer grading (Table 4).

Grade 1 and grade 2 injuries were most commonly seen amongst the patients (33.33% each) comprising of 66.67% of total injuries, while complete cricotracheal separation was noted in 3 patients (14.2%)

Table 4: Severity of injury according to Schaeffer grading.

Severity of injury according to Schaeffer grading	Number of patients (%)
Grade 1 Minor endolaryngeal hematoma without detectable fracture	7 (33.33)
Grade 2 Edema, hematoma, minor mucosal disruption without exposed cartilage, nondisplaced fractures	7 (33.33)
Grade 3 Massive edema, mucosal disruption, exposed cartilage, vocal fold immobility, displaced fracture	1 (4.76)
Grade 4 Group III with two or more fracture lines or massive trauma to laryngeal mucosa	3 (14.2)
Grade 5 Complete LT separation	3 (14.2)

Radiological investigations

Contrast-enhanced computed tomography (CECT) of the neck and chest was performed in all 15 blunt trauma patients (71.42%) and in two patients (9.52%) with a penetrating neck injury. CECT imaging was not performed in patients (26.9%) with an obvious open-neck wounds who clearly required neck exploration. All patients showed dissection of air in the subcutaneous

plane. Ten patients (47.6%) showed thyroid cartilage fracture, of whom, four (19.04%) had a displaced fracture. Five blunt trauma patients (23.8%) showed an isolated tracheal injury, while two patients (9.5%) showed cricoid cartilage fracture with dislocation of the cricoarytenoid joint. Postoperative chest radiographs were performed in all patients who underwent neck exploration.

Treatment given

All patients with penetrating neck injuries underwent neck exploration. Major vessel involvement was seen only in one patient (4.7%), who had laceration of the internal jugular vein leading to massive blood loss. The remaining 20 patients (95.2%) had intact major vessels. Six patients (28.57%) were managed conservatively and 15 patients (71.4%) received surgical intervention in the form of trachesotomy, tracheotomy with LT repair, laryngeal stent placement, primary repair.

Conservative management included head end elevation, administration of low flow oxygen by mask, voice rest, intravenous antibiotics, intravenous steroids, and anti-reflux medications such as proton-pump inhibitors, analgesics, vital monitoring and wide bore cannula aspiration for surgical emphysema.

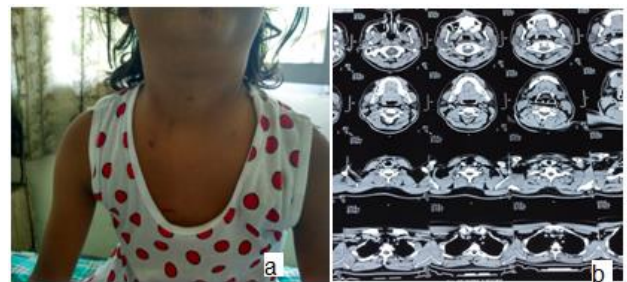


Figure 1 (a and b): Swelling in the anterior part of neck due surgical emphysema, CT scan axial cuts showing extensive subcutaneous emphysema in fascial planes along the sternocleidomastoid, suprasternal notch, and defect in the anterior part of the tracheal ring.

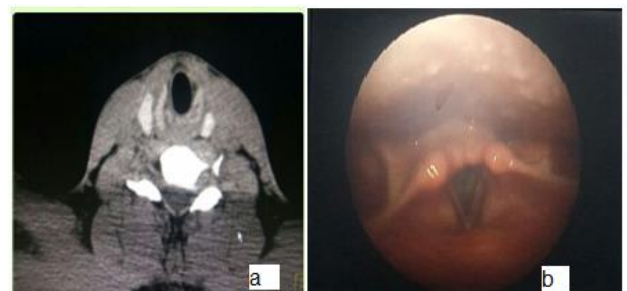


Figure 2 (a and b): Radiological CT scan showing arytenoid dislocation with left false cord haematoma, flexible fiberoptic laryngoscopy showing arytenoid dislocation.

Blunt injury patients who had severe respiratory distress, worsening of symptoms in terms of extending subcutaneous emphysema (Figure 1a and b) on conservative management and radiological and laryngoscopic evidence of dislocated arytenoid cartilage (Figure 2a and b), major endolaryngeal laceration, or evidence of compromised airway underwent neck exploration and tracheostomy. Blunt trauma patients who had minor injuries were managed conservatively.

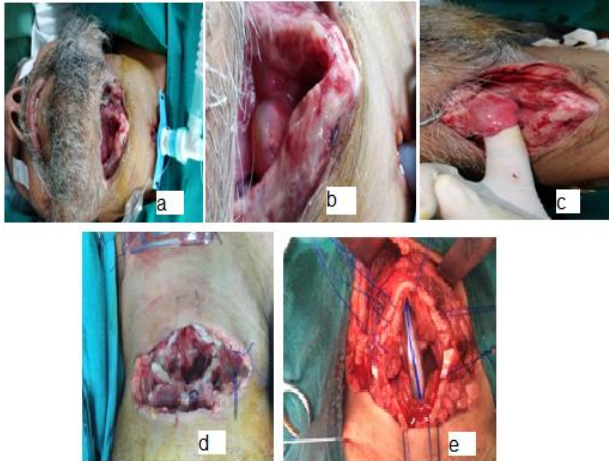

Figure 3: (a-c) Complete cricotracheal separation, (d, e) LT repair over endotracheal tube as stent.

Six patients underwent primary repair of the injuries whilst five patients with severe LT or cricotracheal disruption in these patient's tracheostomy done followed by primary LT repair with vicryl 3-0 and prolene 2-0 suture (Figure 3a-c), tracheal tear underwent laryngeal stent placement (Table 5).

Nine patients with severe injuries underwent tracheostomy with LT repair (Figure 3d) (42.8%).

4 patients (19.04%) had associated hypopharyngeal and esophageal injuries, which were repaired during primary laryngo tracheal repair.

Table 5: Treatment given.

Treatment given	Number of patients (%)
Conservative	6 (28.557)
Laryngeal stenting	5 (23.80)
Primary repair	6 (28.57)
Tracheostomy with LT repair	9 (42.85)
Tracheostomy alone	2 (9.5)

Postoperative complications

Five patients (23.80%) had mild dysphonia following treatment for LT injury, granulation tissue at the site of injury was noted in 4 patients which was removed using potassium titanyl phosphate (KTP) laser.

Postoperative subglottic stenosis was noted in 3 patients, 2 patients who underwent successful laser excision of stenotic segment while 1 patient had laryngeal stent placement for 3 weeks (Figure 4 a-c).

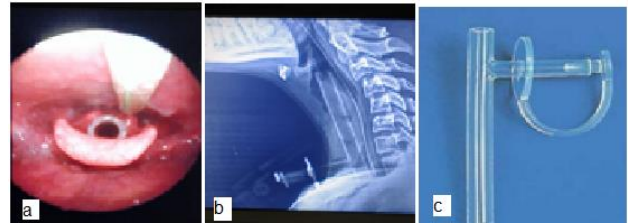

Figure 4 (a-c): Endoscopic picture showing laryngeal stent in situ, lateral radiograph of the neck showing laryngeal stent, silicone laryngeal stent used to prevent glottic stenosis.

2 patients who had presented with previous history of clothesline injury required serial bougie dilatations. Failure decannulation was seen in one patient who was kept on permanent tracheotomy tube. One patient had residual unilateral vocal cord palsy was advised oral steroid and speech therapy.

Table 6: Postoperative complications.

Postoperative complications	Number of patients (%)
Granulation tissue	4 (19.04)
Failure to decannulate	1 (4.76)
Dysphonia	5 (19.04)
Residual vocal cord palsy	1 (4.76)
Subglottic stenosis	3 (14.2)

The average duration of hospital stay was 10 days (range 4 to 14 days). Among the 6 patients who were managed conservatively, the average hospital stay was 3 days, while patients who underwent laryngeal repair had an average hospital stay of 15 days. During 1 month of follow up, a flexible endoscopic assessment was performed on all patients. Patients were followed up after 3 months and 6 months following discharge from the hospital. Six patients (28.57%) were lost to follow up at 3 and 6 months (Table 6).

DISCUSSION

Onotai et al found male preponderance in their study and concluded that it may be due to the risk taking behaviour in men, active participation and frequent involvement in interpersonal violence.⁹

In our study also there was higher proportion of male patients. Similar demographic was observed by Aich et al.¹⁰

In our study younger demographic was more commonly involved as compared to elderly individuals as young

adults are more frequently involved in road traffic accidents. A similar observation was reported by other studies.^{11,12}

Blunt trauma was the most common mode of injury noted in our study as compared to penetrating injuries. this is similar to study by Parida et al.¹²

Most of the blunt trauma injuries in our study were road traffic accidents, 6 out of 21 cases, caused by high speed collision of vehicles with the neck in hyperextension. Blunt forces resulting in hyoid bone fracture with tracheal tear were seen in 2 cases, both males who were riding a bike without wearing a helmet.

The youngest patient with blunt trauma was caused by injury to the neck by hand pump while playing. This patient presented with surgical emphysema in the anterior part of neck extending upto supraclavicular region (Figure 1a and b).

Blunt type of injury depends on the nature of the object that causes the injury, location and velocity of the impact force, and patient related factors (such as age and ossification of the laryngeal cartilages) which can result in minor injury to fracture of the laryngeal cartilage, cricothyroid or cricotracheal separation associated with recurrent laryngeal nerve damage.¹²

Sports related blunt injury to the neck is also common and most commonly seen in high speed sports like football, bicycling, motorbike racing etc.¹³

In our study one male patients presented with stridor due arytenoid dislocation and vocal cord haematoma after being accidentally kicked in the neck during a football match (Figure 2a and b).

Also, the proportion of penetrating laryngeal injury is on the rise, and is thought to be the result of increased trauma caused by industrialization and urbanization. Stabbing injury, injury caused by guns or machines, and other similar types of injury have been reported to be important causes of penetrating neck trauma.^{14,15}

In our study penetrating injuries were either homicidal or suicidal. Penetrating injuries were commonly located over or below the thyroid cartilage, with rupture of the cricothyroid or thyrohyoid which are weak regions in the laryngeal framework. Most of the penetrating injuries were horizontal or oblique deeper cuts resulting in an open wound. Most of the patients were referred to the tertiary hospital for appropriate intervention within 24 hours. Except this one patient with suspected homicidal injury was found by the relatives approximately 24 hours after he disappeared from home and was brought to the emergency thereafter. Patient was brought with a deep horizontal neck wound with complete cricotracheal separation and bulky arytenoids and marked laryngeal oedema and oesophageal tear as well. However he was

maintaining saturation due to complete tracheal breach. In this patient tracheostomy and primary cricotracheal and hypopharyngeal and oesophageal repair was done (Figure 3a-c).

According to Beigh and Ahmad all patients should be referred to the referral centre as early as possible.¹⁶ Delayed presentation may lead to postoperative complications like wound dehiscence and fistula formation and prolonged duration for recovery.

In our study the most common presentation at the time of the initial assessment was respiratory distress in the form of breathing difficulties and stridor, which was seen in 12 patients (57.1%), followed by subcutaneous emphysema (28.57%). This was similar to studies by Schaefer et al, Yen et al, and Cherian et al, who also reported that respiratory symptoms were the most common presentation of neck injury, followed by hoarseness of voice, neck tenderness, and subcutaneous emphysema.^{8,17,18}

Once a laryngeal injury is suspected prompt management should be commenced. The severity of LT can be assessed by American Academy of Otolaryngology Head and Neck Surgery recommended Schaeffer Fuhrman grading system.⁸

CT scanning neck is the gold standard for diagnosing such LT injuries.^{19,20}

In our study, CT scan was undertaken in all blunt trauma patients and in selected patients with penetrating injury. Blunt trauma patients who showed radiological red signs, such as evidence of cartilage exposure, arytenoid dislocation, displaced cartilage fracture, endolaryngeal hematoma.

CT scan can be avoided in patients with an open neck wound with obvious fracture of the laryngeal cartilages and the patient can be directly taken for neck exploration without delay.²¹

We also did flexible endoscopy combined with a CT scan for evaluation of endolaryngeal injuries. This was particularly helpful in assessing cord mobility, arytenoids dislocation and airway oedema.

Nine patients (42.8%) underwent tracheostomy under local anaesthesia and administration of general anaesthesia and further LT repair.

Laryngeal lacerations were closed after redraping of the mucosa over the exposed cartilage with absorbable sutures. Tracheal transections were repaired with vicryl 4.0 sutures in an end to end interrupted fashion placed through all layers of trachea at an interval of 3 to 4 mm.

Laryngeal stents were placed in five patients who had massive endolaryngeal oedema.

There are various types of stents available example silicone, metal and hybrid. We preferred silicone stents due to availability (Figure 4c). In one patient the endotracheal tube was used as stent (Figure 3c). The stents were kept for 2 weeks and removed in the operation theatre under endoscopic guidance

Stents help to maintain proper alignment of the commissure and glottic web formation and subsequent airway stenosis.²²

There was no mortality in any of the 21 patients which was attributed to early intervention and management by a multidisciplinary team.

Hoarseness of voice was the most common complaint of the patients following treatment during follow up which was managed by speech therapy. one patient had residual vocal cord palsy which was managed by extensive speech therapy.

2 patients with clothesline injury developed delayed subglottic stenosis which was treated by serial bougie dilatations.

One patient had failed decannulation was put on permanent tracheostomy tube.

Jalisi et al found that all patients in their study had a good voice quality, and all tracheostomized patients were decannulated successfully.²³

The major limitation in our study was the loss of patients for long-term follow up, meaning that late complications such as stenosis of the airway or quality of voice could not be studied.

CONCLUSION

LT injury is rare but very crucial and life-threatening surgical emergency. Timely intervention is crucial in the management of LT trauma in order to prevent complications. Radiological investigations like computed tomography and flexible endoscopy should be wherever possible to rule out endolaryngeal injuries especially in blunt trauma cases. Prompt management by securing the airway with tracheostomy and meticulous repair of the laryngotracheal mucosa prevents delayed complications. Laryngeal stents can be used order to prevent delayed glottis stenosis. If proper protocol is timely followed, then mortality and morbidity can be avoided.

Funding: No funding sources

Conflict of interest: None declared

Ethical approval: The study was approved by the Institutional Ethics Committee

REFERENCES

1. Gussack GS, Jurkovich GJ, Luterman A. Laryngotracheal trauma: a protocol approach to a rare injury. *Laryngoscope*. 1986;96:660-5.
2. Lee RB. Traumatic injury of the cervicothoracic trachea and major bronchi. *Chest Surg Clin N Am*. 1997;7:285-304.
3. Karmy-Jones R, Wood E.D. Traumatic Injury to the Trachea and Bronchus. *Thorac Surg Clin*. 2007;17:35-46.
4. Symbas PN, Justicz AG, Ricketts RR. Rupture of the airways from blunt trauma: treatment of complex injuries. *Ann Thorac Surg*. 1992;54:177-83.
5. Kiser AC, O'Brien SM, Deterbeck FC. Blunt tracheobronchial injuries: treatment and outcomes. *Ann Thorac Surg*. 2001;71:2059-65.
6. Mendelsohn H, Sidell DR, Berke GS, John MS. Optimal timing of surgical intervention following adult laryngeal trauma. *Laryngoscope*. 2011;121(10):2122-7.
7. Butler AP, O'Rourke AK, Wood BP, Porubsky ES. Acute external laryngeal trauma: experience with 112 patients. *Ann Otol Rhinol Laryngol*. 2005;114(5):361-8.
8. Schaefer N, Griffin A, Gerhardy B, Gochee P. Early recognition and management of laryngeal fracture: a case report. *Ochsner J*. 2014;14(2):264-5.
9. Onotai LO, Ibekwe U. The pattern of cut throat injuries in the University of Port-Harcourt Teaching Hospital, Portharcourt. *Niger J Med*. 2010;19:264-6.
10. Aich M, Khorshed Alam ABM, Talukder DC, Rouf Sarder MA, Fakir AY, Hossain M. Cut throat injury: review of 67 cases. *Bangladesh J Otorhinolaryngol*. 2011;17(3):5-13.
11. Sachdeva K, Upadhyay A. Neck Trauma: ENT Prospects. *Indian J Otolaryngol Head Neck Surg*. 2017;69(1):52-7.
12. Parida PK, Kalaiarasi R, Alexander A. Management of Laryngotracheal Trauma: A Five-Year Single Institution Experience. *Iranian J Otorhinolaryngol*. 2018;30(5):283-90.
13. Irish JC, Hekkenberg R, Gullane PJ, Brown DH, Rotstein LE, Neligan P, et al. Penetrating and blunt neck trauma: 10-year review of a Canadian experience. *Can J Surg*. 1997;40:33-8.
14. Lee WT, Eliashar R, Eliachar I. Acute external laryngotracheal trauma: diagnosis and management. *Ear Nose Throat J*. 2006;85:179-84.
15. Hanft K, Posternack C, Astor F, Attarian D. Diagnosis and management of laryngeal trauma in sports. *South Med J*. 1996;89:631-3.
16. Beigh Z, Ahmad R (2014) Management of cut-throat injuries. *Egypt J Otolaryngol* 30:268-271
17. Yen PT, Lee HY, Tsai MH, Chan ST, Huang TS. Clinical analysis of external laryngeal trauma. *J Laryngol Otol*. 1994;108(3):221-5.
18. Cherian TA, Rupra V, Raman R. External laryngeal trauma: analysis of thirty cases. *J Laryngol Otol*. 1993;107(10):920-3.

19. Bent JP, Silver JR, Porubsky ES. Acute laryngeal trauma:a review of 77 patients. *Otolaryngol Head Neck Surg.* 1993;109(3):441-9.
20. Schaefer N, Griffin A, Gerhardy B, Gochee P. Early recognition and management of laryngeal fracture: a case report. *Ochsner J.* 2014;14(2):264-5.
21. Stanley RB Jr. Value of computed tomography in management of acute laryngeal injury. *J Trauma.* 1984;24(4):359-62.
22. Moonsamy P, Sachdeva UM, Morse CR. Management of laryngotracheal trauma. *Ann Cardiothorac Surg.* 2018;7(2):210-6.
23. Jalisi S, Zoccoli. Management of laryngeal fractures-a 10-year experience. *M J Voice.* 2011;25(4):473-9.

Cite this article as: Munjal M, Kaur J, Rishi P, Singh H, Tuli N, Munjal S. Managing laryngotracheal trauma: 3 year experience at a tertiary hospital in North India. *Int J Otorhinolaryngol Head Neck Surg* 2020;6:459-65.