

Original Research Article

Introduction of a new key step in lateral approach thyroidectomy: a randomised prospective study on thirty patients

Jyotirmoy Phookan, Shilpi Gupta*

Department of Otorhinolaryngology, Assam Medical College, Dibrugarh, Assam, India

Received: 27 January 2020

Revised: 17 March 2020

Accepted: 18 March 2020

*Correspondence:

Dr. Shilpi Gupta,

E-mail: goanurag007@gmail.com

Copyright: © the author(s), publisher and licensee Medip Academy. This is an open-access article distributed under the terms of the Creative Commons Attribution Non-Commercial License, which permits unrestricted non-commercial use, distribution, and reproduction in any medium, provided the original work is properly cited.

ABSTRACT

Background: The school of Bilioth in Vienna started modern thyroid surgeries in 1860s.¹ Thyroidectomy was associated with high mortality, recurrent laryngeal nerve injuries and tetany. One and a half century down the timeline, complications still occur. Although, in experienced hands, the thyroid surgeries performed today are associated with minimal mortality and morbidity. Lateral approach thyroidectomy is a commonly practiced approach with fewer complications. We carried out a study to assess the efficacy, safety and advantages of lateral approach thyroidectomy with a new key step.

Methods: A prospective study was performed on thirty patients undergoing conventional open thyroidectomy from January to July 2019 at a tertiary care hospital in north east India. All patients underwent open thyroidectomy via lateral approach in which identifying superior belly of omohyoid was considered a key step of surgery. Basic demographic data, preoperative diagnosis, operative time, blood loss, need for transection of strap muscles and complications were recorded.

Results: There were no intra-operative complications, without the need to cut strap muscles or sacrifice superior belly of omohyoid in any case. Voice change was seen in one case, improved after steroid administration. One case developed tetany after total thyroidectomy managed with calcium supplements.

Conclusions: Results suggested that lateral approach of thyroidectomy is a quick and safe technique where identification of superior belly of omohyoid considered as our key step, enabled easy delivery of superior pole of thyroid and facilitates easy identification and preservation of vital structures; thus, causing least morbid sequelae.

Keywords: Lateral approach thyroidectomy, Superior belly of omohyoid, Thyroidectomy

INTRODUCTION

In 1920 Dr. William S. Halsted's said, "The extirpation of the thyroid gland, typifies, perhaps better than any operation, the supreme triumph of the surgeon's art. A feat which today can be accomplished by any competent operator without danger of mishap and which was conceived more than one thousand years ago. There are operations today more delicate and perhaps more difficult. But is there any operative problem propounded so long ago and attacked by so many which has yielded

results as bountiful and so adequate?" Over the last one and a half century, technique of thyroidectomy has evolved, travelling an ever-changing path with numerous milestones. In 1880, Sandstrom discovered the parathyroid gland and later it was established as the culprit for post thyroidectomy tetany.² Kocher, a surgeon from Bern in the late nineteenth century pioneered the meticulous surgical technique that resulted in drastic reduction of complications associated with thyroidectomy.³ Kocher also described the cachexia strumipriva syndrome in the patients of thyroidectomy as

a result of hypothyroidism.⁴ Once it was considered to be bound for failure and carried significant mortality and morbidity. Nowadays, various newer techniques have the incision smaller and complications minimal.

The lateral approach to thyroid (LATT) is one such novel innovation that has made thyroid surgeries safer. In this approach an anatomical window bound by Omohyoid's superior belly laterally, sternohyoid and sternothyroid (strap muscles) medially and lobe of thyroid forming the base is identified. For entering this window, it only requires opening the investing layer of deep cervical fascia. This makes management of the superior thyroid vessels and middle thyroid veins easier, thus facilitating easy lateral part of the dissection with mobilisation and delivery of thyroid lobe from underneath the taut strap muscles to the midline wound, without the need of their division or excessive retraction.⁵

We carried out a prospective study in which we performed lateral approach thyroidectomy in 30 cases in period of 6 months and noted different parameters which define "a successful thyroidectomy" that is removal of diseased gland and at the same time preserving and identifying critical structures identified in relation to superior belly of omohyoid like superior laryngeal nerve, middle thyroid vein, recurrent laryngeal nerves, parathyroid glands with least complication and least long term morbidity.

METHODS

We conducted a prospective interventional study on 30 patients undergoing conventional open thyroidectomy via lateral approach from 1st January to 31st July 2019 at a tertiary care teaching centre in Assam, India. A prior ethical committee clearance was obtained and the patients were selected based on inclusion and exclusion criteria that were pre-defined. The statistical analysis of data was performed using the computer program, statistical package for social sciences (SPSS for windows, version 20.0. Chicago, SPSS Inc.) and microsoft excel 2010. The informed written consent was taken from all the participants of the study. Patients coming to our outpatient department with complaints of swelling over thyroid gland were identified and detailed history and clinical examination was done along with ultrasonography and fine needle aspiration cytology (FNAC) and CT neck and thorax (if required). Our inclusion criteria were: large goiter, not more than 12 cm greatest dimension (by USG), malignant goiter of size less than 12 cm. while our exclusion criteria were very huge goiter >12 cm in greatest dimension, retrosternal goiter reaching to aortic arch, recurrent retrosternal goiter, history of neck irradiation, recurrent thyroid disease, thyroid disease in post-radiotherapy patient, and patients coming for completion thyroidectomy.

Thirty patients were selected and all underwent routine blood investigations, thyroid function test and chest

roentgenogram video direct laryngoscopy to document vocal cord movement. Basic demographic data, preoperative diagnosis, plan of surgery, any comorbidities, etc. were recorded (Table 1). The patients underwent pre anaesthetic check up and upon fitness were posted for surgery.

Operative technique

All the surgeries were performed by the same surgical team with same leading surgeon on weekdays between 9 am to 2 pm. Type of surgery done, operative time, blood loss, complications, the need to divide strap muscles, identification of parathyroid glands, recurrent laryngeal nerves and superior laryngeal nerve and post-operative complications were recorded.

Under general endotracheal anaesthesia the patient was kept in supine position with gentle neck extension and arms stuck to patient's both sides with perfect alignment of the head and body for suitable placement of the incision and adequate anatomical exposure. Pre-operative shot of intravenous ceftriaxone was given and the parts were painted and draped in sterile manner.

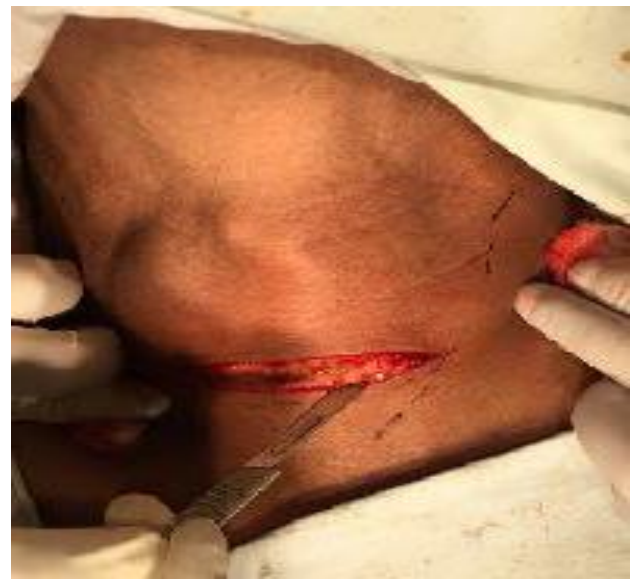

Figure 1: Horizontal skin incision 2 cm above suprasternal notch.

In lateral approach technique, the same 4-6 cm skin crease neck incision was used (Figure 1) but instead of midline separation and retraction of strap muscles, the anterior border of sternocleidomastoid was identified and mobilized laterally. The superior belly of omohyoid is traced up to its insertion in hyoid bone and retracted cranially. The lateral edge of strap muscles was identified and retracted medially to expose the underlying goitre. The ansa cervicalis is identified coursing downwards anterior to the sternohyoid muscle and retracted medially with the sternohyoid and sternothyroid muscles to expose the anterior surface of the thyroid lobe.

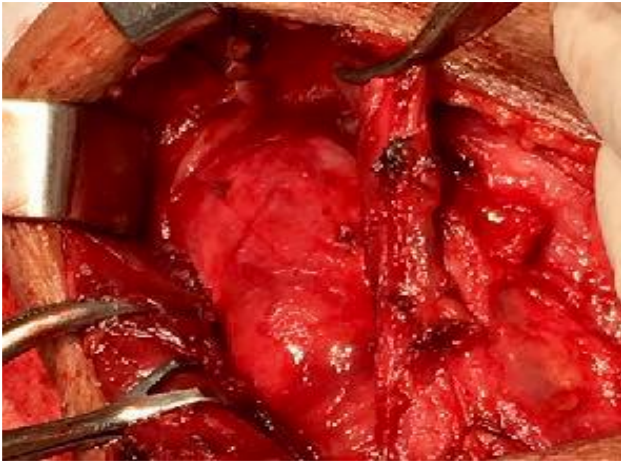

Figure 2: Identification of superior pedicle via lateral approach.

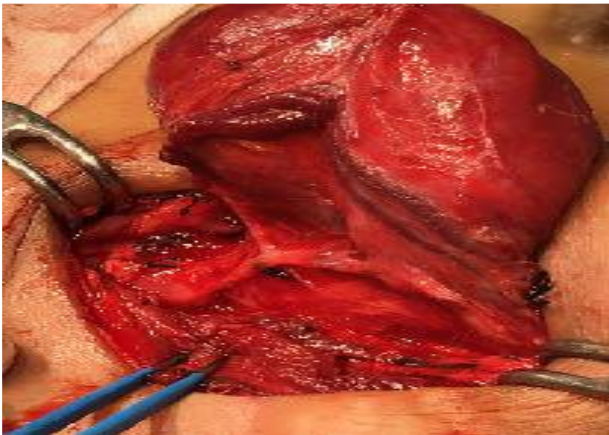


Figure 3: Identification and ligation of middle thyroid vein.

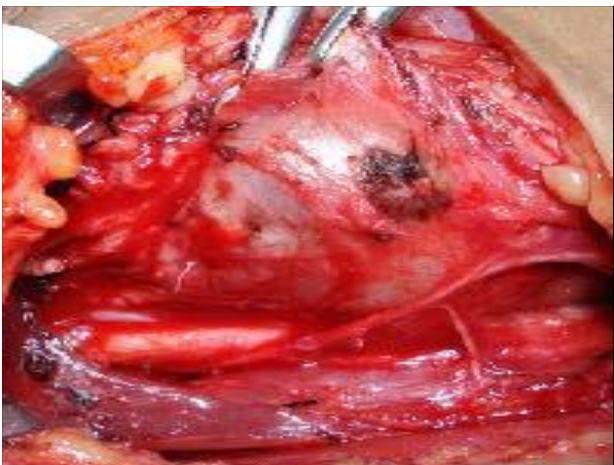

Figure 4: Identification of recurrent laryngeal nerve.

Next, the thyroid was retracted downwards and superior pole of thyroid identified the triangle. The superior vascular pedicle (Figure 2) could be easily identified in this technique allowing individual ligation of vessels and preservation of external laryngeal nerve. Once the middle

thyroid vein (Figure 3) was identified (if present) mostly at junction of superior belly of omohyoid and internal jugular vein and ligated, the rest of thyroid lobe can be easily dissected and retracted medially for easier identification of recurrent laryngeal nerve (Figure 4) at the point of entry at cricothyroid junction or in Simon's triangle and superior parathyroid glands identified (Figure 5) in the lateral triangle itself in posterolateral aspect of thyroid lobe and inferior parathyroid in close proximity to inferior thyroid vessels. The inferior thyroid veins can be easily located travelling transversely over common carotid artery and ligated (Figure 6).

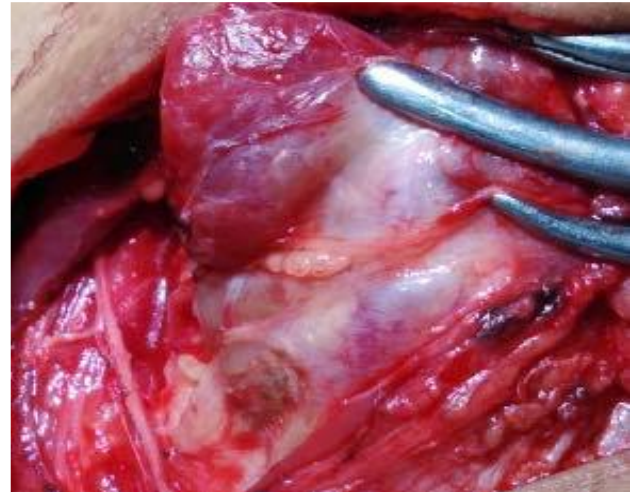

Figure 5: Identification of superior parathyroid.

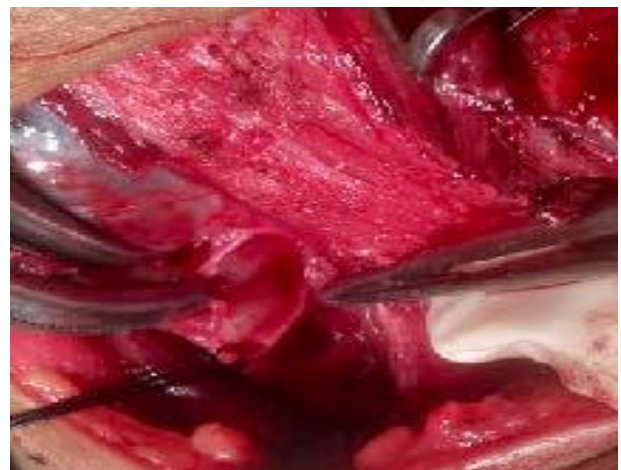

Figure 6: Ligation of inferior thyroid vessels.

The thyroid lobe was freed from its attachment to the ligament of Berry and underlying tracheal rings. For hemithyroidectomy, the isthmus was then transected (Figure 7) to complete the operation. For patients undergoing total thyroidectomy, similar dissection of the opposite lobe was performed after identifying and retracting the opposite SCM. Once both the thyroid lobes were fully dissected and freed from the overlying strap muscles, the smaller of the lobes could be easily pushed beneath strap muscles to the opposite site. Wash with

warm normal saline is given and haemostasis is achieved by ligation and cauterisation. At the end of operation, the midline strap muscles cover over the trachea remained intact preventing adherence of skin flap to the tracheal cartilage. Drain was given and skin closed in layers. Sterile dressing was done and the patient was extubated. All total thyroidectomy specimens were removed intact in the LA group measured and sent for histopathological examination. Intravenous ceftriaxone and analgesia were given post operatively.

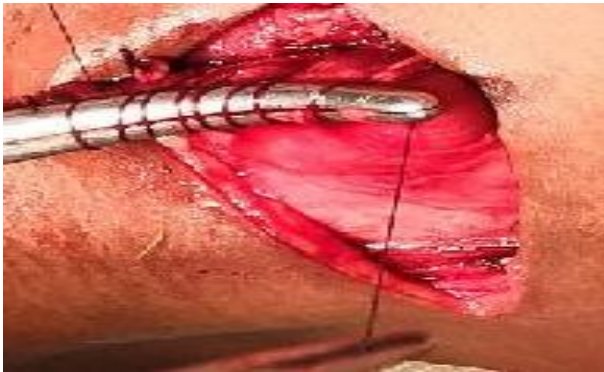

Figure 7: Ligation of thyroid isthmus in hemithyroidectomy.

Parameters recorded: intraoperative blood loss was total of drain collection and no. of gauze used (1 gauze =7 ml blood). Complications of postoperative voice changes, swallowing difficulty, postoperative stridor or respiratory distress, tetany (both by trousseau sign and serum

calcium level measured after 24 hours), hematoma or serosa formation were checked clinically.

Patients were discharged on 3rd post-operative day with or without thyroxine (depending upon the procedure). Follow up was done after 1, 2 and 6 week and healing of scar mark and TSH level and other complication (if any) were noted.

RESULTS

No patients were lost to follow up during the period of six months. The mean age of the patients was 40 years, (ranged from 25-50 years), they included 27 females and 3 males (9:1). 27 patients (90 %) were euthyroid, 3 (10 %) were controlled toxic goiter.

Table 1: Basic demography.

Sex	Number of patients
Male	27
Female	3

The pathology was unilateral lobe colloid goitre in 14 patients (46.6 %), multi nodular bilateral lobe in 7 (23.3 %), unilateral follicular neoplasm (Bethesda category 4) in 3 patients (10 %), unilateral follicular neoplasm (Bethesda category 5) in 1 patient (3 %), papillary carcinoma unilateral lobe of thyroid in 1 patient (3 %) and nodular goitre in unilateral lobe in 2 patients (6 %) (Table 2).

Table 2: Preoperative diagnosis and procedure performed.

Pre-operative diagnosis (FNAC and USG)	Number of patients	Percentage	Procedure performed (lateral approach)
Colloid goitre (U/L)	14	46.6	Hemithyroidectomy
Multi nodular goitre (B/L)	7	23.3	Total thyroidectomy
Follicular neoplasm (Bethesda cat 4) (U/L)	3	10	Hemithyroidectomy
Toxic nodular goitre (U/L)	2	6	Hemithyroidectomy
follicular neoplasm (Bethesda cat 5) (U/L)	1	3	Hemithyroidectomy
Papillary carcinoma (U/L)	1	3	Total thyroidectomy with bilateral and central neck dissection

Table 3: Intraoperative and postoperative complications.

Complications	Number of patients	Treatment given
Conversion to strap muscles cutting	0	-
External branch of SLN injury	0	-
Recurrent laryngeal nerve injury (transient + permanent) with voice change post operatively	1 (Transient)	Steroid administration
Parathyroid injury with postoperative tetany	1	Calcium supplements (serum calcium monitoring)
Seroma or hematoma formation	0	-
Swallowing difficulty	0	-
Postoperative stridor or respiratory distress	0	-
Hypothyroidism (biochemical)	8	Thyroxine administration TSH, T3, T4 monitoring

Parathyroid glands were identified and preserved in all patients. The mean amount of intra-operative blood loss was 84 ml (range; 49-124 ml) and post-operative drainage was 30 ml (range; 10-70 ml). The mean operative time was 90 minutes (range; 60-140 minutes).

The average hospital stay was 3 days, (ranged from 2 to 6 days). The intra-operative and post-operative data (Table 3). There were no intra-operative complications, this approach succeeded without the need to cut strap muscles in any case. Also, sacrificing of superior belly of omohyoid was also not required in any of the cases. Voice change was seen in 1 case which improved after steroid administration. 1 case developed tetany after total thyroidectomy who was administered with calcium supplements.

DISCUSSION

The triangle formed by sternothyroid and sternohyoid muscle medially, superior belly of omohyoid laterally and base formed by thyroid lobe is the first step for extraction of thyroid. When thyroid mass is retracted downward, superior pole of thyroid is visible and facilitates easy identification of superior thyroid pedicle and superior laryngeal nerve and ansa cervicalis. At junction of superior belly of omohyoid and internal jugular vein, the origin of middle thyroid vein can be easily identified. This triangle gives direct view of cricothyroid muscle and recurrent laryngeal nerve can be easily identified entering inside. Also, the superior parathyroid can be easily identified on posterolateral aspect of thyroid lobe and blood supply distal to parathyroid branch can be ligated.

Hence one structure can give a proper guide for identification of all the vital structures and decrease related complications and the operating time. When performed in specialized centers with an adequate training, good understanding of the anatomy and pathology, and with a meticulous dissection technique. Low morbidity and a virtually 0 % mortality can be achieved with lateral approach of thyroidectomy. Cutting the strap muscles is considered a cause voice changes after thyroidectomy, swallowing difficulties and laryngeal nerve injury.^{7,8} With lateral approach even large thyroid mass can be extracted out without the need of cutting strap muscle. Identifying the superior belly of Omohyoid as the key step enables an easy identification and protection of important structures and reduces the operating time and blood loss. As incision required for lateral approach range between 3 to 6 cm along the Langerhans lines, scar mark was minimal and cosmetically acceptable. The lateral approach is associated with lower incidence of adhesion of scar tissue compared to midline approach.⁶ Singaporewalla et al. found post-operative pain and rate of transection of strap muscles was significantly lesser in lateral approach compared to midline approach.⁹

CONCLUSION

Lateral approach of thyroidectomy is a quick and precise way of removing thyroid swelling with least associated complications. Identification of superior belly of omohyoid should be considered as key step of lateral approach. It ensures the best possible outcome for all patients irrespective of their preoperative diagnosis or size of thyroid swelling, easy identification of structures like superior thyroid pedicle, external branch of superior laryngeal nerve, recurrent laryngeal nerve, middle thyroid vein, superior parathyroid and also helps in lateral neck dissection without any extra incision. It also provides a bloodless field when compared to other approaches.⁵ We might justifiably conclude that, by considering lateral approach as your choice of surgery, would definitely give the surgeon a satisfying result in all aspect.

ACKNOWLEDGEMENTS

I feel highly obliged to get this opportunity to observe, learn and compile this study under guidance of my teacher Prof. Dr. J. Phookan, head of department, otorhinolaryngology department, Assam medical college, Dibrugarh. I would also like to thank my parents, my brother and my husband Dr. Anurag Singh for their guidance and immense support. I would like to thank all of my patients without whom this study would never have been possible.

Funding: No funding sources

Conflict of interest: None declared

Ethical approval: The study was approved by the Institutional Ethics Committee

REFERENCES

1. Halsted WS: The operative story of goitre. Johns Hopkins Hosp Rep. 1920;19:71.
2. Thompson NW: The history of hyperparathyroidism. Acta Chir Scand. 1990;156:5-21.
3. Kocher T: Uber Kropfextirpation und ihre Folgen. Arch Klin Chirurgie. 1883;29:254.
4. Kaplan E, Angelos P, Applewhite M, Mercier F, Grogan RH. Chapter 21 surgery of the thyroid. In: Feingold KR, Anawalt B, Boyce A, Chrousos G, Dungan K, Grossman A, et al., editors. Endo text. South Dartmouth (MA): MDText.com, Inc.; 2000.
5. Kordy EM, Attia SG, Anwar HW, Mohamed IA, Elgamal R, Shalamesh MI, et al. Lateral backdoor approach versus conventional anterior approach in recurrent. Thyroid surg. 2019;9(1):5.
6. Uludag M, Yetkin G, Citgez B, Isgor A, Atay M, Kebudi A, et al. Contribution of gamma probe guided surgery to lateral approach completion thyroidectomy. Endocr Pract. 2009;15:213-9.
7. Bliss RD, Gauger PG, Delbridge LW. Surgeon's approach to the thyroid gland: surgical anatomy and the importance of technique. World J Surg. 2000;24(8):891-7.

8. Lombardi CP, Raffaelli M, Alatri DL, Marchese MR, Rigante M, Paludetti G, et al. Voice and swallowing changes after thyroidectomy in patients without inferior laryngeal nerve injuries. *Surgery*. 2006;140(6):1026-32.
9. Singaporewalla RM, Tan BC, Rao AD. The lateral “backdoor” approach to open thyroid surgery: A comparative study. *Asian J Surg*. 2018;41(4):384-8.

Cite this article as: Phookan J, Gupta S. Introduction of a new key step in lateral approach thyroidectomy: a randomised prospective study on thirty patients. *Int J Otorhinolaryngol Head Neck Surg* 2020;6:892-7.