

## Case Report

# Gradenigo's syndrome: a petrous apex lesion

Meena V. Kale\*, Ninad S. Gaikwad, Sanjay C. Chhabria

Department of Otorhinolaryngology, T.N.M.C. and B.Y.L.Ch. Nair Hospital, Mumbai Central, Maharashtra, India

**Received:** 29 January 2020

**Revised:** 02 March 2020

**Accepted:** 03 March 2020

### \*Correspondence:

Dr. Meena V. Kale,

E-mail: meenakale33@gmail.com

**Copyright:** © the author(s), publisher and licensee Medip Academy. This is an open-access article distributed under the terms of the Creative Commons Attribution Non-Commercial License, which permits unrestricted non-commercial use, distribution, and reproduction in any medium, provided the original work is properly cited.

### ABSTRACT

Unsafe chronic suppurative otitis media (CSOM) requires early attention, otherwise leads to various extracranial and intracranial complications. Petrositis is one of the complications of temporal bone due to unsafe CSOM leading to inflammation or abscess in the petrous apex along with involvement cranial nerves V and VI nerve and leading to a trio of symptoms like ipsilateral otorrhea, deep facial pain and ipsilateral lateral rectus palsy, this clinical trio collectively called as Gradenigo's syndrome. We have done retrospective study of 3 cases who were presented to our tertiary care centre ENT-OPD with symptoms suggestive of Gradenigo's syndrome. Cases selected by simple random sampling. Cases with ear malignancy was excluded from study. Cases were followed up for 3 months and results were analysed. Petrositis if ignored can lead to rare but fatal complication of unsafe CSOM. Common in males in third decade and the ear swab suggestive of common organism was pseudomonas. Medical management given as per culture and sensitivity report of ear swab and then followed by definitive surgery of canal wall down tympano-mastoidectomy with petrous apex decompression.

**Keywords:** Canal wall down tympano-mastoidectomy, Gradenigo's syndrome, *Pseudomonas*, Unsafe chronic suppurative otitis media

### INTRODUCTION

Petrous apex in 30% cases is a well pneumatized part of temporal bone.<sup>1</sup> Infection to petrous apex is rare due to early detections and treatment of otological symptoms. Due to it being a pneumatized bone, spread of infection was easier than mixed or sclerosed mastoid which resist the spread.

As there is increase in awareness of otological complaints and its treatment, ceases the petrous apex involvement and its further manifestation. Unsafe chronic suppurative otitis media (CSOM) and cases of malignant otitis externa which inspite of receiving adequate medical management were liable to spread infection from mastoid to the petrous apex gradually.

Petrous bone involvement if inadequately treated leads to petrous apex inflammation with abscess formation which ultimately involves fifth and sixth cranial nerves along with purulent ear discharge. Trigeminal nerve ganglion lies on the superior aspect of petrous apex while the abducent nerve lies on the medial aspect of petrous bone which makes them liable for involvement in petrositis.<sup>2,3</sup>

As per our study, gram negative bacteria (*Pseudomonas aeruginosa*) was predominant, which can spread the infections anatomically and through the pathological pathway. Pneumatization of the petrous apex results from extension of air cells along infralabyrinthine, anterior, superior, posteromedial, or subarcuate tracts that communicate directly with the mastoid or middle ear cavity and provide direct pathways for disease. Commonly anatomical obstruction of drainage pathway

of mastoid cavity leads to subsequent infection or inflammation. While pathological pathway is rare, it can start from middle ear infection and then by eroding tegmen tympani, tegmen antri which subsequently leads to dural irritation with pachymeningitis and involvement of petrous apex.<sup>4</sup>

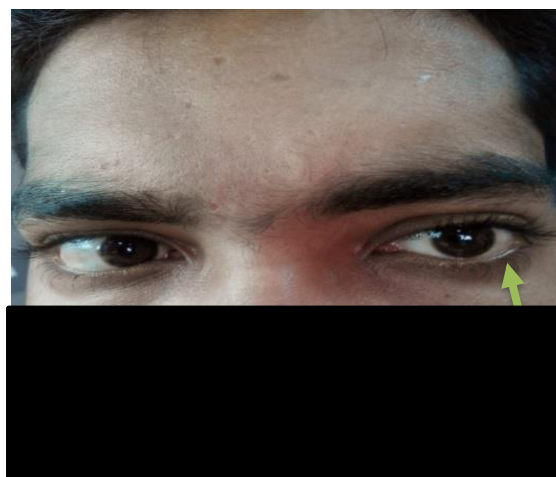
Petrous apex lesion leads to a clinical triad of otorrhea, deep facial pain along the distribution of trigeminal nerve viz. (V1: ophthalmic, occasionally V2: maxillary i.e. retro-orbital pain) and 6<sup>th</sup> nerve involvement leads into ipsilateral lateral rectus palsy. Symptom of trio collectively called as Gradenigo's syndrome.<sup>5</sup>

Gradenigo's syndrome was first described by Guiseppe Gradenigo in 1904.<sup>6</sup> Since decades incidences have seen a decline due to era of broad spectrum antibiotics as well health awareness programmes like ENT diagnostic camps.<sup>7</sup> Clinical symptoms was the criteria to start with medical management. We have diagnosed Gradenigo's syndrome on clinical basis and radiological investigations like high resolution computed tomography (HRCT) of temporal bone and magnetic resonance imaging (MRI) of brain especially the area around petrous apex.<sup>8</sup>

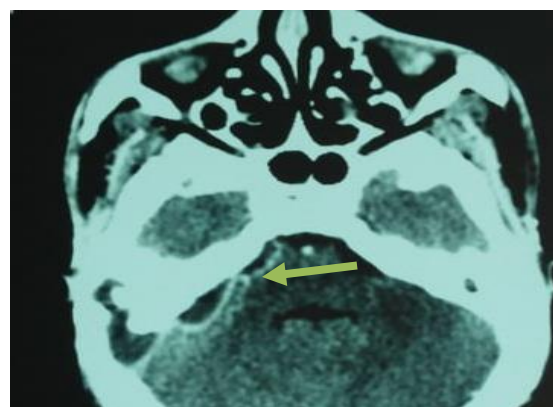
Patients received long term (3 to 4 weeks) indoor conservative medical management with close observations. With weekly SCAST (sensitivity and culture test) report to check for the correct antibiotics so as to provide symptomatic relief. This was followed by surgical intervention to treat the unsafe CSOM and decompression of petrous apex.

## CASE REPORTS

We have studied 3 male cases which clinically presented with unsafe CSOM and on examination they also had a trio of Gradenigo's syndrome. All the cases were in the age group of third-fourth decade and have visited our tertiary care hospital. Informed and willing consent for surgery was taken from all. All the cases presented initially with otorrhea (100%) which was inadequately treated by the patients for a long time. This was followed by mild to severe ipsilateral headache (75%). When the patients reached hospital for uncontrollable symptoms, a ear swab was sent for SCAST. Bacteriology in most cases was gram negative pseudomonas aeruginosa (75%) and occasionally along with staphylococcus aureus (25%). In a developing country mycobacterium tuberculosis is also a one of the infective entity which we didn't find in our study.<sup>3</sup> For the same, all patients were admitted and received a specific and sensitive intravenous antibiotics as per SCAST report for 2 to 3 weeks. But even then, the symptoms persisted and aggravated with development of ipsilateral facial pain (60%) and lateral rectus muscle (100%) (Figure 1) palsy leading to simulation of diplopia along with fever were subjected to surgical intervention after stabilization. Unusual symptoms like loss of corneal reflex, due to irritation of ophthalmic branch of afferent pathway of trigeminal nerve were also seen.



**Figure 1: Left lateral rectus palsy.**



**Figure 2: HRCT temporal bone: suggest enhancing hypodense extra-axial collection upto petrous apex bone along with mastoiditis.**

For confirmed diagnosis and their management; clinically suspected cases with Gradenigo's syndrome were subjected to HRCT temporal bone along with MRI of brain. HRCT temporal bone gives a fair idea about mastoid bone soft tissue involvement along with apical petrositis and occasional petrous apex abscess (Figure 2); while MRI brain gives soft tissue shadow in and around petrous apex (T1 weighted MRI: inflammation of petrous apex along with peripheral enhancement of gadolinium and T2 weighted MRI: petrous apex high signal intensity).<sup>8,9</sup>

One of the studies is in favour of only conservative management, but we preferred both conservative as well surgical treatment for better compliance of any age patient.<sup>10</sup> None of the study suggested about the continuation of duration of conservative management. Only one patient with lateral rectus palsy showed minimal improvement after 2 weeks of intravenous antibiotics while rest two required long duration 6 to 8 weeks of intravenous antibiotics perioperatively. At the end 2 patients of petrositis with 1 case of petrous abscess after adequate but failed medical therapy had to

undergone drainage of abscess by canal wall down tympano-mastoidectomy.

## DISCUSSION

In our study; 3 cases of Gradenigo's syndrome presented to our ENT department. This discussion is based on clinical presentations and their management.

Due to advent of antibiotics and early diagnosis of unsafe CSOM; incidences of complications has decreased, but once in a while it shows appearance in a developing country especially in those who neglected long standing otorrhea.<sup>11</sup> Commonly SCAST report showed pseudomonas responsible for long standing otorrhea in petrositis.<sup>12</sup> In our study majority cases were male of age group in third decade. With common presentation foul smelling long standing otorrhea, mild to moderate ipsilateral headache, ipsilateral lateral rectus palsy and ipsilateral deep facial and retro-orbital pain.

Imaging modalities like HRCT temporal bone and MRI brain are helpful tool in diagnosis, management as well in monitoring the progression and improvement of the condition.<sup>12</sup> HRCT will show bony destructive lesion till petrous apex and T1-weighted MRI is helpful in soft tissue assessment in petrous apex lesions which is inadequately provided by CT scan.<sup>10</sup> Hence both the modalities are essentially important.

Medical management with intravenous higher antibiotics with long duration for 2 to 3 weeks pre-operatively followed by surgical canal wall down tympano-mastoidectomy with petrous apex decompression and drainage along with continuation of medical therapy for 2 more weeks is the definitive management.<sup>11</sup>

## CONCLUSION

Gradenigo's syndrome is a rare disease and petrositis at times a fatal complication of unsafe CSOM due to medially involvement of the meninges, cavernous sinus and brain. But in remote and rural part of developing country due to poverty, ignorance of ear disease, non-availability of diagnostic as well therapeutic services leads to unsafe CSOM disease with its complications. Awareness as well as health education programme has decreased the incidences in 20<sup>th</sup> century. Hence radiological as well clinical coordination is important to diagnose and treat the accurate disease entity. HRCT temporal bone and MRI brain are the main investigations for diagnostic and therapeutic purposes. Medical management in association with canal wall down tympano-mastoidectomy with petrous apex drainage is the effective mode of treatment.

Before we conclude we had one more patient a 76 year old male with uncontrolled diabetes and radiological

features of petrositis including pseudomonas but had no clinical presentation of Gradenigo's syndrome, a mystery.

As we conclude, medical and surgical management gives a synergistic effect and complete reversal of disease.

*Funding: No funding sources*

*Conflict of interest: None declared*

*Ethical approval: Not required*

## REFERENCES

1. Gibier L, Darrouzet V, Franco-Vidal V. Gradenigo syndrome without acute otitis media. *Pediatr Neurol.* 2009;41(3):215-9.
2. Tornabene S, Vilke GM. Gradenigo's syndrome. *J Emerg Med.* 2010;38(4):449-51.
3. Lutter SA, Kerschner JE, Chusid MJ. Gradenigo syndrome: a rare but serious complication of otitis media. *Pediatr Emerg Care.* 2005;21(6):384-6.
4. Plodpai Y, Hirunpat S, Kiddee W. Gradenigo's syndrome secondary to chronic otitis media on a background of previous radical mastoidectomy: a case report. *J Med Case Rep.* 2014;8:217.
5. Kantas I, Papadopoulou A, Balatsouras DG, Aspris A, Marangos N. Therapeutic approach to Gradenigo's syndrome: a case report. *J Med Case Rep.* 2010.
6. Matis GK, de A Silva DO, Chrysou OI, Karanikas MA, Birbilis TA. Giuseppe Gradenigo: Much more than a syndrome! Historical vignette. *Surg Neurol Int.* 2012;3:122.
7. Hafidh MA, Keogh I, Walsh RM, Walsh M, Rawluk D. Otogenic intracranial complications. a 7-year retrospective review. *Am J Otolaryngol.* 2006;27(6):390-5.
8. Hardjasudarma M, Edwards RL, GanleyJP, Aarstad RF. Magnetic resonance imaging features of Gradenigo's syndrome. *Am J Otolaryngol.* 1995;16:247-50.
9. Hitier M, Boutet C, Faure C, Moreau S. Radiology quiz case 2. Gradenigo's syndrome caused by right petrous apicitis. *Arch Otolaryngol Head Neck Surg.* 1998;119:444-54.
10. Rossor TE, Anderson YC, Steventon NB, Voss LM. Conservative management of Gradenigo's syndrome in a child. *BMJ Case Rep.* 2011;2011:bcr0320113978.
11. Kandakure VT, Khokle PD, Shah UR. Management of unsafe type of chronic supportive otitis media with extracranial complications of tertiary care center. *Indian J Otol.* 2018;24:129-34.
12. Jacobsen CL, Bruhn MA, Yavarian Y, Gaihede ML. Mastoiditis and Gradenigo's Syndrome with anaerobic bacteria. *BMC Ear Nose Throat Disord.* 2012;12:10.

**Cite this article as:** Kale MV, Gaikwad NS, Chhabria SC. Gradenigo's syndrome: a petrous apex lesion. *Int J Otorhinolaryngol Head Neck Surg* 2020;6:773-5.