

## Original Research Article

# Turbinoplasty of concha bullosa: a useful adjunct in improving nasal airway

Nithya Venkataramani<sup>1\*</sup>, Ravi Sachidananda<sup>1</sup>, Srividya Rao Vasista<sup>2</sup>

<sup>1</sup>Department of ENT, <sup>2</sup>Department of Dentistry, People Tree Hospitals, Bengaluru, Karnataka, India

**Received:** 19 January 2020

**Revised:** 06 March 2020

**Accepted:** 07 March 2020

### \*Correspondence:

Dr. Nithya Venkataramani,

E-mail: [nithya.venkataramani@gmail.com](mailto:nithya.venkataramani@gmail.com)

**Copyright:** © the author(s), publisher and licensee Medip Academy. This is an open-access article distributed under the terms of the Creative Commons Attribution Non-Commercial License, which permits unrestricted non-commercial use, distribution, and reproduction in any medium, provided the original work is properly cited.

### ABSTRACT

**Background:** Concha bullosa is the pneumatisation of middle turbinate which causes crowding and obstruction of the middle meatus. This is associated with contralateral septal deviation. The objective of this study is to evaluate, if a concha bullosa turbinoplasty has any added value in improving nasal symptoms when performed as adjunct with septoplasty.

**Methods:** Retrospective analysis of the hospital database was done and details of patients who underwent septoplasty along with concha bullosa turbinoplasty was collected and the patients were telephonically contacted to record their symptom improvement.

**Results:** Details of nineteen patients who underwent concha bullosa turbinoplasty with septoplasty were studied, mean age of the patients was 31.26 years and the mean follow up period was 22 months. All patients had improvement in symptoms with most completely asymptomatic, the others had mild to moderate symptoms.

**Conclusions:** Concha bullosa turbinoplasty as an adjunct to septoplasty does alleviate the symptom of nasal obstruction.

**Keywords:** Concha bullosa, Septoplasty, Turbinoplasty

### INTRODUCTION

Septoplasty is a commonly performed surgery for patients presenting with nasal obstruction due to deviated nasal septum and has reported success rate of around 70%.<sup>1-3</sup> Intermittently it is noted that in spite of a good septal surgery, patients complain of persisting nasal obstruction which could be due to unaddressed nasal valve problems or turbinate issues including concha bullosa, presence of polyps or concomitant allergic rhinitis.<sup>1</sup>

Middle turbinate concha bullosa is a term used for pneumatised middle turbinate. The prevalence of concha bullosa is around 35% in patients investigated with computed tomography scan of the paranasal sinus (CT

PNS) for sinus disease.<sup>4</sup> Concha bullosa is known to cause crowding in the middle meatus, thereby impeding the ventilation of the osteomeatal complex. It is a radiological diagnosis and is further subclassified as lamellar and bulbous based on location of pneumatisation. There have been studies to find the radiological association of deviated nasal septum with concha bullosa and impact of concha bullosa on sinusitis.<sup>4,5</sup> However, studies to investigate the effect of concomitant septal surgery with reduction of concha bullosa on nasal airway have not been investigated.

Our study aims to find the added benefits concha bullosa turbinoplasty when it is performed as an adjunct to septoplasty.

**METHODS**

A retrospective chart review was conducted at a tertiary care centre (People Tree Hospitals, Bangalore) after obtaining ethical clearance from hospital ethical committee.

Patients presenting with unilateral or bilateral nasal obstruction were investigated with outpatient endoscopy. Those with gross symptomatic deviated nasal septum (DNS) were further investigated with computerized tomography of the para nasal sinuses (CT PNS). The hospital database was analysed and data of all the patients who underwent septoplasty with concha bullosa turbinoplasty between October 2016 and September 2019 was collected. Electronic notes were reviewed for all patients. Details of patient demographics and operative procedures were noted down. Inclusion criteria was all patients who underwent septoplasty with concha bullosa turbinoplasty (lateral lamellar resection or crushing the concha bullosa).

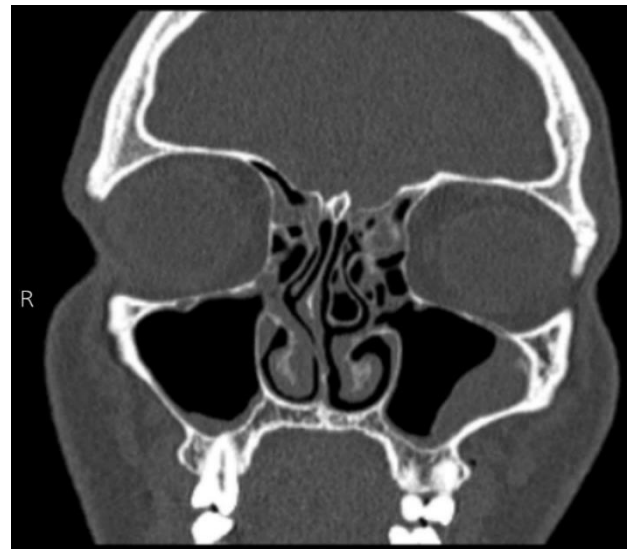
Exclusion criteria were those who underwent other adjunct procedures like adenoidectomy or extensive functional endoscopic sinus surgery with septoplasty.

All patients were operated under general anaesthesia. The DNS was corrected with standard septoplasty preserving as much of cartilage as possible.

Once the septal deviation was corrected the large concha was corrected by endoscopic lateral lamellar excision or crushing of the concha (in 2 cases). After infiltrating the middle turbinate, incision was made over the anterior end of the turbinate, the lateral bony part of the concha was carefully separated and removed up to the posterior end

of the middle turbinate with microdebrider or trucat forceps. In 2 patients the concha was gently crushed with Blakesley forceps to recreate a wider middle meatus. Nasal pack was placed for 24 hours and removed on the first postoperative day. They were reviewed after a week and at 6 weeks to reassess symptoms or to release any wet synechiae.

Long term results were assessed by a well validated nasal outcome questionnaire called the NOSE (nasal obstruction and symptom evaluation) scale (Table 1). Results were tabulated and data analysed. Microsoft excel 2010 was used for tabulation of data.



**Figure 1: CT image showing concha bullosa of the left middle turbinate.**

**Table 1: NOSE scale.<sup>6</sup>**

Characteristic	Not a problem	Very mild problem	Moderate problem	Fairly bad problem	Severe problem
Nasal congestion/stuffiness	0	1	2	3	4
Nasal blockage/obstruction	0	1	2	3	4
Trouble breathing through nose	0	1	2	3	4
Trouble sleeping	0	1	2	3	4
Unable to get enough air through during exertion	0	1	2	3	4

**RESULTS**

Nineteen patients who had nasal symptom with deviated nasal septum and evidence of concha bullosa on CT scan were included in the study (Figure 1). All patients underwent concha bullosa turbinoplasty with septoplasty. Mean age of the patients was 31.26 years and the mean follow up period was 22 months (minimum of 3 months). Three of these patients were not available for the 24 months follow up and were excluded from the study. They were available for only 6 weeks follow up and were

symptomatically better at that appointment. These were excluded from the study.

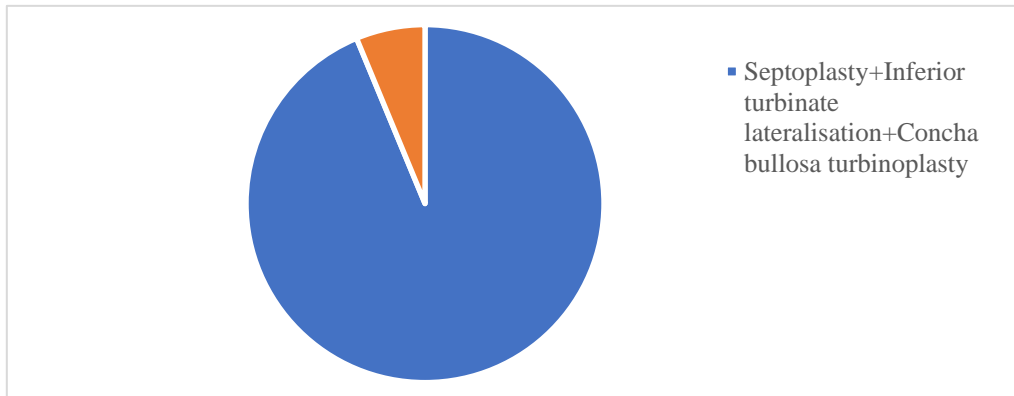
Of the 16 patients who were included in the study, 15 had septoplasty with concha bullosa turbinoplasty and inferior turbinate lateralisation. One patient had septoplasty, inferior turbinate lateralisation, concha bullosa turbinoplasty and barbed wire pharyngoplasty as part of sleep apnea surgery. Patients were interviewed with NOSE outcome scale (Table 1).

All patients had improvement in symptoms with 10 patients completely asymptomatic (NOSE score of 0). Two patients had moderate symptoms (NOSE score 8),

four patients had mild symptoms with NOSE score 4. No complications were seen in any of the patients including those missed for follow up (Table 2).

**Table 2: Outcome of NOSE score.**

Post op avg NOSE score	Number of patients	Interpretation
8	2	Moderate symptoms
4	4	Mild symptoms
0	10	Asymptomatic



**Figure 2: Distribution of adjunct procedures.**

**DISCUSSION**

**Synopsis of key findings**

Our study results show that addressing the co existent concha bullosa in septal surgery improves nasal airway significantly. The success rates of the septal surgery are variable, ranging from 65 to 85 percent.<sup>1,7-9</sup> The cause of failure can be many, including improper technique, missed diagnosis such as allergic rhinitis, valve problems and turbinate issues like hypertrophied turbinates or concha bullosa.<sup>1</sup>

Concha bullosa is an anatomical variant characterised by pneumatisation of the turbinate and it commonly occurs in the middle turbinate.<sup>10</sup> The prevalence of concha bullosa is about 35%.<sup>11,12</sup> Although most ENT surgeons perform an outpatient endoscopy of the nose to look for synchronous pathology, the most common obstructive pathology which could be missed is the concha bullosa. This is best identified on a computed tomography scan of paranasal sinuses and is hence a radiological diagnosis.

**Comparisons with other studies**

The passage of air through the nose is very complex. Studies of nasal airway show that more flow passes around the middle meatus rather than the inferior meatus.<sup>13</sup> A study by Simmen et al showed that major flux of airflow was through the middle meatus with very little air flow along the nasal floor.<sup>14</sup> Traditionally, most ENT surgeons perform a concomitant surgery of the inferior turbinate like diathermy, turbinoplasty and rarely

turbinectomy to improve the airway. Most ENT surgeons do not request a CT scan for a diagnosis of obstructive septal deviation. This meant missing a concha bullosa whose reported incidence is almost 35%. The presence of a concha bullosa is thought to cause crowding in the middle meatus region, thereby impeding the ventilation and respiratory flow through the meatus.<sup>15</sup>

The association of nasal septal deviation with concha bullosa has been extensively studied. It has been observed that a unilateral concha bullosa or the dominant one in bilateral concha bullosa is associated with contralateral deviation of nasal septum.<sup>11,16</sup> The causative role of concha bullosa in chronic rhinosinusitis is a topic of debate, so is its role in mucociliary clearance and rhinogenic headache.<sup>11,12,16,18,19</sup>

There is no consensus on the exact indications of concha bullosa surgery. It mainly depends on patient symptoms and clinical findings attributable to concha bullosa. Different techniques have been described for concha bullosa surgery including crushing, partial turbinectomy (medial or lateral) and complete middle turbinectomy.<sup>20</sup> The lateral partial resection of turbinate involves removing only the lateral lamella of the concha, it is widely used but the possibility of synechia formation is a disadvantage with this technique. Crushing of the concha bullosa is a fairly effective technique and can be done if the concha is not extensive. Resection of middle turbinate has been described but is not generally recommended.<sup>20</sup> In our practice we used the excision of lateral lamella and crushing techniques and found both methods equally effective in relieving patient symptoms.

### Limitations of the study

The drawback of this study is the lack of control group. However, we had 3 patients with a past history of septoplasty with no improvement in symptoms and were found to have a concha bullosa on radiological examination. A concha bullosa turbinoplasty helped to improve the nasal airway.

It is difficult to identify a concha bullosa clinically or endoscopically. It is best to assess patients with DNS with CT scan of paranasal sinuses to effectively tailor the nasal airway surgery to individual needs. Further studies are needed with a control group to clearly establish the role of enlarged concha bullosa in the management of obstructive nose.

### CONCLUSION

Concha bullosa is one of the causes for persisting nasal obstruction after septoplasty. Preoperative imaging the paranasal sinuses helps in identifying the presence of concha bullosa. Concha bullosa turbinoplasty as an adjunct to septoplasty does alleviate the symptom of nasal obstruction.

*Funding: No funding sources*

*Conflict of interest: None declared*

*Ethical approval: The study was approved by the Institutional Ethics Committee*

### REFERENCES

- Gillman GS, Egloff AM, Serrano RCM. Revision Septoplasty: A Prospective Disease-Specific Outcome Study. *Laryngoscope.* 2014;124(6):1290-5.
- Delaney SW. Evolution of the Septoplasty: Maximizing Functional and Aesthetic Outcomes *Nasal Surg. M J Otol.* 2018;1(1):4.
- Siegel NS, Gliklich RE, Taghizadeh F. Outcomes of septoplasty. *Otolaryngol Head Neck Surg.* 2000;122:228-32.
- Sazgar AA, Massah J, Sadeghi M, Bagheri A, Rasool E. The incidence of concha bullosa and the correlation with nasal septal deviation. *B-ENT.* 2008;4:87-91.
- Javadrashid R, Naderpour M, Asghari S. Concha bullosa, nasal septal deviation and paranasal sinusitis; A computed tomographic evaluation. *B-ENT.* 2014;10(4):291-98.
- Stewart MG, Smith TL, Witsell DL, Weaver EM, Yueh B, Hannley MT. Development and validation of the Nasal Obstruction Symptom Evaluation scale. *Otolaryngol Head Neck Surg.* 2004;130:157-63.
- Cantone E, Ricciardiello F, Oliva F, Corso DE, Iengo M. Septoplasty: is it possible to identify potential 'predictors' of surgical success. *Acta Otorhinolaryngol Ital.* 2018;38(6):528-35.
- Jin HR, Kim DW, Jung HJ. Common Sites, Etiology, and Solutions of Persistent Septal Deviation in Revision Septoplasty. *Clin Exp Otorhinolaryngol.* 2018;11(4):288-92.
- Illum P. Septoplasty and compensatory inferior turbinate hypertrophy: long-term results after randomized turbinoplasty. *Eur Arch Otorhinolaryngol.* 1997;254(1):89-92.
- Wadhwa S, Sharma N, Garg U, Dutta P. Concha bullosa: types and relationship with chronic sinusitis. *Int J Otorhinolaryngol Head Neck Surg.* 2017;3(3):482-5.
- Kucybala I, Janik KA, Ciuk S, Storman D, Urbanik A. Nasal septal deviation and concha bullosa - do they have an impact on maxillary sinus volumes and prevalence of maxillary sinusitis. *Pol J Radiol.* 2017;82:126-33.
- Zinreich SJ, Mattox DE, Kennedy DW, Chisholm HL, Diffley DM, Rosenbaum AE. Concha bullosa: CT evaluation. *J Comput Assist Tomogr.* 1988;12:778-84.
- Zhao K, Jiang J. What is normal nasal airflow: A computational study of 22 healthy adults. *Int Forum Allergy Rhinol.* 2014;4(6):435-46.
- Simmen D, Scherrer JL, Moe K, Heinz B. A Dynamic and Direct Visualization Model for the Study of Nasal Airflow. *Arch Otolaryngol Head Neck Surg.* 1999;125(9):1015-21.
- Rawi ANH, Uthman AT, Abdulhameed E, Nuaimi AS, Seraj Z. Concha bullosa, nasal septal deviation, and their impacts on maxillary sinus volume among Emirati people: A cone-beam computed tomography study. *Imaging Sci Dent.* 2019;49(1):45-51.
- Stallman JS, Lobo JN, Som PM. The incidence of concha bullosa and its relationship to nasal septal deviation and paranasal sinus disease. *AJNR Am J Neuroradiol.* 2004;25(9):1613-8.
- Calhoun KH, Waggenspack GA, Simpson CB, Hokanson JA, Bailey BJ. CT evaluation of the paranasal sinuses in symptomatic and asymptomatic populations. *Otolaryngol Head Neck Surg.* 1991;104(4):480-3.
- Mehta R, Kaluskar SK. Endoscopic turbinoplasty of concha bullosa: Long term results. *Indian J Otolaryngol Head Neck Surg.* 2013;65(2):251-4.
- Cantone E, Castagna G, Ferranti I, Cimmino M, Sicignano S, Rega F, et al. Concha bullosa related headache disability. *Eur Rev Med Pharmacol Sci.* 2015;19(13):2327-30.
- Ahmed EA, Hanci D, Utun O. Surgical techniques for the treatment of concha bullosa: A systematic review. *Otolaryngol Open J.* 2018;4(1):9-14.

**Cite this article as:** Venkataramani N, Sachidananda R, Vasista SR. Turbinoplasty of concha bullosa: a useful adjunct in improving nasal airway. *Int J Otorhinolaryngol Head Neck Surg* 2020;6:878-81.