

Original Research Article

Primary nasal rhinosporidiosis - a ten year multicentre experience: what we know?

S. Rajendran¹, S. Shanmuga Ashok^{2*}, Thalapathy Ramkumar¹

¹Department of ENT, Upgraded Institute of Otorhinolaryngology, Madras Medical College and RGGGH, Chennai, Tamil Nadu, India

²Department of ENT, Government Medical College, Omandurar Block B, Chennai, Tamil Nadu, India

Received: 04 January 2020

Revised: 18 January 2020

Accepted: 20 January 2020

*Correspondence:

Dr. S. Shanmuga Ashok,

E-mail: sivaashok@yahoo.com

Copyright: © the author(s), publisher and licensee Medip Academy. This is an open-access article distributed under the terms of the Creative Commons Attribution Non-Commercial License, which permits unrestricted non-commercial use, distribution, and reproduction in any medium, provided the original work is properly cited.

ABSTRACT

Background: Rhinosporidiosis is a disease caused by *Rhinosporidium seeberi* that affects the mucous membranes primarily. Nose is the commonest organ to be involved. The authors of this paper with more than ten years of experience across various institutions in Tamil Nadu have analysed their cases and have found out that posterior lip of valve of hasner in the inferior meatus to be the site of attachment in primary nasal rhinosporidiosis irrespective of the endemicity of the region.

Methods: This is a prospective study of seventy eight cases of primary rhinosporidiosis over a period of ten years (February 2009 to December 2019). Recurrent cases, those who did not come for follow up and who were operated under local anesthesia were not included in this study. All the patients (45) were subjected to endoscopic surgery for excision of the rhinosporidiosis under general anesthesia after informed written consent and sent for histopathological examination.

Results: Most common age group being 25 to 50 years with male preponderance and the common site of occurrence is the posterior lip of valve of Hasner in the inferior meatus with seasonal variation with O+ve blood group preponderance. Most common clinical presentation is unilateral nasal obstruction.

Conclusions: Rhinosporidiosis is hyperendemic in Tiruvarur and Thiruvannamalai. The posterior lip of valve of hasner is the commonest site of attachment. Correct identification of the site of attachment and surgical excision with cauterisation prevents its recurrence.

Keywords: Primary nasal rhinosporidiosis, Valve of hasner, Inferior meatus

INTRODUCTION

Rhinosporidiosis is chronic granulomatous inflammatory disease caused by *Rhinosporidium seeberi*. It has been recently classified as an aquatic protistan parasite. Tamil Nadu is endemic region for this condition. In this state southern districts like Kanyakumari, Ramanathapuram, Madurai, Sivagangai and Tiruvarur district is considered hyperendemic.¹ The authors have worked in various institutions across the state of Tamil Nadu like

Thiruvarur, Thiruvannamalai, Vellore and Chennai, have vast experience in treating rhinosporidiosis. Various studies have mentioned the inferior meatus, inferior turbinate, nasal floor, nasal septum as the primary site of attachment of rhinosporidiosis.²

The aim of the study was to describe the demographic distribution, clinical presentation and site of attachment of primary nasal rhinosporidiosis in various districts of Tamil Nadu over the period of ten years.

METHODS

This is a prospective study of seventy-eight cases of primary rhinosporidiosis over a period of ten years (February 2009 to December 2019) in various tertiary care centres in Tamil Nadu (Tiruvarur, Thiruvannamalai, Vellore and Chennai). Recurrent cases were excluded. Ten patients who did not come for follow up after one year were not included when deriving the final results. Patients who were operated under local anesthesia were not included in this study. All the patients (45 patients) were subjected to endoscopic surgery for excision of the rhinosporidiosis under general anesthesia after informed written consent. Correct size Endo tracheal tube with appropriate cuff pressure inflation was done by anesthetist. Under direct visualization the throat was packed with saline soaked ribbon gauze pack by the surgeon. With 0 degree nasal telescope the nose was decongested with one in thousand dilution adrenaline pack, taking care not to create microabrasion and trauma. After two minutes of decongestant packing, the inferior meatus was packed with adrenaline soaked ribbon gauze following gentle push of the inferior turbinate towards the nasal septum taking care not to injure the mucosa. The region of valve of Hasner was visualised and the site of attachment on the posterior lip of valve of Hasner was cauterised with bipolar diathermy in low voltage setting to prevent charring and block to the valve. Once the procedure is complete the inferior meatus is again decongested and visualized for any remanant, inferior canaliculus was flushed with saline and the patency of nasolacrimal duct was confirmed. In patients with very large rhinosporidiosis Mass cutter- shaver device was used to morselize the rhinosporidiosis, taking diligence not to create mucosal damage. This maneuver is important to remove the rhinosporidiosis through the involved nose and not remove through the oral cavity. This prevents uninvolved areas from getting into contact with rhinosporidiosis. Brief demographic and clinical data of patients were collected for this study.

RESULTS

In the forty-five cases thirty-nine were males and six females. Most of the patients belongs to Tiruvarur and Thiruvannamalai districts (Figure 1). All patients gave history of bathing in ponds in which animals like bullocks and buffalo too had access. Males in the age group of twenty-five to fifty were the commonest to get infected (Figure 2). Unilateral nasal obstruction being the most common clinical presentation (Figure 3). Posterior lip of valve of Hasner in the inferior meatus (Figure 4) and (Figure 5) was the site of attachment in primary nasal rhinosporidiosis in our study. During the dry season in Tiruvarur and Tiruvannamalai district when all ponds have dried, the incidence was reduced (Figure 6). Most commonly O+ve blood group individuals were affected (Figure 7). Histopathologically presence of sporangia and numerous endospores seen with hematoxylin-eosin stains

confirms the diagnosis (Figure 8). Rhinosporidiosis is aquatic protistan parasite and cannot cultured in vitro.

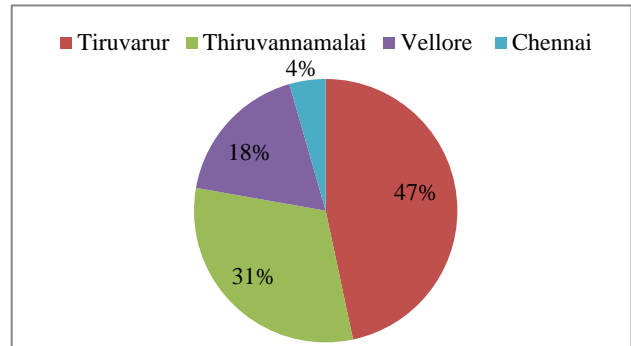


Figure 1: Demographic distribution of patients.

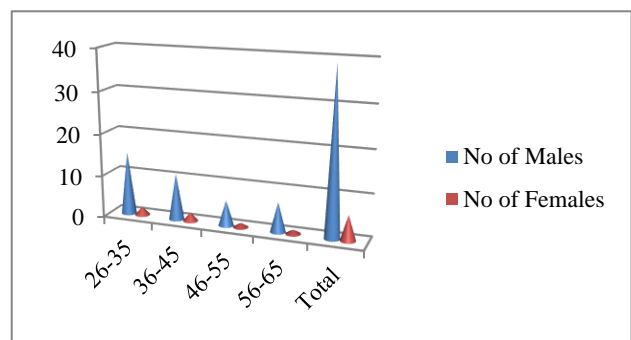


Figure 2: Distribution of patients according to age and sex.

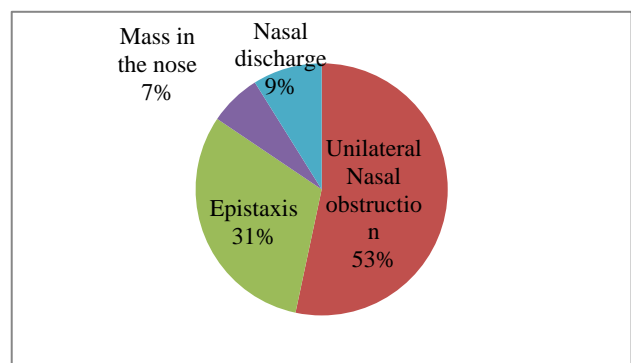


Figure 3: Clinical presentation.

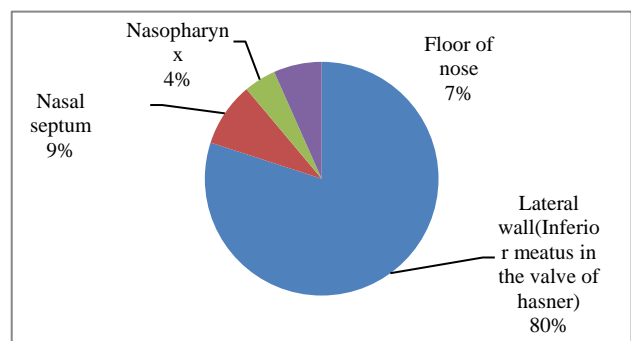


Figure 4: Site of attachment in the nose.

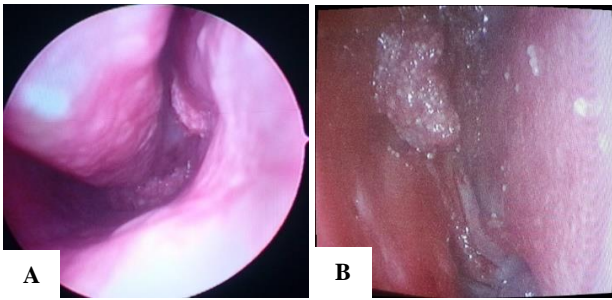


Figure 5 (A and B): Endoscopic view showing the site of attachment in the valve of Hasner.

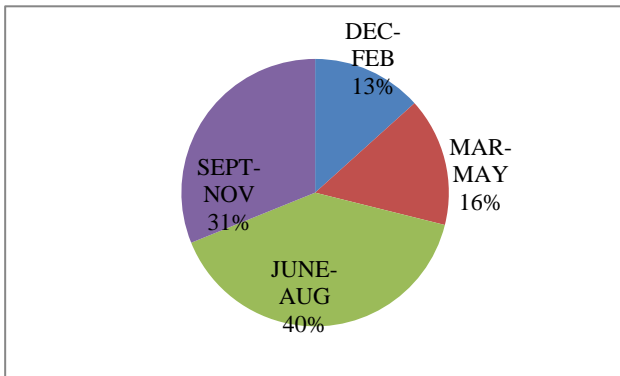


Figure 6: Distribution of patients according to months of the year.

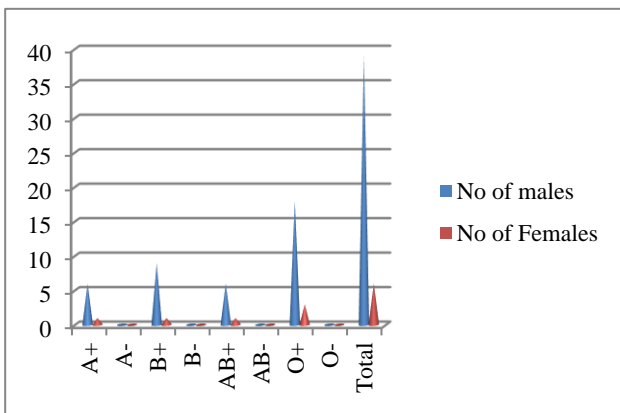


Figure 7: Distribution among various blood groups.

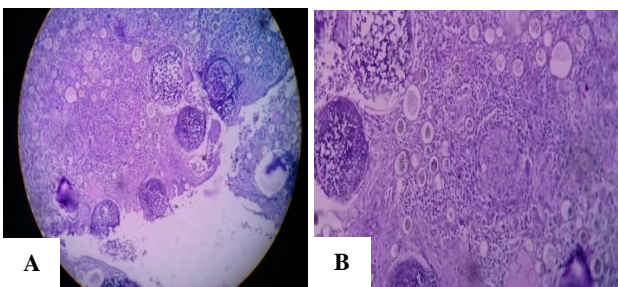


Figure 6 (A and B): (H&E, 10X and 40X) showing many thick walled sporangia with many endospores.

DISCUSSION

Rhinosporidiosis is a chronic granulomatous disease of the upper respiratory tract and it is characterized by formation of polypoid masses. This disease is endemic in India and Sri Lanka. In Tamil Nadu particularly some districts like Tiruvarur and Ramanathapuram are hyperendemic.

Total 45 cases were studied over the period of ten years. Most common age group being 25 to 50 years with male preponderance. Study by Arsecularatne et al, and Kutty et al, also found the maximum number of cases in the age-group 21 to 30 years with male preponderance.^{2,3}

Most of the affected individuals shared common thing is bathing in the ponds in which buffalos, cows and other farm animals had access. Study by Karthikeyan et al, found the same.⁴

Most of the patients presented with unilateral nasal obstruction followed by nasal bleeding.⁴ Similar results found in studies conducted by Guru et al, and Bandyopadhyay et al.^{5,6}

The most common site involved is nasal mucosa followed by nasopharynx, oropharynx, tracheobronchial tree, esophagus, conjunctiva and ears.⁷ Cutaneous and visceral involvement occurs following disseminated disease. For the first time the posterior lip of valve of Hasner has been found to be the most common site of attachment in primary nasal rhinosporidiosis followed by nasal septum, nasopharynx and floor of nose.

Most common blood group involved in our study is O+ve. Similar results found in Sinha et al.⁸

CONCLUSION

Rhinosporidiosis is hyperendemic in Tiruvarur and Thiruvannamalai. Rhinosporidiosis affect individuals who take bath in ponds in which farm animals have access. Rhinosporidiosis is more common when migratory birds roost in the ponds. For the first time the posterior lip of valve of Hasner has been found to be the most common site of attachment in primary nasal rhinosporidiosis. Correct identification of the site of attachment and surgical excision with cauterisation prevents its recurrence. Postoperative medical therapy with dapsone has limited role. Some precautions like avoidance of bathing in ponds and domestic purposes helps to reduce the incidence.

Funding: No funding sources

Conflict of interest: None declared

Ethical approval: Not required

REFERENCES

1. Babu S, Anuradha A, Chandra S, Kashyap B. Nasal rhinosporidiosis with oropharyngeal extension. *Ann Nigerian Med.* 2011;5:24-7
2. Arseculeratne SN. Recent advances in rhinosporidiosis and *Rhinosporidium seeberi*. *Indian J Med Microbiol.* 2002;20:119-31.
3. Kutty MK, Shridharan T, Mathew KT. Some observation on rhinosporidiosis. *Am J Med Sci.* 1963;246:695-701.
4. Karthikeyan P, Vijayasundaram S, Pulimoottil DT. A Retrospective Epidemiological Study of Rhinosporidiosis in a Rural Tertiary Care Centre in Pondicherry. *J Clin Diagn Res.* 2016;10(5):MC4-8.
5. Guru RK, Pradhan DK. Rhinosporidiosis with special reference to extra nasal presentation. *J Evol Med Dent Sci.* 2014;22(3):6189-99.
6. Bandyopadhyay SN, Jana U, Bandyopadhyay G, Majhi TK, Sen S, Das S, et al. Rhinosporidiosis: various presentations and different sites. *Bengal J Otolaryngol Head Neck Surg.* 2015;23(2):48-56.
7. Satyanarayana C, Rhinosporidiosis with a record of 255 cases, *Acta Otolaryngol.* 1960;51:348-66.
8. Sinha A, Phukan JP, Bandyopadhyay G, Sengupta S, Bose K, Mondal RK, Choudhuri MK. Clinicopathological study of rhinosporidiosis with special reference to cytodagnosis. *J Cytol.* 2012;29:246-9.

Cite this article as: Rajendran S, Ashok SS, Ramkumar T. Primary nasal rhinosporidiosis - a ten year multicentre experience: what we know?. *Int J Otorhinolaryngol Head Neck Surg* 2020;6:343-6.