

Case Report

Cavernous haemangioma of maxillary sinus: a camouflaged presentation

S. Santiyamadhi^{1*}, R. Komathi¹, Noraini Mohamad², Ing Ping Tang³

¹Department of Otorhinolaryngology, ²Department of Pathology, Sarawak General Hospital, Jalan Hospital, Kuching, Malaysia

³Department of Otorhinolaryngology, Faculty of Medicine and Health Sciences, University Malaysia Sarawak, Jalan Datuk Mohammad Musa, Kota Samarahan, Sarawak, Malaysia

Received: 27 December 2019

Revised: 14 January 2020

Accepted: 17 January 2020

***Correspondence:**

Dr. S. Santiyamadhi,

E-mail: santiya.dr@gmail.com

Copyright: © the author(s), publisher and licensee Medip Academy. This is an open-access article distributed under the terms of the Creative Commons Attribution Non-Commercial License, which permits unrestricted non-commercial use, distribution, and reproduction in any medium, provided the original work is properly cited.

ABSTRACT

Cavernous haemangioma of the nose and paranasal sinuses is a rare lesion which often misdiagnosed preoperatively. It is slow growing and locally destructive due to pressure effect thus simulating the features of a malignant lesion. In this case we presented a 64-year-old gentleman whom presented with bleeding from right alveolar ridge. On examination revealed a friable mass of 2×2 cm which bled on contact mimicking malignant lesion. CT scan revealed a heterogeneously enhancing soft tissue lesion with surrounding bone remodelling which made it difficult to rule out malignancy. The tissue punch biopsy suggestive of inflammatory myofibroblastic tumour, however unable to rule out low grade malignancy. With the dilemma of making an accurate preoperative diagnosis, we proceeded with right total maxillectomy as to provide a total resection of the tumour. Postoperative histopathological examination confirmed to be cavernous haemangioma. This camouflaged presentation of cavernous haemangioma was a challenge in the decision making to provide the best curative treatment. Cavernous haemangioma of maxillary sinus is a complex entity, thus diagnosing this lesion is in grey area for the surgeons. A high index of suspicion combined with the radiological finding is crucial in deciding the treatment option in such camouflaged presentations. An analytical and suspicious mind combined with histopathological and radiological examination is pertinent for confirmation of the diagnosis.

Keywords: Cavernous, Myofibroblastic, Camouflaged

INTRODUCTION

Hemangioma is a proliferation of blood vessels that creates a mass resembling a neoplasm. They may occur in any vascularized tissue including skin, subcutaneous tissue, muscle and bone.¹ Hemangiomas of the nose and paranasal sinuses are rare and often misdiagnosed as malignant conditions. Although soft tissue hemangioma is common in head and neck, they occur infrequently in paranasal sinuses. Origin of cavernous hemangioma is debatable. According to Shira and Guernsey it is a true

benign neoplasm as a result of endothelial proliferation which differentiates into blood vessels.² Sometimes it can produce destruction of adjacent bones, making it difficult to differentiate from more common malignant tumours. Clinically and radiologically they are difficult to diagnose. Due to scarcity of cases, a comprehensive clinical picture is lacking, and the imaging results are often non-specific, increasing the chances of misinterpretation with the more common sinonasal disorders. The correct diagnosis of cavernous hemangioma in this case is relatively challenging due to

similar histological findings of myofibroblastic tumour until surgery was performed. Management of hemangiomas and treatment of choice depends of several factors, age of the patient, signs and symptoms, size and extent of the lesions as well as their clinical characteristics. Some hemangiomas may be present without any sign or symptom.³ We report a rare presentation of cavernous hemangioma of the maxillary sinus which mimics features of malignancy, on the other hand tissue biopsy from the maxillary sinus suggested myofibroma, a benign tumour. Although computed tomography scan showed enhancing soft tissue lesion within the tumour, the substantial bony wall dehiscence and remodeling made it difficult to differentiate from other malignant lesions. Therefore, unable to get a definite diagnosis prior to the surgery.

CASE REPORT

An elderly male patient aged 64 years presented with a chief complaint of bleeding from right alveolar ridge associated with bulge at the right upper jaw for one-year duration. Clinical examination revealed a friable mass about 2×2 cm over the right alveolar ridge. Nasal endoscope showed suspicious mass from right maxillary sinus compressing the right nasal cavity. A complete medical examination showed no other significant findings.

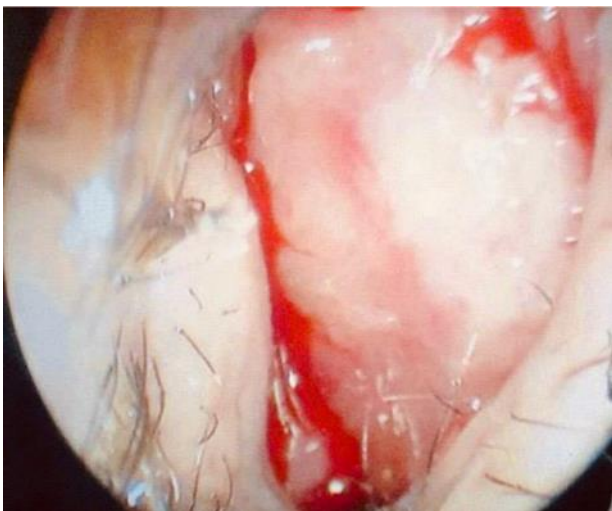


Figure 1: Endoscopic view of the mass occluding the right nasal cavity.
Note the bleeding around the lesion.

Computed tomography scan of paranasal sinuses revealed a heterogeneously enhancing soft tissue lesion measuring 4.7×5.2×4.0 cm occupying the entire right maxillary sinus with surrounding remodelling of its bony wall. Few areas of bony wall dehiscence with soft tissue extra-maxillary extension into the right masseter space and intraorally to hard palate. The overlying skin is thickened.

Histopathological examination of the right maxillary sinus biopsy stained with smooth muscle actin and

vimentin are positive, the histological features are of a benign spindle cell tumour suggestive of inflammatory myofibroblastic tumour. However unable to rule out a low-grade malignancy. The patient was scheduled for right total maxillectomy and placement of healing plate under general anaesthesia. A firm well encapsulated tumour of right maxillary sinus, involving whole maxillary bone was resected in total. After the lesion was resected placement of healing plate with circumzygomatic wiring was done.

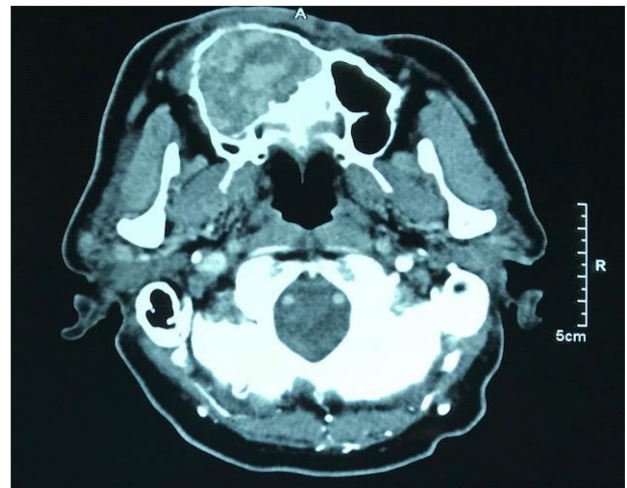


Figure 2: Coronal bone window showing right maxillary soft tissue lesion with surrounding remodelling of its bony wall.

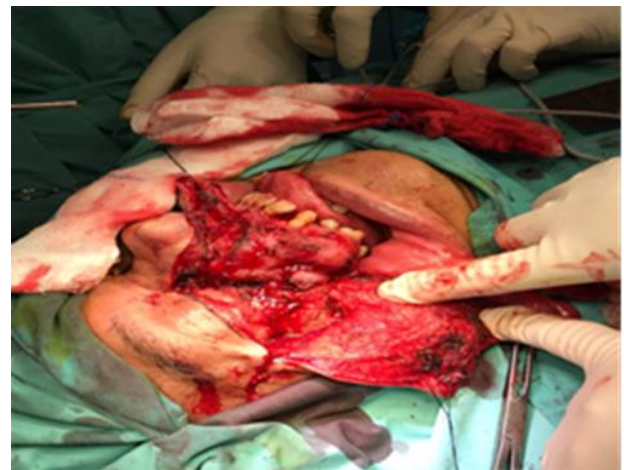

Figure 3: Intraoperative finding of right maxillary tumour measuring about 6×7×4 cm.

Microscopic examination showed multiple dilated and slit like thin walled vascular channels. These vascular channels are lined by single layered endothelial cells, without nuclear atypia seen. Findings show features of cavernous hemangioma.

The patient recuperated well with no further bleeding in the immediate and late post-operative period and no recurrence in six months follow up period.

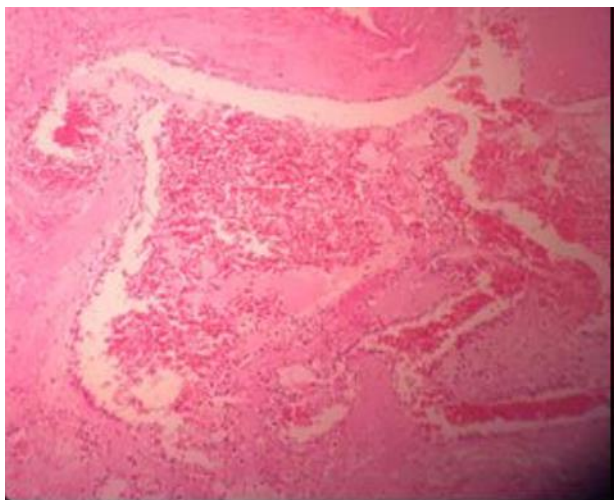


Figure 4: Multiple dilated vascular channels with fibrin depositions consistent with cavernous hemangioma (under 20X magnification).

DISCUSSION

Primary hemangioma is a rare benign bone tumor. It constitutes 0.5% to 1.0% of all bone tumors.^{4,6} Hemangiomas of the head and neck are benign vascular lesions, and although they are common in these regions but it occurs rarely in paranasal sinuses. Fu et al reported in his study 85 cases of vascular tumors of which angiofibroma was the most number of occurring tumour followed by capillary haemangioma and 5 cases of cavernous haemangioma and the other vascular tumours. Microscopically these tumours are composed of multiple, large, thin walled, dilated blood-filled vascular channels lined by flat endothelial cells. He also stated that 4 cases were successfully treated by local excision and 1 case was treated by radiotherapy.⁷ Cavernous hemangioma of paranasal sinuses may be misinterpreted as malignancy due to the aggressive behaviour. Signs and symptoms include nasal obstruction, rhinorrhea and occasionally facial swelling which is asymptomatic. Due to scarcity of cases, there is no generalized clinical picture or uniform management protocol for cavernous hemangioma thereby increasing the chance of misdiagnosis.⁸ In our case, examination revealed swelling at the right alveolar ridge which bleeds on contact mimicking neoplasm associated with swelling of right cheek which was gradually increasing in size. Histopathologically, the biopsy suggested myofibroblastic tumour, a benign condition. CT showed heterogeneously enhancing soft tissue lesion occupying the entire right maxillary sinus with surrounding remodelling of its bony wall. Due to the aggressive behaviour of the tumour which mimicked malignancy, surgical resection was done. Histopathological findings of the surgical specimen

suggestive of a cavernous hemangioma, a benign vascular tumour.

CONCLUSION

In conclusion, cavernous haemangioma of maxillary sinus is a complex entity, thus diagnosing this lesion is in grey area for the surgeons. It may be mistaken for a locally aggressive neoplasm. A high index of suspicion combined with the radiological finding is crucial in deciding the treatment option in such camouflaged presentations. An analytical and suspicious mind combined with histopathological and radiological examination is pertinent for confirmation of the diagnosis.

Funding: No funding sources

Conflict of interest: None declared

Ethical approval: Not required

REFERENCES

1. Vikas D, Sunil Y, Anita D, Francis A. Cavernous Hemangioma-Uncommon Presentation in Zygomatic Bone; a case report. J Craniofac Surg. 2012 ;23(2):607-9.
2. Dhiman NK, Jaiswara C, Kumar N, Patne SC, Pandey A, Verma V. Central cavernous hemangioma of mandible: Case report and review of literature. Natl J Maxillofac Surg. 2015;6(2):209-13.
3. Whear NM. Condylar hemangioma-a case report and review of the literature. Br J Oral Maxillofac Surg, 1991;29:44-7.
4. Dickins JRE. Pathologic quiz case 1. Arch Otolaryngol. 1978;104:58-60.
5. Marshak G. Hemangioma of the zygomatic bone. Arch Otolaryngol. 1980;106:581-2.
6. Sasagawa Y, Akai T, Yamamoto K, Masuoka T, Itou S, Oohashi M, et al. Multiple cavernous hemangiomas of the skull associated with hepatic lesions. Neurol Med Chir (Tokyo). 2009;49:162-6.
7. Fu YS, Perzin KH. Non-epithelial Tumors of the Nasal Cavity, Paranasal Sinuses, and Nasopharynx. A Clinicopathologic Study. I General Features Vascular Tumors. 1974;33(5):1275-88.
8. Dutta M, Kundu S, Barik S, Banerjee S, Mukhopadhyay S. Mucosal Cavernous Hemangioma of the Maxillary Sinus. Arch Iranian Med. 2015;18(2):130-2.

Cite this article as: Santiyamadhi S, Komathi R, Mohamad N, Tang IP. Cavernous haemangioma of maxillary sinus: a camouflaged presentation. Int J Otorhinolaryngol Head Neck Surg 2020;6:397-9.