

## Case Report

# Granular cell tumour (Abrikossoff's tumor) in the ENT region: about two cases report

Mimouni Hicham<sup>1\*</sup>, Touihmi Safaa<sup>1</sup>, Rkain Ilham<sup>1,2</sup>

<sup>1</sup>Department of Otorhinolaryngology, Head and Neck Surgery, University Hospital, Tangier, Morocco

<sup>2</sup>Faculty of Medicine and Pharmacy of Tangier, Abdelmalek Saadi university, Tétouan, Morocco

**Received:** 19 December 2019

**Accepted:** 31 January 2020

### \*Correspondence:

Dr. Mimouni Hicham,

E-mail: [mimouhi@gmail.com](mailto:mimouhi@gmail.com)

**Copyright:** © the author(s), publisher and licensee Medip Academy. This is an open-access article distributed under the terms of the Creative Commons Attribution Non-Commercial License, which permits unrestricted non-commercial use, distribution, and reproduction in any medium, provided the original work is properly cited.

## ABSTRACT

Granular cell tumors also named Abrikossoff's tumors, are very rare soft tissue tumors, almost always benign and can affect different organs. The head and neck location are the most common, particularly skin and the tongue. The larynx is concerned in 7 to 10% of the cervico-facial locations of this tumor (1, 2). In this article we report two cases of Abrikossoff's tumor. The first case is of a 27 years old man, with no particular features in his medical history, who consulted for dysphonia, progressively evolving over 6 months. The nasal endoscopy found a whitish nodular lesion of almost 20 mm of diameter, involving the middle third of the right vocal cord. The tumor was removed under microlaryngoscopy. The second case is of ten days old newborn female, who presented dyspnea and dysphagia while breastfeeding, the clinical exam showed a round shaped lesion of 4 cm of diameter, implanted in the dorsal face of the tongue. The lesion was rooted out with electrocautery under general anesthesia. Anatomopathology examination with Immunohistochemistry of both patients' surgical samples confirmed the diagnosis of granular cell tumor. The Origin of the Abrikossoff's tumors is uncertain. The recent immunohistochemical studies are orienting toward neurogenic origin. These tumors usually arise in the adult, between the ages of 20 to 60 years old, with female predominance. The symptoms are diverse and non-specific, only the anatomopathological examination permits to confirm the diagnosis. The main issues of these tumors are the compression of the adjacent structures and the high risk of recurrence, which requires long term surveillance.

**Keywords:** Surgery, Abrikossof, Granular cell tumor, Head and neck

## INTRODUCTION

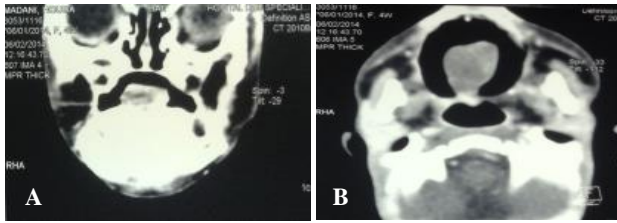
Granular cell tumors are a very uncommon, they generally appear in head and neck in about 50% of cases and the larynx is concerned in 10% of these cases. Multiples locations of the tumor are possible.<sup>1,2</sup>

The symptomatology is non-specific. Direct laryngoscopy objectives a mass mostly located in the posterior third of the vocal cords. The diagnosis is histological completed with immunohistochemical study.<sup>3</sup> The treatment of these tumors is based on the surgical removal. The high risk of recurrence requires long term surveillance.

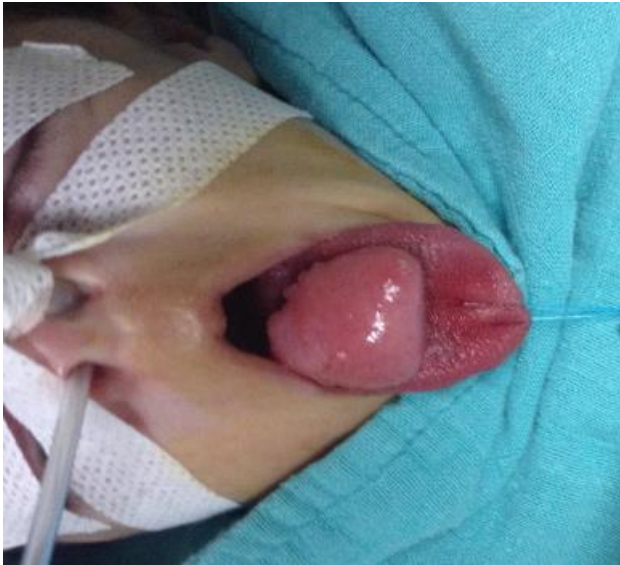## CASE REPORT

### Case 1

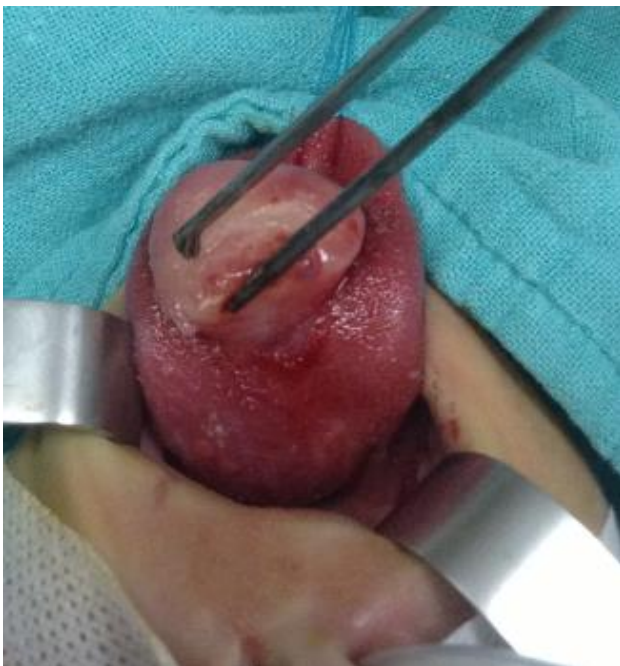A 27 years old male, with no particular features in his medical history, presented severe dysphonia, progressively evolving over 6 months, with no other associated signs. The nasal endoscopy objective whitish nodular and regular mass, non-infiltrating, non-bulging, occupying the middle third of the right vocal cord. The vocal cord's mobility was preserved. No adenopathies were founded in the cervical examination. The mass was removed with endolaryngeal microsurgery under general anesthesia.



**Figure 1 (A and B):** Computed tomography scan with axial and coronal section, showing pedunculated tissular process infiltrating the dorsal face of the tongue.



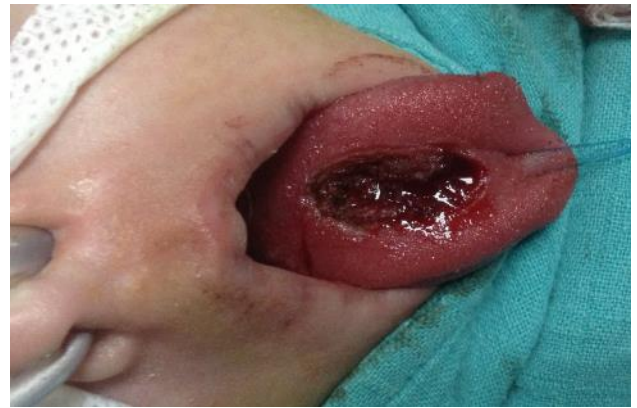**Figure 2:** Superior view of the tongue showing the mass occupying the of the dorsal of the tongue.



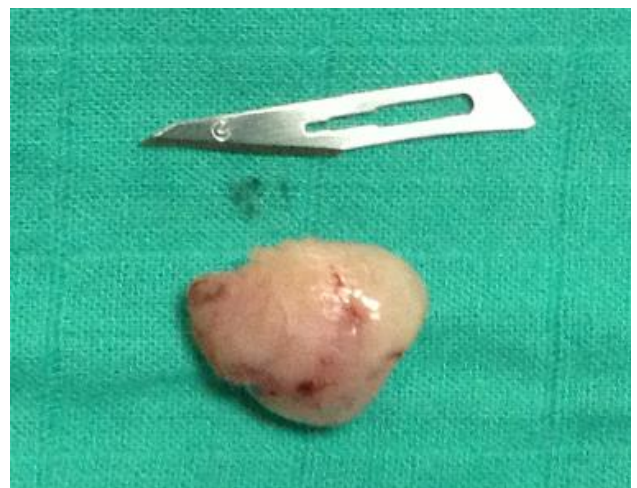**Figure 3:** Pedunculated mass of the dorsal face of the tongue

## Case 2

The second case is of a ten days old newborn female, who presented dyspnea and dysphagia while breastfeeding, the clinical exam showed 4 cm spherical shaped lesion, implanted on of 2 cm surface area of the dorsal face of the tongue. The lesion was painless, firm in consistency and recovered with normal mucosa.



**Figure 4:** Superior view of the tongue after surgical removal of the tumor with large margin excision.

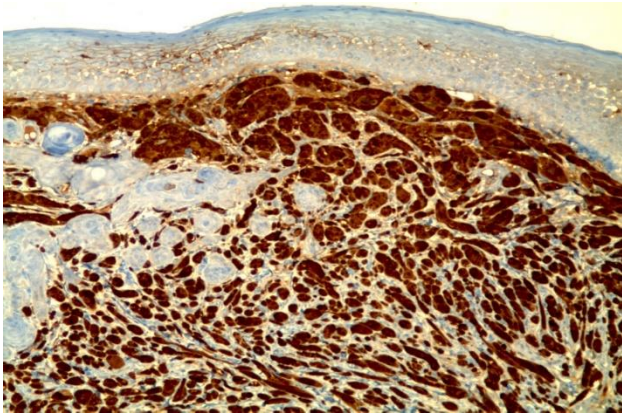


**Figure 5:** The surgical specimen after excision.

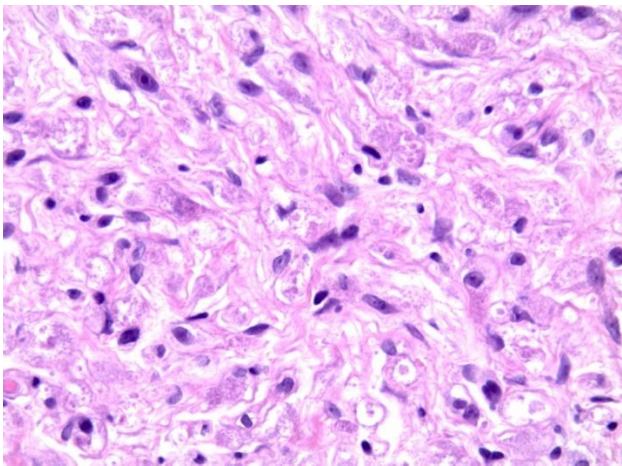
Computed tomography scan (CT) of the head and neck with coronal and axial sections had shown pedunculated tissular process infiltrating the dorsal face of the tongue. The lesion was rooted out with electrocautery under general anesthesia with nasotracheal intubation.

The histological examination and immunohistochemistry study of the surgical samples showed granular cell tumor with pseudoepitheliomatous hyperplasia of the squamous epithelium in both cases. The markers PS100 and CD68 used in the immunohistochemical examination were also positives; which confirms the diagnosis of granular cell tumor. The post-operative follow up was simple, the dysphonia has disappeared.





**Figure 6: PAS staining of the cytoplasmic granules.**



**Figure 7: Histological aspect of the granular cells (HE 400X).**

## DISCUSSION

Abrikossoff's tumors are very uncommon, mostly benign, it has been found that they may develop on different organs, especially in the upper aero digestive tract (tongue, lips, cheeks, the palate, the buccal floor), they can also be either mono or multi-focal. In fact, patients with Abrikossoff's tumor have 4 to 10% chances to develop another synchronous or metachronous lesion, regardless of the location.<sup>2,3</sup>

Initially called granular cells myoblastoma by Abrikossif in 1962, given the presumed muscular origin of the tumor, the cytochemical and microscopic recent studies have shifted to neurogenic origin.<sup>1</sup> Multiples etiopathogenic, degenerative, inflammatory, regenerative and congenital theories have been developed, but none of them confirmed.<sup>5</sup>

These tumors mostly occur between the second and the sixth decades of life, with female predominance. The symptomatology depends on the location of the tumor, such as dysphonia, stridor, hemoptysis, earache, coughing

and also dyspnea in the extended form, but still, they are non-specific.<sup>1,3,6</sup>

On the clinical ENT examination and direct laryngoscopy, 1 to 2 cm of diameter lesion is observed, this lesion is usually regular, non-encapsulated, firm, sessile, recovered with normal white or grey mucosa, more often located in the posterior third of the vocal cords but can also be seen in the arytenoid folds, the false cords, the retrocricoid region when the larynx is concerned with the tumor. In the pediatric forms, the tumor is often located in the supralottic region, or mostly in the tongue.

The diagnosis is generally done post-operatively through the histological examination of the surgical sample; it can't be evoked before, unless the patient has already been diagnosed with Abrikossoff's tumor in another location.<sup>7</sup>

Histologically, the tumor is distinguished with the presence of polymorphic and polyhedral cells with granulomatous and acidophilic cytoplasm. The nucleuses are small sized with condensed, central and vesicular chromatin. The cytoplasmic granules are positively marked with Sudan black Band PAS (periodic acid-Schiff).<sup>3,5</sup> Myelinated nerve fibers are often found in these tumors.

Malignant forms of this tumor could be seen in 1 to 2% of the cases. Some clinical features permit to bring up the diagnosis of the malignant form of the tumor, such as the size: if superior to 4 cm, rapid evolvement and the infiltration of the adjacent tissues. Histological specifications for tumor's malignancy also exist, such as nuclear polymorphism, mitosis, necrosis and cellular atypia.<sup>5,9</sup>

The surgical removal with laser is the therapy of choice in the laryngeal forms of the tumor. Cold instruments and electrocautery are used in other locations (the tongue). The resection margins is 2 cm. The risk of recurrence is from 8 to 21%. Partial laryngectomy could be an option for the extended forms. Radiotherapy and chemotherapy not only have no room in the therapeutic strategy, but may even represent a risk of malignant transformation of the tumor.<sup>4,10</sup>

## CONCLUSION

The natural history of these tumors have long been unknown, given their rarity, rigorous and long term surveillance is highly required by clinical examination and radiological assessment with an magnetic resonance Imaging.

*Funding: No funding sources*

*Conflict of interest: None declared*

*Ethical approval: Not required*

## REFERENCES

1. Sataloff RT, Ressue JC, Portell M, Harris RM, Ossoff R, Merati AL, et al. Granular Cell Tumors of the Larynx. *J Voice.* 2000;14(1):119-34.
2. Enoz M, Kiyak E, Katircioglu S, Gulluoglu M. Abrikossoff tumor of the larynx. *Acta Medica (Hradec Králové).* 2007;50(2):157-8.
3. White JB, Robert Glade, Christopher Thomas Rossi, and Steven Bielamowicz. Granular Cell Tumors of the Larynx: Diagnosis and Management. *J Voice.* 2009;23(4):516-7.
4. Lazar RH, Younis RT, Kluka EA, Joyner RE, Storgion S. Granular cell tumor of the larynx: report of two pediatric cases. *Ear Nose Throat J.* 1992;71:440-3.
5. Rejas R, Campos M, Cortes A, Pinto D, de Sousa S. The neural histogenetic origin of the oral granular cell tumor: an immunohistochemical evidence. *Med Oral Patol Oral Cir Bucal.* 2011;16:e6-10.
6. Daniels J. Granular cell tumour of tongue: A case report. *Saudi Dent J.* 2009;21:75-8.
7. Torrijos-Aguilar A, Alegre-de Miquel V, Pitarch-Bort G, Mercader-García P, Fortea-Baixaui J. Cutaneous granular cell tumor: a clinical and pathologic analysis of 34 cases. *Actas Dermosifiliogr.* 2009;100:126-32.
8. Suchitra G, Tambekar K, Gopal K. Abrikossoff's tumor of tongue: Report of an uncommon lesion. *J Oral Maxillofac Pathol.* 2014;18:134-6.
9. Haikal F, Maceira J, Dias E, Ramos-e-Silva M. Histogenesis of Abrikossoff tumour of the oral cavity. *Int J Dent Hyg.* 2010;8:53-62.
10. Barbieri M, Musizzano Y, Boggio M, Carcuscia C. Granular cell tumour of the tongue in a 14-year-old boy: case report. *Acta Otorhinolaryngol Ital.* 2011;31:186-9.

**Cite this article as:** Hicham M, Safaa T, Ilham R. Granular cell tumour (Abrikossoff's tumor) in the ENT region: about two cases report. *Int J Otorhinolaryngol Head Neck Surg* 2020;6:765-8.