

## Original Research Article

# Clinical, pathological and radiological correlation of thyroid swellings

Hetal H. Chauhan\*, R. G. Aiyer, Purva C. Shah

Department of Otorhinolaryngology and Head-Neck Surgery, Baroda Medical College and SSG Hospital, Vadodara, Gujarat, India

**Received:** 15 December 2019

**Revised:** 01 February 2020

**Accepted:** 29 February 2020

### \*Correspondence:

Dr. Hetal H. Chauhan,

E-mail: [chauhanhetal2192@gmail.com](mailto:chauhanhetal2192@gmail.com)

**Copyright:** © the author(s), publisher and licensee Medip Academy. This is an open-access article distributed under the terms of the Creative Commons Attribution Non-Commercial License, which permits unrestricted non-commercial use, distribution, and reproduction in any medium, provided the original work is properly cited.

## ABSTRACT

**Background:** The cause and type of thyroid swellings vary across geographical areas, lifestyles, and socioeconomic status of people. The incidence of palpable thyroid swellings is 4-7% out of which only 1% are malignant. Out of all thyroidectomy cases, histologically confirmed thyroid malignancy constitutes only 20%. Hence, we attempt to evaluate thyroid swellings based on clinical examination, ultrasonography (USG), Fine needle aspiration cytology (FNAC), and histopathological evidence to aide in arriving at proper diagnosis and treatment at an early stage.

**Methods:** This was a prospective observational study conducted at the SSG Hospital, Vadodara from December, 2016 to September 2017 and included 30 patients. Following preliminary examination, we performed thyroid function tests, FNAC, and USG pre-operatively. Histopathological examination of excised tissue was performed within 4-5 hours after thyroid surgery, and later, post-op complications were noted. Results were derived after appropriate statistical tests.

**Results:** 65% patients belonged to 2nd and 3rd decade with male to female ratio of 1:5 and all patients presented with an anterior neck swelling. Clinical examination was found to be 50% sensitive and 100% specific. The sensitivity and specificity of FNAC was 50% and 96% respectively while that of USG was 67% and 100% respectively. Out of 16% malignant cases, all were of papillary type. Most common post-op complication was related to wound care (3-5%).

**Conclusions:** Correlation between clinical findings, ultrasonography findings, cytology, serum investigations and histopathological examinations are to be carried out for appropriate management of thyroid swelling.

**Keywords:** Thyroid swelling, Malignancy, Fine needle aspiration cytology, Ultrasonography

## INTRODUCTION

Thyroid gland is the only endocrine gland which is amenable to direct physical examination owing to its large size and superficial location. The cause and type of thyroid swellings vary across geographical areas, lifestyles, and socioeconomic status of people. The incidence of palpable thyroid swellings is 4-7% out of which only 1% are malignant.<sup>1</sup> Out of all thyroidectomy cases, histologically confirmed thyroid malignancy constitutes only 20%.<sup>2</sup> Incidence of thyroid malignancy increases with age, history of radiation exposure, and diet

containing goitrogenic material.<sup>3</sup> In northeast India, frequent floods and changes in the course of rivers depletes the soil of iodine which is the cause for a high prevalence of goiter and thyroid swelling in the area.<sup>4</sup>

On elaborating history and clinical examination, benign swellings are slow-growing, have a smooth surface, well-defined margin, firm consistency, and are non-tender without pressure symptoms like dysphagia, voice change, and stridor. Malignant swelling, on the other hand, are rapidly growing with an uneven surface, ill-defined margins, hard consistency, are tender, and are associated with pressure symptoms. Intra-operative examination of

excised specimen involves shape, size, surface, bleeding and fixity to underlying structure. Benign swellings have smooth appearance, less bleeding and are not fixed to underlying structures. Malignant swelling is uneven, more bleeding and fixed to underlying structures. Ultrasonography (USG) of the neck is more accurate than clinical evaluation for diagnosing thyroid swellings. It is a safe and cost-effective method which can detect thyroid nodules as small as diameter of 1-3 mm. Although, it cannot accurately distinguish between benign and malignant lesion, there are certain sonographic criteria like micro calcification, irregular margins, and hypo echogenicity that suggest malignancy. Fine needle aspiration cytology is the safest, most reliable, accurate, and cost-effective way to evaluate thyroid nodules and thus, has become the gold standard method available for distinguishing between benign and malignant thyroid swellings.<sup>3</sup> It provides accurate cytological information which guides us to prepare a definitive management plan with high sensitivity and specificity approaching to 96%. Bethesda system of classifying FNAC results facilitates an effective communication between pathologists and clinicians, guides patient management, and increases the number of malignancies found in post-thyroidectomy specimens. However, certain malignancies like follicular carcinoma of thyroid require histopathological examination as the diagnosis depends on lympho-vascular and capsule invasion.

In subtotal thyroidectomy, the surgeon leaves a small thyroid remnant in situ to preserve thyroid function, thereby preventing lifelong thyroid hormone supplementation therapy. It has been practiced for more than a century for benign multinodular goitre to reduce compressive symptoms and take care of cosmetic concerns without causing major morbidity and postoperative hypothyroidism due to which the patient need not take lifelong supplemental or replacement levothyroxine. However, recurrence with this procedure is as high as 50% on long-term follow-up. Total thyroidectomy is the procedure that removes entire thyroid gland while in near total thyroidectomy, the surgeon removes both lobes except for a small amount of thyroid tissue (on one or both sides) in the vicinity of recurrent laryngeal nerve and superior parathyroid glands. Total thyroidectomy is safe and effective for benign multinodular goitre in the hands of an expert surgeon. Near-total thyroidectomy is a relatively safer procedure with similar efficacy. For malignant lesions, subtotal thyroidectomy is associated with higher recurrence, inadequate treatment and therefore, provides little significant advantage of being safer as compared to total thyroidectomy. Major complications of total thyroidectomy are permanent hypoparathyroidism and vocal cord paralysis. The acceptable rate of these crucial complications is between 1% to 2%.<sup>1</sup> Most studies suggest that the incidence of hypocalcaemia is higher after total thyroidectomy than after subtotal thyroidectomy, but the incidence of other complications like transient recurrent laryngeal nerve palsy, and post-

operative haematoma is not significantly different between the two procedures. When a recurrent thyroid swelling is being resected, bilateral recurrent laryngeal nerve injury must be avoided. All patients who require reoperation should undergo preoperative laryngoscopy evaluation, since as many as 20% may have existing permanent recurrent laryngeal nerve palsy and up to 32% of these are known to be asymptomatic and also for medico-legal purpose.<sup>2</sup>

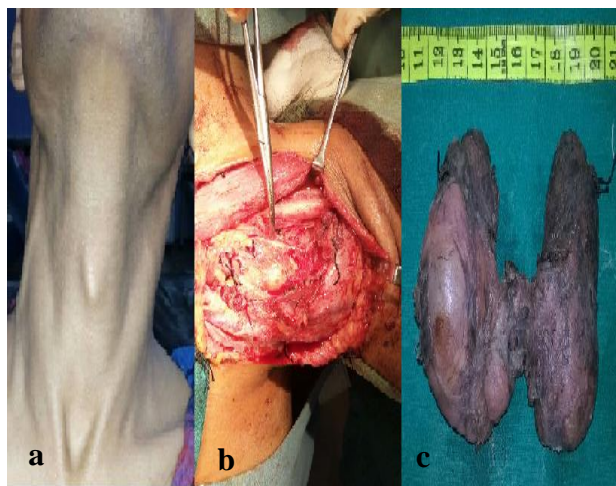
In this study, we aim to correlate the history, clinical examination, ultrasonography of the neck, fine needle aspiration cytology reports with the post-operative histopathology reports. We will also correlate the intra-op findings with pre-operative and post-operative diagnosis.

## METHODS

This was a prospective observational study conducted at the department of otorhinolaryngology and head-neck surgery, Baroda medical college and SSG hospital, Vadodara from December 2016 to September 2017. We included all patients (n=30) who came to the outpatient and in-patient department of the department of otorhinolaryngology and head-neck surgery and those who were referred from departments of surgery and emergency medicine with complaint of midline neck swelling. Swellings other than thyroid swelling as elicited by clinical examination and those thyroid swellings which did not require surgical management were excluded from the study.

After obtaining approval from the institutional ethics committee and taking a well-informed written consent, all participants were assessed for detailed demographic profile, noting the detail of patient's bio data, where the patient resides, his detailed habits and if any member of family has goitre. The duration of the swelling was noted in all the cases, which represents the time from when the patient first noticed the swelling and note the exact duration of appearance of swelling. Details to evidence the presence of thyrotoxicosis or hypothyroidism was asked in all patients. Any other associated ear, nose & throat complaints were noted. Clinical examination done with detailed inspection (shape, size, surface, margin, movement of swelling with deglutination and movement of swelling with protrusion of tongue.) and palpation (shape, size, surface, margin, temperature, tenderness, fixity or mobility over underlying structure) of the swelling. All the patients were submitted to routine investigations like complete blood counts, blood sugar, renal and liver function tests, coagulation profile, HIV, HBsAg, chest X-ray, ECG and blood grouping were performed according to the patient's profile. The special blood investigations including serum T3, serum T4, and serum TSH for thyroid function test in all patients. Total calcium and ionized calcium done in case of thyroid malignancy and plan to do total thyroidectomy. Ultrasound of neck was done in supine position with a pillow under the neck to hyperextend it. Transverse,

longitudinal and multiple angled and oblique projections were taken. Several features were kept in mind like number, size, site, echogenicity, vascularity, calcification, and lymphadenopathy. This was done in all cases. Fine needle aspiration cytology with hypodermic needle of 23G 1½ inch needle and syringe was taken in all cases after doing ultrasonography to avoid collapsing of cyst after fine needle aspiration cytology. The slides were sent for cytological examination for all cases. Clinical photography done preoperatively as well as during surgery and postoperative specimen (Figure 1). In all cases indirect laryngoscopy done. Surgery was done as per the diagnosis made. For malignant lesions, we performed total thyroidectomy while in benign lesions, lobectomy, isthmectomy, hemi-thyroidectomy, subtotal, and near-total thyroidectomy was done according to the decision of the head surgeon. All patients were euthyroid at the time of surgery which helped in avoiding intraoperative complications of thyroid storm and haemorrhage. Patient was given general anaesthesia in supine position with extended neck. After making a skin crease incision and elevating the superior and inferior flaps, we exposed the gland and examined the tumor with its vascular involvement. Following mobilization and dissection of the upper pole, dissection of tumor done with part of gland depending on the type of lesion. Care was taken to protect recurrent laryngeal nerve and parathyroid glands. After wound closure, excised specimen sent for histopathological examination in 40% formalin solution within 4-5 hours of the procedure. In case of malignant nodule on histopathological report, patient was referred to GCRI, Ahmedabad for further treatment. Post-operative follow-up done after 3 months.



**Figure 1: a) Pre-operative anterior neck swelling, b) Intra-operative image of total thyroidectomy, and c) Post-operative specimen of multi nodular goitre with benign nodules in right lobe and isthmus.**

Sample size (n=30) of this study was calculated on the basis of hospital records of the previous year for the number of thyroid surgeries performed in the department of otorhinolaryngology and head-neck surgery. All the

data was analysed using appropriate statistical tests. A p-value of <0.05 was considered significant assuming normal distribution of dependent variables and randomization of independent variables. Qualitative data was expressed in percentage and quantitative data was expressed as mean±standard deviation. Data was entered with the help of microsoft word and excel and analysed by Medcalc software version 12.5.0.

## RESULTS

In our study, 30 patients participated ranging from 16 years of age to 62 years out of which 15 patients (50%) belonged to the age group of 20-40 years. Male to female ratio was 5:1 with 25 males and 5 females. All patients (100%) presented to us with complaint of swelling in front of the neck out of which 80% presented within the first year of appearance of symptoms. There were no associated complaints of change in the quality of voice, difficulty in swallowing, and difficulty in breathing. 10 patients (33.33%) used non-iodised salt while the others were using iodised salt. In majority of cases, there was no specific etiological factor for thyroid swelling. On clinical examination, we detected 5 (16.67%) benign cystic thyroid disease, 1 (3.33%) multi-nodular goitre, 3 (10%) thyroid carcinoma, and 21 (70%) as benign thyroid disease. On USG examination, we detected 26 (86.67%) nodules as benign and 4 (23.33%) as malignant (Table 1). On FNAC, we diagnosed 26 (86.67%) lesions as benign and 4 (13.33%) lesions as malignant out of which we identified 3 as papillary carcinoma and 1 lesion as follicular neoplasm. Intra-operative excision of thyroid lesion followed by histopathological examination of the cut sections was taken as the gold standard of diagnosing malignancy in thyroid nodules and this showed 24 (80%) benign and 6 (20%) malignant lesions all of which were papillary carcinoma of thyroid. We found variable echogenicity in all benign lesions out of which 15 lesions (57.69%) were hypoechoic, 2 lesions (7.69%) hyperechoic, 4 lesions (15.38%) anechoic, and the rest (19.23%) were isoechoic. Two of the four malignant lesions were hyperechoic and the remaining two were hypoechoic. We did not find any anechogenicity or calcification in the malignant nodules (Table 2). Sensitivity and specificity of clinical examination in detecting malignant lesion was found to be 50% and 100% respectively. We clinically diagnosed 27 nodules as benign and 3 as malignant and hence, one malignant thyroid swelling was falsely labelled as benign. Sensitivity and specificity of USG in detecting malignant lesion is 67% and 100% respectively. On USG examination, we detected 26 nodules as benign and 4 as malignant which shows that 2 malignant nodules were falsely diagnosed as benign on USG. Sensitivity and specificity of FNAC in detecting malignant lesion is 50% and 96% respectively. With FNAC, we diagnosed 3 malignant lesions correctly while the other 3 were misdiagnosed as benign. On the other hand, 23 out of the 24 benign thyroid swellings were correctly diagnosed as

benign while the remaining follicular adenoma was misinterpreted as follicular neoplasm.

**Table 1: Difference between different diagnostic modalities in differentiating benign and malignant lesions.**

	Benign lesions N (%)	Malignant lesions N (%)
<b>Clinical examination</b>	27 (90)	3 (10)
<b>Ultrasonography</b>	26 (76.67)	4 (23.33)
<b>FNAC</b>	26 (76.67)	4 (23.33)
<b>Histopathology</b>	24 (80)	6 (20)

**Table 2: Distribution of benign and malignant lesions depending on their appearance on USG.**

	Benign lesions N (%)	Malignant lesions N (%)
<b>Hyperechoic</b>	2 (7.69)	2 (50)
<b>Hypoechoic</b>	15 (57.69)	2 (50)
<b>Anechoic</b>	4 (15.38)	0
<b>Isoechoic</b>	5 (19.23)	0
<b>Calcification</b>	0	0
<b>Total</b>	26 (100)	4 (100)

We measured the sensitivity and specificity of clinical examination, USG, and FNAC taking histopathological findings as the gold standard (Table 3).

**Table 3: Sensitivity and specificity of clinical examination, USG, and FNAC in diagnosing malignant thyroid nodules.**

	No. of patients		Total
<b>Sensitivity and specificity of clinical examination</b>			
Positive	True positive 3	False positive 0	3
Negative	False negative 3	True negative 24	27
Total	6	24	30
<b>Sensitivity and specificity of ultrasonography examination</b>			
Positive	True positive 4	False positive 0	4
Negative	False negative 2	True negative 24	26
Total	6	24	30
<b>Sensitivity and specificity of FNAC in detecting malignant nodules</b>			
Positive	True positive 3	False positive 1	4
Negative	False positive 3	True negative 23	26
Total	6	24	30

**Table 4: Ultrasonography findings in benign and malignant thyroid nodules.**

Study	Total cases	Echogenicity hypoechoic N (%)	Hyperechoic N (%)	Anechoic N (%)	Isoechoic N (%)	Calcification N (%)
<b>Benign nodules</b>						
Solbiati et al <sup>10</sup>	356	41.0	50.9	8.1	-	15.0
Brkljiscic et al <sup>11</sup>	289	30.4	24.5	18.9	30.4	-
Present study	24	50	6.67	13.33	30	-
<b>Malignant nodules</b>						
Solbiati et al <sup>10</sup>	139	75.5	2	-	23.2	17
Brkljiscic et al <sup>11</sup>	70	78	2	-	23.2	-
Present study	6	50	50	-	-	-

In this study, surgery was done in all 30 cases of thyroid swellings. We performed hemi-thyroidectomy in 19 patients (63.33%) of which 2 cases were papillary thyroid carcinoma. Subtotal thyroidectomy was performed in 5 (16.67%) cases of which one was a malignant lesion while others were benign.

Total thyroidectomy was performed in 4 (13.33%) four cases out of which 3 were diagnosed as papillary thyroid carcinoma and one was done for disease clearance in benign thyroid disease involving the isthmus and both lobes. Radical neck node dissection was performed in 3 cases papillary thyroid carcinoma. In one patient with benign nodule limited to the isthmus, we performed isthmusectomy. In a patient with past history of right



sided hemi-thyroidectomy who presented to us with a benign swelling in the remaining thyroid lobe, we performed completion thyroidectomy. Patients with PTC in whom total thyroidectomy was not done were put under close follow-up and were referred to GCRI, Ahmedabad for post-operative radioactive iodine treatment. All patients with papillary thyroid carcinoma were put on suppressive therapy of levo-thyroxine 100 to 150 microgram/day to suppress the endogenous TSH production.

## DISCUSSION

In comparison to other studies, this study had 53.33% patients belonging to the age group of 2<sup>nd</sup>, 3<sup>rd</sup>, 4<sup>th</sup> decade as compared to Venkatachalapathy study which had 69% patients, Kapur et al study with 75% patients, and Bhansali study with 70% patients in the same age group.<sup>5-7</sup> It may be because of less number of patients compared to other studies. In the present study, female to male ratio for thyroid swelling was 5: 1 which was comparable to other studies Venkatachalapathy study had a female to male ratio of 2.2:1, Kapur et al study with 2:1, and Bhansali study with a ratio of 7:2.<sup>5-7</sup> According to previous studies, the most common type of malignancy in patients with thyroid nodule is papillary thyroid carcinoma.<sup>5</sup> The present study showed 100% incidence of papillary carcinoma among the patients with malignant thyroid swelling. On USG examination, we found variable echogenicity in all benign lesions. Hypoechoogenicity was the most common feature in Solbiati et al study and in present study. On the other hand, Brkljacic et al study found that hyperechogenicity was the most common feature in benign lesions.<sup>9,10</sup> Evidence of calcification was seen in Brkljacic et al study in 15% of benign lesions, while in our study, no calcification was seen in benign lesions.<sup>10</sup> In the present study, 2 malignant lesions were hyperechoic and 2 were hypoechoic whereas no anechogenicity was seen in the malignant nodules. Hypoechoogenicity was seen in 78% of malignant nodules in Brkljacic et al and in 75.5% of malignant nodules in Solbiati et al (Table 4).<sup>9,10</sup> Comparing the sensitivity (Sn) and specificity (Sp) of the FNAC in our study (Sn=50%, Sp=96%) with FNAC report of other studies, we found that FNAC specificity in our study was comparable to other studies but its sensitivity in the current study was lower than the previous studies - Gardner et al (Sn=65%, Sp=91%), Hawkins et al (Sn=86%, Sp=95%), Khafagi et al (Sn=87%, Sp=72%), Caplan et al (Sn=91%, Sp=99%), and Gharib et al (Sn=98%, Sp=99%).<sup>11-15</sup>

## CONCLUSION

Management of thyroid swelling is still a controversial topic because surgical procedure for each histologic type of thyroid lesion varies from simple enucleation to total thyroidectomy combined with radical dissection of cervical lymph nodes. Clinical evaluation alone is not

sufficient for diagnosis and management. Correlation between clinical findings, ultrasonography findings, cytology, serum investigations and histopathological examinations were carried out for appropriate management of thyroid swelling in present study.

*Funding: No funding sources*

*Conflict of interest: None declared*

*Ethical approval: The study was approved by the Institutional Ethics Committee*

## REFERENCES

1. Vinci DL. Leonardo on the human body. New York: Dover Publications; 1925.
2. Graves RJ. Clinical lectures - part II. London Medical and Surg J. 1838;7:516-7.
3. Basedow VCA. Exophthalmus durch Hypertrophie des Zellgewebes in der Augenhöhle. Wochenschr. Ges Heilk. 1840;6:197-220.
4. Garrison, Fielding H. An introduction to the history of medicine with medical chronology, bibliographic data and test questions. 4th ed, Philadelphia: WB Saunders Company; 1929.
5. Venkatachalapathy TS, Sreeramulu PN, Maddineni RK. A prospective study of clinical, sonological and pathological evaluation of thyroid nodule. J Thyroid Dis Therapy. 2012;1:2.
6. Kapur MM, Sarin R, Karmakar MG, Sarda AK. Solitary thyroid nodule. Indian J Surg. 1982;44:174-79.
7. Bhansali SK. Solitary nodule in the thyroid gland; experience with 600 cases. Indian J Surg. 1982;44:547-61.
8. Gharib H. Fine needle aspiration biopsy of thyroid nodules: advantages, limitations and effect. Mayo Clinic Proceedings. 1994;69(1):44-9.
9. Solbiati L, Charboneau JW, Osti V, James EM, Hay ID, Rumack CM, et al. The thyroid gland. Diagnostic Ultrasound. St Louis, Missouri: Elsevier Mosby; 2005;3(1):735-70.
10. Brkljacic B, Cuk V, Brzac TH, Zigman BZ, Brkljacic DD, Drinkovic I. Ultrasonic evaluation of benign and malignant nodules in echographically multinodular thyroids. J Clinical Ultraso. 1994;22:71-6.
11. Gardner HA, Ducatman BS, Wang HH. Predictive value of fine needle aspiration of the thyroid in classification of follicular lesions. Cancer. 1993;71(8):2598-603.
12. Hawkins F, Bellido D, Bernal C, Rigopoulou D, Valdepenas RMP, Lazaro E, et al. Fine needle aspiration biopsy in the diagnosis of thyroid cancer and thyroid disease. Cancer. 1987;59(6):1206-9.
13. Khafagi F, Wright G, Castles H. Screening for thyroid malignancy: the role of fine needle aspiration biopsy. Medi J Austra. 1988;149(6):302-3.

14. Caplan RH, Strutt PJ, Kiskan A. FNAB of thyroid nodules. *Wisconsin Medi J.* 1991;90(6):285-8.
15. Gharib H, Goellner JR. Fine-needle aspiration biopsy of the thyroid: an appraisal. *Annals Int Medi.* 1993;118(4):282-9.

**Cite this article as:** Chauhan HH, Aiyer RG, Shah PC. Clinical, pathological and radiological correlation of thyroid swellings. *Int J Otorhinolaryngol Head Neck Surg* 2020;6:708-13.