

Case Report

Case report on hereditary haemorrhagic telangiectasia

Stuti Mathur*, Akanksha Saberwal, Yogesh Dabholkar, Bhavika Verma

Department of ENT, DY Patil Hospital, Maharashtra, India

Received: 01 December 2019

Revised: 11 January 2020

Accepted: 13 January 2020

***Correspondence:**

Dr. Stuti Mathur,

E-mail: omvirendra1993@gmail.com

Copyright: © the author(s), publisher and licensee Medip Academy. This is an open-access article distributed under the terms of the Creative Commons Attribution Non-Commercial License, which permits unrestricted non-commercial use, distribution, and reproduction in any medium, provided the original work is properly cited.

ABSTRACT

Osler Weber Rendu disease also known as hereditary haemorrhagic telangiectasia (HHT) is a rare autosomal dominant disorder by the presence of multiple arteriovenous malformations (AVMs) that lack intervening capillaries resulting in direct connections between arteries and veins. A 70-year-old male patient known case of hypertension; Indian origin was brought to the emergency department of our hospital with complaints of severe epistaxis. An attempt was made initially to control bleeding by ice compressions and finally anterior and posterior nasal packing was done. He gave history of similar episodes in the past often accompanied with hematemesis and melena on and off since childhood gastroduodenoscopy was done to rule out cause for hematemesis which showed multiple telangiectasia in fundus, body and antrum of stomach and first part of duodenum establishing the diagnosis of HHT. Patient with Osler-Weber-Rendu disease may present with uncontrolled bleeding. Resuscitation along with hemostasis is the main stay of treatment. As the bleeding occurs from malformed vessels coagulation tests are normal. Management include blood transfusion, antifibrotics and surgical hemostasis.

Keywords: Hereditary haemorrhagic telangiectasia, Antifibrotics, Gastroduodenoscopy, Hemostasis

INTRODUCTION

Osler Weber Rendu disease also known as hereditary haemorrhagic telangiectasia (HHT) is a rare autosomal dominant disorder by the presence of multiple arteriovenous malformations (AVMs) that lack intervening capillaries resulting in direct connections between arteries and veins.¹⁻³ Epistaxis is the most common symptom of HHT and mucocutaneous telangiectasia the most common sign.¹

CASE REPORT

A 70-year-old male patient known case of hypertension, Indian origin was brought to the emergency department of our hospital with complaints of severe epistaxis. An attempt was made initially to control bleeding by ice compressions and finally anterior and posterior nasal

packing was done. He gave history of similar episodes in the past often accompanied with hematemesis and melena on and off since childhood. On presentation his blood pressure was 100/60 mmhg, pulse was 121/min.

Routine blood work which revealed Hb 6.0 gm/dl and PCV 22%. In totality, 3 pints of packed cells and 5 units of FFP were transfused in conjunction with Tranexamic acid infusion. Exploration using nasal endoscopy followed by cauterisation under general anaesthesia was performed. On nasal endoscopy multiple telangiectatic patches were found around the nasal septum and middle turbinate.

Gastroduodenoscopy was done to rule out cause for hematemesis which showed multiple telangiectasia in fundus, body and antrum of stomach and first part of duodenum establishing the diagnosis of HHT. CT brain was done to rule out cerebral AVMs.

Newer drugs like bevacizumab as medical line of management and septodermoplasty was advised.

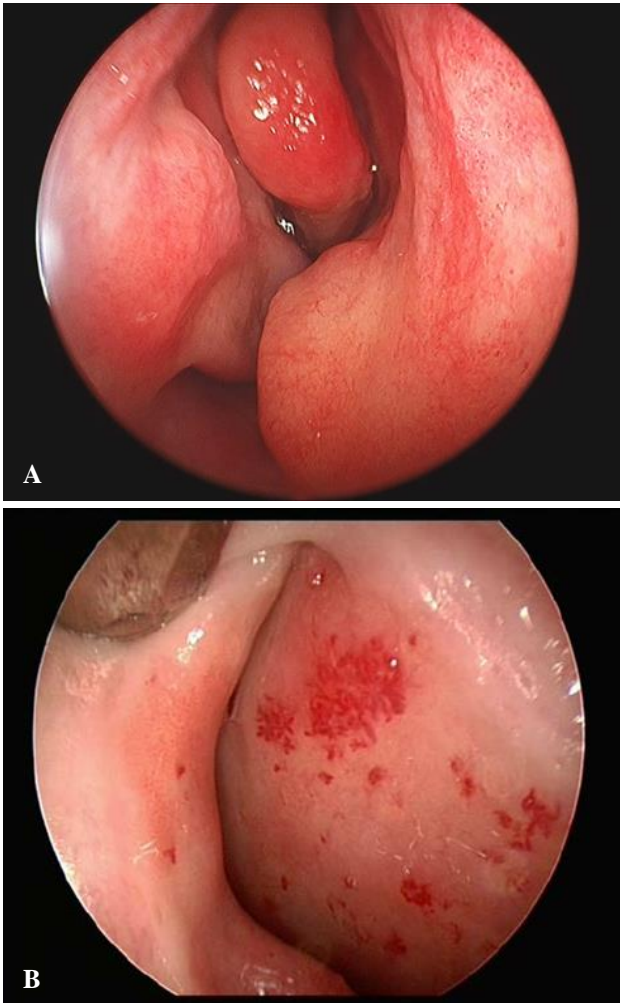


Figure 1 (A and B): Diagnostic endoscopic images of nasal mucosa of 70 year old male showing telangiectasis.

DISCUSSION

HHT is a rare systemic fibro vascular dysplasia with incidence varying from 1 in 5,000 to 10,00. HHT is manifested by mucocutaneous telangiectasis and AVMs in different parts of body.^{1,2} Lesions can affect the nasopharynx, central nervous system, lung, liver, and spleen, as well as the urinary tract, gastrointestinal tract, conjunctiva, trunk, arms, and fingers. Impaired signalling of transforming growth factor- β or bone morphogenesis protein as well as vascular endothelial growth factor has been attributed as the primary cause of HHT.^{5,6} The diagnosis of HHT is made clinically significant bleeding from gastrointestinal tract may occur in 25% patients older than 60 years and may increase with age. Pulmonary involvement in the form of AVMs may be present in 75% HHT1 and 44% HHT2 patients with pulmonary involvement are at high risk of developing cerebral thrombotic and embolic events including stroke,

brain abscess, or transient ischemic attacks due to right-to-left shunting Cerebral AVMs may be present 15-20% HHT1 and 1 to 2% HHT2 patients and may present with seizure, headache or intracranial haemorrhages. Pre-existing anemia due to recurrent bleeding is common and sudden decompensation may lead to heart failure. Uncontrolled bleeding may occur from skin lesions during patient positioning and transport.^{7,8} Epistaxis may lead to aspiration of blood into trachea causing pulmonary edema. Sudden change in blood pressure may cause bleeding from AVMs anywhere in the body, most serious of which is from cerebral AVM. Gastric distension may occur from ingested blood and may cause reflux and aspiration during induction. Male and females are equally affected. Classic triad of presentation include telangiectasis of the skin and mucous membranes, epistaxis, and a positive family history. Epistaxis may be present in upto 95% whereas skin lesions account for 75-90% of presentations.⁹

In stable patients, posted for elective surgery, angiogenesis inhibitor or hormone therapy should be considered in selected patients to reduce perioperative bleeding. Careful history and physical examination may indicate any systemic involvement and standard radiological imaging with angiography may be performed to search for haemangiomas in brain, lung, gastrointestinal tract, nose and paranasal sinuses. In unstable patient presenting with severe bleeding focus should be directed to simultaneous resuscitation and hemostasis.⁸ Blood transfusion forms the mainstay of volume resuscitation in severely volume depleted patient. Epistaxis should be controlled with tight nasal packing immediately followed by cauterisation of bleeding vessels and dermoplasty if required. Since bleeding does not result from a defect in coagulation cascade, but from the malformed vascular structures, platelet or plasma transfusions are of no use and reserved only to supplement the loss. Antifibrinolytics including tranexamic acid and aminocaproic acid have been used with success to control epistaxis.⁸ In addition to antifibrinolytic effects, tranexamic acid also stimulates the expression of activin receptor-like kinase (ALK)-1 and endoglin, as well as the activity of the ALK-1 or endoglin pathway.¹⁰ Intraoperatively controlled hypotension should be used to reduce bleeding.

CONCLUSION

Patient with Osler-Weber-Rendu disease may present with uncontrolled bleeding. Resuscitation along with hemostasis is the main stay of treatment. As the bleeding occurs from malformed vessels coagulation tests are normal. Management include blood transfusion, antifibrinolytics and surgical hemostasis.

Funding: No funding sources

Conflict of interest: None declared

Ethical approval: Not required

REFERENCES

1. Peery WH. Clinical spectrum of hereditary hemorrhagic telangiectasia (Osler-Weber-Rendu disease). *Am J Med.* 1987;82:989-97.
2. Guttmacher AE, Marchuk DA, White RI Jr. Hereditary hemorrhagic telangiectasia. *N Engl J Med.* 1995;333:918-24.
3. Shovlin CL, Guttmacher AE, Buscarini E, Faughnan ME, Hyland RH, et al. Diagnostic imaging pathways: development, dissemination, implementation and evaluation. *Int J Quality Health Care.* 2006;32(4):89-95.
4. Auchu H, de Chadarévian JP, Bideau A, Robert JM. Age-related clinical profile of hereditary hemorrhagic telangiectasia in an epidemiologically recruited population. *Am J Med Genet.* 1989;32:291-7.
5. Schmierer B, Hill CS. TGF beta-SMAD signal transduction: molecular specificity and functional flexibility. *Nat Rev Mol Cell Biol.* 2007;8:970-82.
6. Pau H, Carney AS, Murty GE. Hereditary-haemorrhagic telangiectasia (Osler-Weber-Rendu syndrome): otorhinolaryngological manifestations. *Clin Otolaryngol Allied Sci.* 2001;26:93-8.
7. Harries PG, Brockbank MJ, Shakespeare PG, Carruth JA. Treatment of hereditary haemorrhagic telangiectasia by the pulsed dye laser. *J Laryngol Otol.* 1997;111:1038-41.
8. Wrana JL, Attisano L, Wieser R, Ventura F, Massagué J. Mechanism of activation of the TGF-beta receptor. *Nature.* 1994;370:341-7.
9. Kjeldsen AD, Kjeldsen J. Gastrointestinal bleeding in patients with hereditary hemorrhagic telangiectasia. *Am J Gastroenterol.* 2000;95:415-8.
10. Sabbà C, Pasculli G, Lenato GM, Suppressa P, Lastella P, Memeo M, et al. Hereditary hemorrhagic telangiectasia: clinical features in ENG and ALK1 mutation carriers. *J Thromb Haemost.* 2007;5:1149-57.

Cite this article as: Mathur S, Saberwal A, Dabholkar Y, Verma B. Case report on hereditary haemorrhagic telangiectasia. *Int J Otorhinolaryngol Head Neck Surg* 2020;6:589-91.