

## Case Series

# Button battery foreign body among children: a case series

Gerald P. Sebastian<sup>1\*</sup>, Rajinidevi Kaliyan<sup>2</sup>, Pethuru Devadason<sup>3</sup>

<sup>1</sup>Department of Otorhinolaryngology, Thanjavur Medical College, Thanjavur, Tamil Nadu, India

<sup>2</sup>Department of Anaesthesiology, Govt Thiruvavur Medical College, Thiruvavur, Tamil Nadu, India

<sup>3</sup>Department of Community Medicine, Sree Mookambika Institute of Medical Sciences, Kulasekharam, Kanyakumari, Tamil Nadu, India

**Received:** 26 November 2019

**Revised:** 08 March 2020

**Accepted:** 09 March 2020

### \*Correspondence:

Dr. Gerald P. Sebastian,

E-mail: [drgerald94@gmail.com](mailto:drgerald94@gmail.com)

**Copyright:** © the author(s), publisher and licensee Medip Academy. This is an open-access article distributed under the terms of the Creative Commons Attribution Non-Commercial License, which permits unrestricted non-commercial use, distribution, and reproduction in any medium, provided the original work is properly cited.

## ABSTRACT

In children the foreign bodies are a common occurrence which may be either accidental or self-induced as a matter of habit. Various materials like metal, plastic toy parts, food matters, etc have been reported as foreign bodies. Button batteries have been reported as foreign bodies in the ear, nose and throat are very relevant and practical, due to their early chemical disintegration in contact with mucosal surface; hence, need emergency surgical intervention to avoid complications. Here, we report five cases of button batteries in the ear nose and throat at various stages of presentation with their sequelae.

**Keywords:** Button batteries, Foreign bodies, Nasal septal perforation, X-ray PNS, Leaking button battery

## INTRODUCTION

Ear, nose and throat foreign bodies in children frequently present to both general practitioners and otorhinolaryngologist. Most of the foreign bodies are non-hazardous like plastic objects, paper, coin, cotton, cereals or foam. The dangerous foreign body like button battery has the potential to cause serious sequelae if it is not removed immediately. Diagnosis is often delayed because the causative event is usually unobserved, the symptoms are nonspecific, and patients often are misdiagnosed initially. So general physicians need to have a high index of suspicion for foreign bodies in children with unexplained upper airway symptoms.<sup>1</sup>

These foreign bodies can be either in ear, nose or throat. Patients with foreign bodies in the ear are often asymptomatic, and in most of the cases are in an accidental finding.<sup>2</sup> Others may have pain, symptoms suggestive of otitis media, hearing loss, or a sense of

fullness in ear. 75 percent of patients with ear foreign bodies were younger than eight years as per the findings from several large case series.<sup>3</sup>

Nasal foreign bodies tend to be located on the floor of the nasal passage, just below the inferior turbinate, or in the upper nasal fossa anterior to the middle turbinate.<sup>4</sup> Patients often present with unilateral, foul-smelling nasal discharge. Patients may be able to expel the nasal foreign body simply by “blowing their nose” while blocking the opposite nostril.<sup>1</sup> Referral should be obtained when the foreign body cannot be easily removed or adequately visualized.

Pharyngeal and laryngeal foreign bodies should be suspected in patients with undiagnosed cough, stridor, or hoarse-ness. All pharyngeal and laryngeal foreign bodies are medical emergencies that require airway protection. Because complete airway obstruction usually occurs at the time of aspiration and results in immediate

respiratory distress, emergency intervention is essential. Diagnosis is often complicated by delayed presentation. Case reports describe foreign bodies in the throat that were misdiagnosed and treated as croup.<sup>5</sup> Thus, physicians must have a high degree of suspicion in patients with unexplained upper airway symptoms, especially in children who have a history of choking.

While beads, plastic toys, pebbles and popcorn kernels are common foreign bodies in the ears and plastic, metal pin, seeds, nuts, bones, coins, dental appliances are common in the throat (pharynx), the common foreign bodies in the nose (nasal cavities) are beads, buttons, toy parts, pebbles, candle wax, food, paper, cloth, and button batteries.<sup>1</sup>

Button batteries are nowadays very commonly used in devices such as hearing aids, electronic games, watches, digital planners and new electronic gadgets. The button battery is so called because of its shape and size. The shiny and smooth appearance of them are quite attractive and interesting to children who eagerly handle them when they are accessible.<sup>6</sup>

The common pathophysiology of complications in button battery foreign body are release of toxic substance (e.g. silver, zinc, mercury or lithium), local electrical burn- the electrical circuit completes when lodged in the aerodigestive tract and injury usually happens on the anode side of battery, electrolyte leakage from battery causing caustic injury by 45% KOH and pressure necrosis caused by impacted foreign body. Neglected or delayed management of button battery foreign body can cause the following damages in the ear, nose and throat area. In the ear, the common damages are perforation of tympanic membrane, tympanomeatal tissue damage, ossicular necrosis, middle ear mucosal damage, sensory neural hearing loss and vestibular damage.<sup>1</sup>

The complications in the nasal cavity is based on many factors. These include the time interval between insertion and removal of the foreign body, the orientation of the battery in the nasal cavity and the surface in contact with the negative pole (anode), more likely, is what causes damage, nasal septal perforations are more likely to occur when the negative terminal is in contact with the septum, nasal button battery impaction may produce mucosal turbinate and septal ulceration in as little as three to six hours, necrosis of the inferior turbinates has occurred at 24 hours and inferior meatus ulceration, saddle deformities, chondritis, atrophic rhinitis, and alar collapse may ultimately result.<sup>7</sup>

The mechanism of injury by these foreign bodies in the pharynx of these patients is related primarily to the generation of hydroxide radicals in the mucosa resulting in a caustic injury from high pH, instead of an electrical-thermal injury. Types of injuries sustained have included tracheoesophageal fistula, esophageal perforation, esophageal strictures, vocal cord paralysis from recurrent

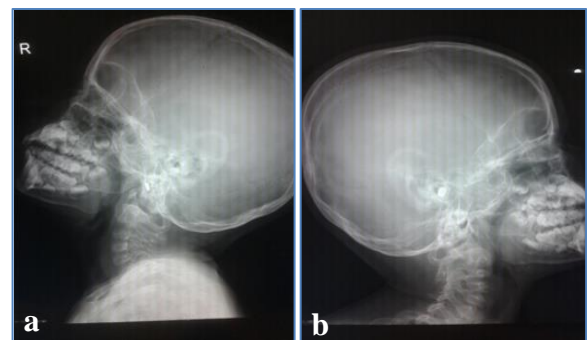
laryngeal nerve injury, mediastinitis, cardiac arrest, pneumothorax and aortoenteric fistula.<sup>8</sup>

The aims and objectives of this case series were to study the various presentations and outcomes in a series of five children that presented with button batteries in which 3 were in the nose and 1 each in ear and throat. Informed consent of these patients had been taken regarding the publication of these data in to journal article.

## CASE SERIES

### Case 1

A 6 years old boy came with complaints of accidental navigation of known foreign body (button battery) in his right ear while playing with cell phone toy with his friends. There was no history of ear ache, ear discharge, hard of hearing or any other specific ENT symptoms. There was a history of evaluation and navigation to remove the foreign body by the local ENT surgeon in which the attempt was failed. No radiographic evaluation was done there.



**Figure 1 (a and b): X-rays both mastoids Law's view showing radio opaque foreign body.**

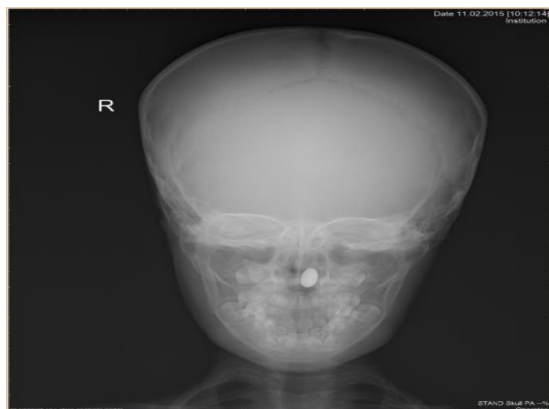On examination, the child was conscious, oriented and afebrile. His vitals were normal. On local examination of the ears, left ear was normal by clinical and otoscopic examinations. In the right ear, blood clots were there in external auditory canal (EAC). Tympanic membrane was not visualized. On probing, gritty sensation was felt. Facial nerve was intact. Nose and throat examination were clinically normal. X-ray both mastoids were taken (Figure 1) which showed radio-opaque foreign body with double rim appearance. Removal of foreign body by Jobsons probe by direct visualization was tried but failed. So, the hospitalization and evaluation done. DIL received considering the impending complication of button battery. Emergency removal of foreign body under general anesthesia done.

Under general anesthesia with head in left lateral position, removal of foreign body by endaural navigation also failed due to impaction in the EAC. Post aural incision was done and meatal flap was raised. Intact foreign body was visualized and removed. No leak of the

button battery in the surrounding tissue was observed. Tympanic membrane was then visualized end aurally and found to be intact. Post aural wound was closed in layers. Endaural medicated pack was kept. Patient extubated and shifted to ward. In the Post-operative observation, nil specific complaints were received from days 1-4. ENT examination was done and clinically normal. Facial nerve was intact. On the day 5 patient was discharged and advised for follow up visit after 7 days. On the day 15, the patient was reviewed and the ENT examination done was clinically normal.

### Case 2

A 4 years old boy was referred from an ENT practitioner for evaluation of foreign body nose. There was the history of left sided nasal obstruction, blood stained nasal discharge and foul smelling for 10 days. History of unwitnessed foreign body in left nasal cavity was there. There was no history of fever or any other ENT symptoms. On examination, the child was conscious, alert and afebrile. The vitals were normal. On local examination of nose, there was blood stained discharge present in left nasal cavity. Right nasal cavity was free. On probing gritty sensation felt in left nasal cavity. X-ray PA view of skull showed radio-opaque foreign body with double rim appearance (Figure 2).



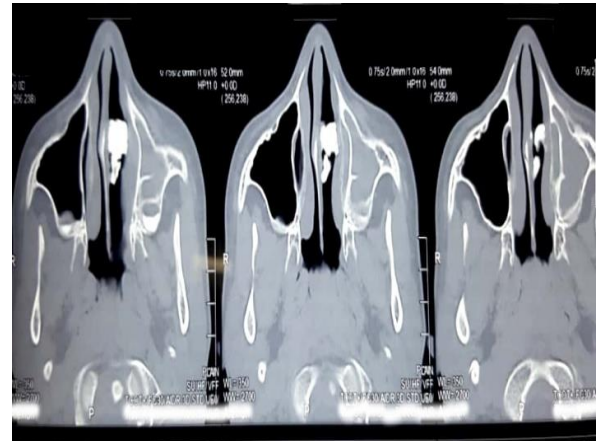**Figure 2: X-ray PA view of skull showing radiopaque foreign body with double rim appearance.**

A leaked button battery was removed by navigation using foreign body removal probe. Nasal cavity visualized and septum found to be intact in anterior rhinoscopy. Inferior turbinate and anterior part of middle turbinate was intact. On post nasal examination, the choana was free. Antibiotics, analgesics and normal saline nasal drops were given for 5 days. The child was advised to follow up after 7 days. On the follow up visit after 7 days, anterior rhinoscopy showed septum intact and inferior turbinate was normal on left side.

### Case 3

A 4 years old female child was referred to our tertiary care hospital from an ENT surgeon in the periphery area.

This child was having history of 4 months foul smelling nasal discharge which was treated by paediatrician initially and then referred to the ENT surgeon. The child was treated conservatively by nasal drops and antibiotics without taking X-ray PNS/DNE examination. After 4 months, now she was evaluated here. On arrival, clinically there was a black irregular mass occupying both nasal cavities.



**Figure 3: CT PNS axial view showing radio opaque foreign body.**

Patient was not cooperative for probing. So, the X-ray and CT PNS (Figure 3) were taken which showing radio opaque foreign body, the button battery. It was planned for an emergency endoscopic removal of foreign body under general anaesthesia. The procedure was done. On removal a large perforation involving cartilage part of septum was observed. The post-operative period was uneventful. X-ray chest showed no evidence of aspiration pneumonia.

### Case 4

A 3 years old boy came with history of foul-smelling nasal discharge for 5 days from the left nostril. On examination with rhinoscopy, the gritty sensation was felt along with bleeding. X-ray and CT were taken and showed radio opaque foreign body. Emergency endoscopic removal was done under general anaesthesia. The foreign body was found to be a leaked button battery (Figure 4) perforating the cartilaginous septum. This is septal perforation of neglected foreign body, the button battery. After removal of the foreign body, gel foam kept in situ. Post-operative period was uneventful.

### Case 5

A 1 and 1/2 years old male child was received in our OPD with history of accidental ingestion of button battery of the remote as witnessed by parents. There no history of any other specific ENT symptoms. The child was initially attended by a paediatrician and then referred to our tertiary institute for further management. On examination, the child was conscious, afebrile and no

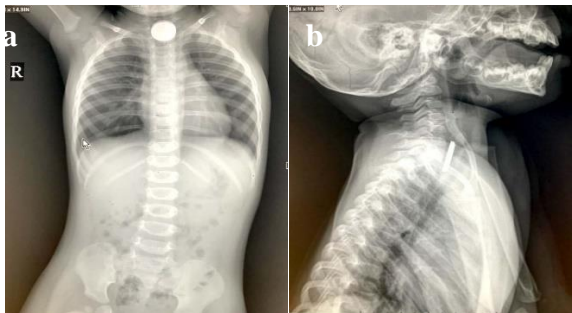

stridor noticed. There was history of dysphagia with refusal of feeds. X-ray STNL/chest were taken (Figure 5) immediately and found it to be button battery foreign body at the cricopharynx level.

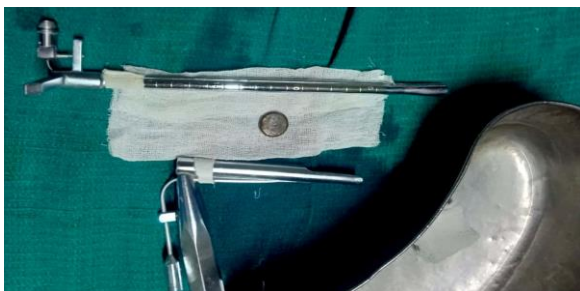After basic investigation patient was planned for an emergency foreign body removal by rigid esophagoscopy under general anaesthesia (Figure 6). Oesophagoscopy introduced per oral navigated to hypopharynx. The leaked button battery foreign body was found below cricopharynx which was removed by forceps. The leaked material was suctioned. No significant abnormality was observed. The procedure uneventful. Ryles tube was inserted. Patient recovered from general anaesthesia and extubated. Postoperatively, a paediatric physician's evaluation also was done. Nil significant complaints were received. Patient was discharge on the 4<sup>th</sup> post-operative day.



**Figure 4: Picture showing the leaked button battery removed from nasal cavity.**



**Figure 5 (a and b): X-ray STNL showing double rim appearance - the significance of button battery.**



**Figure 6: Button battery removed by rigid pediatric esophagoscopy.**

## DISCUSSION

This study is the case series which describes the various presentations and outcomes in a series of five children that presented with button batteries in which 3 were in the nose and 1 each in ear and throat. The first case of a button battery foreign body was reported in 1977 which involved a child swallowed a camera battery which lodged in the proximal esophagus. Batteries account for less than 2% of the foreign bodies ingested by children.<sup>1</sup> Button cell batteries are attractive to small children and often ingested. In the past 20 years, although there has not been an increase in the total number of button cell batteries ingested in a year, researchers have noted a 6.7 fold increase in the risk that an ingestion would result in a moderate or major complication and 12.5 fold increase in fatalities comparing the last decade to the previous one.<sup>9</sup>

The button battery is named after its shape. Lithium became the preferred cell type because of longer shelf life capacity, better stability at cool temperature, lighter weight, and ability to carry twice the voltage of previously used mercuric oxide, manganese dioxide, and zinc-air cells. With the increasing use of electronic gadgets at home, the use of button batteries has increased in the recent years, and their use is a routine affair in almost every household.<sup>10</sup>

Those who fail to read history are destined to suffer the repetition of his mistakes. Alessandro Giuseppe Antonio Anastasio Volta, an Italian physicist, chemist, and a pioneer of electricity and power is credited as the inventor of the electric battery. He invented the Voltaic pile in 1799. Volta's invention sparked a great amount of scientific excitement and led others to conduct similar experiments which eventually led to the development of the field of electrochemistry.<sup>11</sup> Since then, batteries have been widely applied in various electrical devices.

In this case series, 5 cases have been described. Of them 3 were in the nose and 1 each in ear and throat respectively. Of the 3 nasal cavity foreign bodies, only one had the large perforation of the nasal septum. Other 2 had not experienced any complications. This may be explained as early diagnosis and prompt treatment received by the later 2 patients. As per the history, the case which had complication was diagnosed very late and managed accordingly. Studies show that delayed management may lead to Inferior meatus ulceration, saddle deformities, chondritis, atrophic rhinitis, alar collapse, septal perforation, and nasal/choanal stenosis.<sup>8,12</sup> Because of the danger of liquefaction necrosis of the surrounding tissue, button batteries must be removed from the nose immediately.

Patients with batteries lodged in the esophagus have a greater potential for a serious outcome than those who have batteries that pass into the distal gastrointestinal tract. This is because batteries impacted in the esophagus exert a cumulative effect in a localized area without the

benefit of dilution of chemical and electrical effects provided by the gastrointestinal secretions in more distal segments.<sup>13</sup> In this study, one child with history of ingestion of button battery has been explained here. Unnoticed/unwitnessed foreign body is the common history in many foreign bodies in ear, nose and throat. Though it was noticed by parents immediately and attended by a paediatrician and managed promptly and referred in time, the battery which was found at the cricopharynx level as found leaking. The leaked material was suctioned and no significant abnormality was observed further.

Early suspicion of accidental foreign body ingestion or impaction, thorough history taking, compulsory radiological evaluation and prompt endoscopic guided removal of the foreign body under general anaesthesia wherever necessary are the major steps in managing foreign bodies in ENT system. The sole responsibility of the otolaryngologists is to make sure these measures taken promptly without delay which only can prevent serious complications.<sup>11</sup>

In this study, one child with button battery foreign body impacted in the ear has been described. Delay in the removal could potentially lead to stenosis of the external auditory canal, ossicular erosion, facial nerve injury, and necrosis of the medial wall of the middle ear resulting in a sensorineural deafness and damage to the vestibular labyrinth as experienced in the study by Thabet et al.<sup>14</sup> In this study, it was an intact battery and no leak of the button battery in the surrounding tissue was observed. That is why there was no complications observed.

## CONCLUSION

Hazardous material in the button battery is hazardous due to its electrochemical composition and the large potential for local damage and severe mucosal injuries. So, the button battery foreign body should be treated as a life-threatening. Early detection is the key in the management of button battery foreign bodies to improve outcomes. Physicians must recognize its hazardous potential and its serious implications. Radiologists must be aware of its danger and be trained to differentiate the button batteries from the coins. There is also a need for more public education on this serious problem.

*Funding: No funding sources*

*Conflict of interest: None declared*

*Ethical approval: Not required*

## REFERENCES

1. Heim SW, Maughan KL. Foreign bodies in the ear, nose, and throat. *Am Fam Physician.* 2007;76(8):1185-9.
2. Brown L, Denmark TK, Wittlake WA, Vargas EJ, Watson T, Crabb JW. Procedural sedation uses in the ED: management of pediatric ear and nose foreign bodies. *Am J Emerg Med.* 2004;22:310-4.
3. Muzio DJ, Deschler DG. Emergency department management of foreign bodies of the external ear canal in children. *Otol neurotol.* 2002;23:473-5.
4. Chan TC, Ufberg J, Harrigan RA, Vilke GM. Nasal foreign body removal. *J Emerg Med.* 2004;26:441-5.
5. Robinson PJ. Laryngeal foreign bodies in children: first stop before the right main bronchus. *J Paediatr Child Health.* 2003;39:477-9.
6. Lin VY, Daniel SJ, Papsin BC. Button batteries in the ear, nose and upper aerodigestive tract. *Int J Pediatric Otorhinolaryngol.* 2004;68(4):473-9.
7. Dane S, Smally AJ, Peredy TR. A truly emergent problem: button battery in the nose. *Academic Emergency Med.* 2000;7(2):204-6.
8. Fakhim AS, Bayazian G, Sohrabpour M. Neglected esophageal button battery ingestion: Local protocol for management. *Egyptian J Ear, Nose, Throat and Allied Sci.* 2013;14(1):27-31.
9. Anfang RR, Jatana KR, Linn RL, Rhoades K, Fry J, Jacobs IN. pH-neutralizing esophageal irrigations as a novel mitigation strategy for button battery injury. *Laryngoscope.* 2019;129:49-57.
10. Majumdar AB, Sengupta A, Paul SS. A case series of button batteries as nasal foreign bodies among children. *Int J Advances Med.* 2014;1(3):273-6.
11. Pancaldi, Giuliano. *Volta, Science and Culture in the Age of Enlightenment.* Princeton Univ Press ISBN. 2003;346(4):367-81.
12. Myla S, Shaik A. Nasal Septal Perforation Due to Button Battery: A Case Report. *IJSR.* 2014;3(11):2000-01.
13. Samad L, Ali M, Ramzi H. Button battery ingestion: hazards of esophageal impaction. *J Pediatric Surg.* 1999;34(10):1527-31.
14. Thabet MH, Basha WM, Askar S. Button Battery Foreign Bodies in Children: Hazards, Management, and Recommendations. *BioMed Res Int.* 2013;2013:7.

**Cite this article as:** Sebastian GP, Kaliyan R, Devadason P. Button battery foreign body among children: a case series. *Int J Otorhinolaryngol Head Neck Surg* 2020;6:983-7.