

Original Research Article

Efficacy of fine needle aspiration cytology in the early diagnosis of different head and neck malignancies: a hospital based prospective study

Bonapart Chowdhury*

Department of ENT, Shri Ramkrishna Institute of Medical Sciences and Sanaka Hospitals, Malandighi, Durgapur, West Bengal, India

Received: 18 November 2019

Revised: 14 January 2020

Accepted: 17 January 2020

***Correspondence:**

Dr. Bonapart Chowdhury,

E-mail: maildrbonapart@gmail.com

Copyright: © the author(s), publisher and licensee Medip Academy. This is an open-access article distributed under the terms of the Creative Commons Attribution Non-Commercial License, which permits unrestricted non-commercial use, distribution, and reproduction in any medium, provided the original work is properly cited.

ABSTRACT

Background: Fine needle aspiration cytology (FNAC) is a very useful diagnostic modality for early diagnosis of cancers in the head and neck region where large majority of the lesions are in the form of cervical lymphadenopathy, thus FNAC is easily feasible. This can be used as a significant screening tool if sensitivity is found to be high.

Methods: A hospital based prospective study to find the accuracy of FNAC in correctly diagnosing malignant lesions in patients with visible or palpable mass lesions in the head and neck area where both FNAC and histopathological examination (HPE) is possible taking HPE as gold standard.

Results: FNAC is a very effective tool in the early diagnosis of different head and neck malignancies with sensitivity of 91.37% and specificity of 97.62%.

Conclusions: FNAC is a simple, quick and safe diagnostic modality for different head and neck malignancies with significant sensitivity and specificity, thus can be used as a screening tool effectively.

Keywords: FNAC, Sensitivity, Specificity, Head and neck, Tumour

INTRODUCTION

Cancers of head and neck are major health issue worldwide, with an increasing incidence in the developing countries. The incidence is quite high in North Eastern states; Tripura being one of them is no exception. In India, head and neck cancers (HNCA) account for 30-40% cancers at all sites. It is the sixth common cause of death in males and seventh in females. In North-east India, incidence of tobacco related oral cancers is about 33%.¹ According to various studies, the prevalence of HNCA with respect to total body malignancies varies from 9.8% to 42.7%.² In one study in North East India, the prevalence was 54.48%.¹

Spread is dictated by local anatomy, and each site has its own pattern.³ Lymph nodes are common site of metastases for different cancers. Thus, clinical recognition and urgent diagnosis of palpable lymphadenopathy is of paramount importance.

FNAC was first used as a diagnostic tool in 1904 by Grieg and Grey. They aspirated trypanosomes from the lymph nodes of patients with sleeping sickness. Over the subsequent 30 years, its role was developed in particular by Guthrie who attempted to correlate the results of aspiration with a range of disease being investigated and by Martin & Ellis who, from their base at Memorial Sloan-Kettering Cancer Center in New York, developed its use in the diagnosis of malignancy.

Fine needle aspiration cytology (FNAC) is a very useful diagnostic modality for early diagnosis of cancers in the head and neck region where large majority of the lesions are in the form of cervical lymphadenopathy (CL). Moreover, like adults, in children also FNAC is considered to be safe and reliable mean of obtaining diagnostic material. Usually no complications arise from FNAC of cervical lymph nodes and there are no absolute contraindications for undertaking FNAC procedure. It is now the first line investigation for the diagnosis of palpable head and neck masses of all type. FNAC is readily applicable to all cases of cervical lymphadenopathy, a large number of which are reactive lymphadenitis, which when diagnosed on FNAC, ameliorate anxiety of patients.

The most common indication for FNAC in the head and neck in day to day practice is nodal metastasis or suspected local recurrence of previously diagnosed and treated cases.

FNAC has been widely accepted as a rapid, accurate and inexpensive diagnostic method which either enhances or reduces the probability of thyroid cancer prior to definitive histology. It is therefore used as a tool in the planning for surgery. FNAC is recommended as the primary investigation for suspected thyroid cancer.

The usefulness of salivary gland FNAC relates to the fact that it is easy to perform, is minimally invasive, smear evaluation is immediate and the procedure can be repeated several times to obtain more tissue for diagnosis or special studies. FNAC may be useful in evaluating poorly defined salivary gland masses and to confirm clinical suspicion of malignant disease in order to counsel patients before surgery. The main problem with salivary gland FNAC is deciding whether a tumor is benign or malignant. There is considerable overlap between the morphological patterns of salivary gland tumors found on cytology and as many are rare, it is not surprising that their interpretation is difficult. The great majority of common variants of salivary gland neoplasms can be diagnosed with a high level of accuracy and can avoid unnecessary surgery. Patients with a high operative risk may benefit a lot from information obtained by FNAC.

Sensitivity of a test means identifying the “true positives”, that is patients who are diseased having a positive test. Specificity of a test means identifying the “true negatives”, that is patients who are not diseased having a negative test. A screening test is expected to have a high sensitivity so that the rate of false negative is low.

Considering the magnitude of this problem of cancer and its implication to our society, an early diagnosis and treatment plays a vital role in the overall management and to achieve desired survival rate and prognostic prediction.

METHODS

This is a hospital based prospective study conducted at the Department of Otorhinolaryngology and Head and Neck Surgery, Agartala Government Medical College and GB Pant Hospital during November 2011 to November 2013. The sample size was calculated as per prevalence data available with an allowance of error of 20% of prevalence and level significance (Type I error) at 5%. Considering 82 as the minimum sample size by this calculation, 100 cases had been included in the study. Patients coming to ENT OPD with presenting complaints suggestive of head and neck neoplasm like neck swelling, unexplained epistaxis, thyroid swelling, hoarseness etc. with visible or palpable mass lesions in the head and neck area where both FNAC and histopathological examination (HPE) is possible were subjected to FNAC and then to HPE. All these cases were included in this study. Patients with suspected head and neck neoplasm where FNAC was feasible and those who had undergone biopsy later were taken up for this study. Efficacy of FNAC for diagnosis of head and neck malignancies was thus calculated taking HPE as gold standard. The data was analysed using SPSS software.

Inclusion criteria

Patients agreed to participate in the study after signing the informed consent, patients with suspected head and neck neoplasm where FNAC and HPE both were possible.

Exclusion criteria

Patients not willing to participate in the study, patients with suspected neoplasm where FNAC and biopsy were not possible due to any reason.

RESULTS

In the present study, the predominating population were male with 70.68% with maximum incidence in the 51-60 years of age distribution.

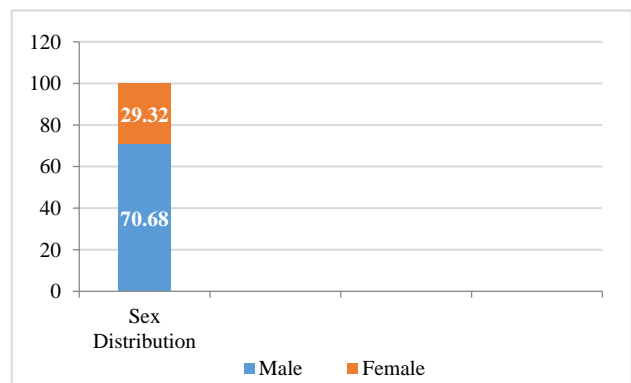


Figure 1: Sex distribution.

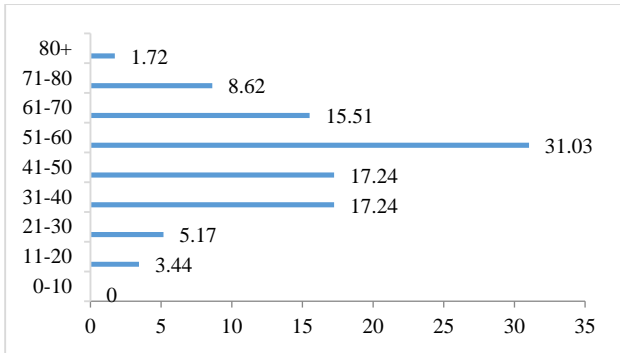


Figure 2: Age distribution.

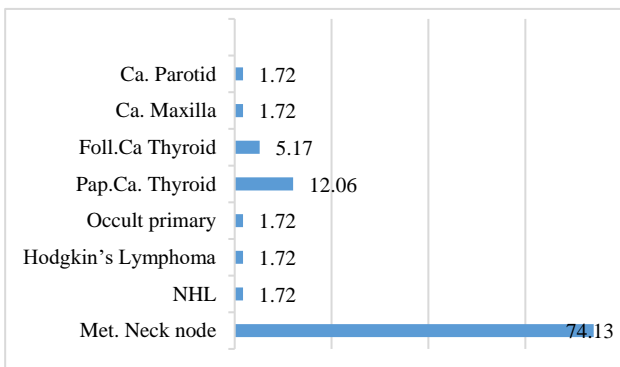


Figure 3: Pathological distribution.

Table 1: Histopathology.

| FNAC | + | - | Total |
|--------------|-----------|-----------|------------|
| + | 53 | 01 | 54 |
| - | 05 | 41 | 46 |
| Total | 58 | 42 | 100 |

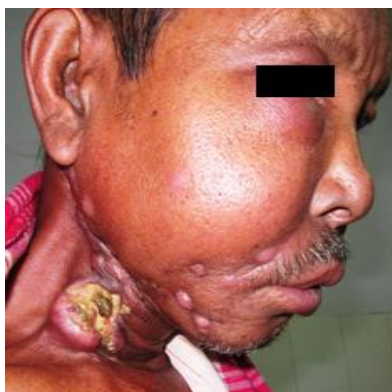

Figure 4: Fungating metastatic neck node.

The commonest pathology was metastatic cervical lymph node with 74.13% followed by papillary carcinoma thyroid with 12.06%. The sensitivity and specificity of FNAC was found to be 91.37% and 97.62% respectively with a positive predictive value of 98.15% and negative predictive value of 89.13% in this study. The percentage of false positive was found to be 2.38% and false negative was 8.62%.

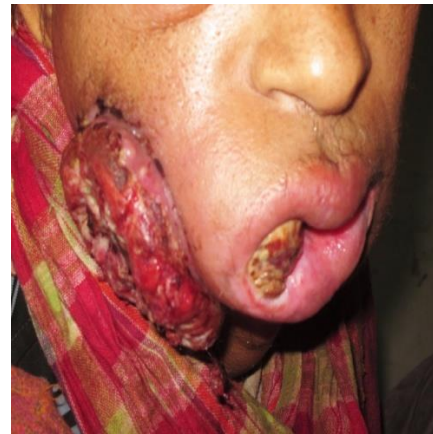

Figure 5: Sq. cell carcinoma buccal mucosa with extension to cheek.

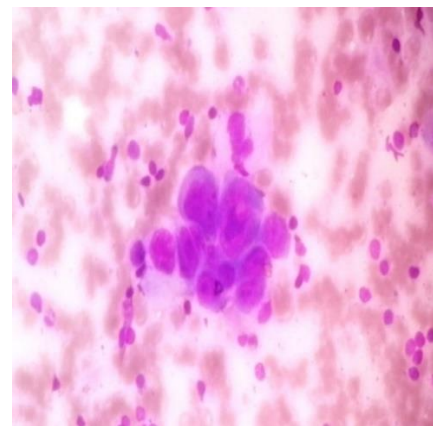


Figure 6: Photo micro graph of FNAC smear from a case of met. sq. cell carcinoma.

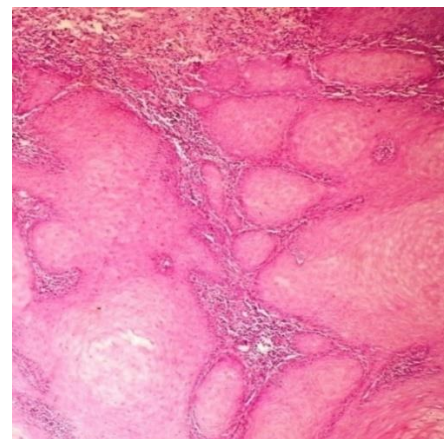


Figure 7: Photo micro graph of HPE section from a case of well diff. sq. cell carcinoma.

DISCUSSION

FNAC was found to have a sensitivity of 91.37% and specificity of 97.62% which is similar to the findings of Alwan et al and Kim et al where these were 97.9% and 100% respectively in cases of metastatic cervical

lymphadenopathy.^{4,5} Diagnosis of CL by FNAC has got certain limitations. The main limitation is the presence of only necrotic material in the aspirate without any cellular element. Mainly two possibilities are needed to be ruled out if only necrosis is found on aspirations which are tuberculosis and malignancy.

In case of lymphomas, Jacobs et al, Wakely et al and Morris et al had found sensitivity >80% and specificity around 95%.^{6,7,9} In the present study, the relative prevalence of Hodgkin's lymphoma and non-Hodgkin's lymphoma were 1.72% each. Another case was diagnosed as non-Hodgkin's lymphoma by FNAC was found to be reactive lymphadenitis by HPE after excision biopsy. As this study was aimed at head and neck malignancy in general, so any comment on lymphoma separately is not possible as the relative prevalence was not statistically significant. In case of thyroid nodules, 5 to 10% were malignant in a study by Morris et al where as it was 34.48% in the present study. This may be due to the fact that it was not a 'thyroid only' study and specific opinion regarding thyroid nodules is not possible from such small number of thyroid swelling samples. Different studies have found sensitivity and specificity in case of thyroid malignancy to be 83% and 92% respectively.¹⁰⁻¹³ Moon et al found sensitivity of 84.9% with respect to thyroid malignancy.¹⁴ Another study of 62 thyroid cancer patients at University of California, Los Angeles (UCLA) revealed that FNAC has sensitivity of 71% and false negative rate 14.5%.¹⁵ It has also been shown in a study that 7% of repeat FNAC are reported as positive for malignancy, where initial FNAC was negative.¹⁶

In the present study, there were 12.06% cases of papillary thyroid carcinoma which were diagnosed correctly by FNAC as both FNAC & HPE were similar. As this was a study of Head & Neck malignancy in general, any opinion regarding efficacy of FNAC in diagnosing thyroid malignancy is not possible.

Distinguishing between follicular adenoma and carcinoma is not possible by FNAC as it requires demonstration of invasion of the capsule, lymphatics or blood vessels.^{15,17,18}

In the present study, there were 5.17% cases of follicular neoplasia in thyroid swelling as diagnosed by FNAC, out of which 60% were found to be malignant i.e. follicular carcinoma by HPE.

In case of salivary gland malignancy, sensitivity was found widely varying from 29-97% and specificity 84-100%.^{19,20-23} The rate of malignant lesions out of all salivary gland tumours were found to be 15-32%.^{21,22} As in the present study there was only 1.72% case of salivary gland malignancy in the form of squamous cell carcinoma of parotid, any opinion in this regard is not possible.

FNAC was found to be a safe procedure in this study where none of the patients reported any adverse events like vaso vagal attack, vertigo or haemorrhage etc. It was also found to be quick procedure with insignificant pain and easy to perform.

CONCLUSION

FNAC is a simple, quick and safe diagnostic modality for different head and neck malignancies with significant sensitivity and specificity, thus can be used as a screening tool effectively.

ACKNOWLEDGEMENTS

Author would like to thank Dr. Arun Kr Bhattacharjee, Ex. Professor and HOD, Department of ENT, Dr. Abhijit Datta, Associate Professor, Department of Pathology and Dr. Bhupendra Debbarma, Assistant Professor, Department of ENT, Agartala Govt. Medical College and GB Pant Hospital.

Funding: No funding sources

Conflict of interest: None declared

Ethical approval: The study was approved by the Institutional Ethics Committee

REFERENCES

1. Bhattacharjee A, Chakraborty A, Purkaystha P. Prevalence of head and neck cancers in the North East- an institutional study: *Indian J Otolaryngol Head Neck Surg.* 2006;58:15-9.
2. Thakur S, Chaturvedi V, Singh AK, Puttevar MP, Raizada RM. Pattern of ear, nose, pharynx, larynx and esophagus (ENPLO) cancers in rural based hospital. *Indian J Otolaryngol Head Neck Surg.* 2001;53:93-9.
3. McGuirt WF. Differential diagnosis of neck masses. In: Cummings Ch W, Fredrickson JM, editors. *Otolaryngology head & neck surgery*, vol 3. 3rd ed. Philadelphia (PA) : Mosby; 1998: 1743-1746.
4. Kim BM, Kim EK, Kim MJ, Yang WI, Park CS. Sonographically guided core needle biopsy of cervical lymphadenopathy in patients without known malignancy. *J Ultrasound Med.* 2007;26:585-91.
5. Nada al Alwan, Al Hashimi AS, Salman MM, Al Attar EA. Fine needle aspiration cytology versus histopathology in diagnosing lymph node lesion. *Eastern Mediterranean Health J.* 1996;2:320-5.
6. Jacobs JC, Katz RL, Shabb N, el-Naggar A, Ordonez NG, Pugh W. Fine needle aspiration of lymphoblastic lymphoma- A multiparametre diagnostic approach. *Acta Cytol.* 1992;36:887-94.
7. Wakely PE Jr, Kornstein MJ. Cytopathology of lymphoblastic lymphoma & Leukaemia: The MCV experience. *Pediatr Patol Lab Med.* 1996;16:243-52.
8. Martin HE, Ellis EB. Biopsy by needle puncture and aspiration. *Ann Surg.* 1930;92:169-81.

9. Morris LF, Ragavendra N, Yeh MW. Evidence-based assessment of the role of ultrasonography in the management of benign thyroid nodules. *World J Surg.* 2008;32:1253-63.
10. Gharib H. Fine-needle aspiration biopsy of thyroid nodules: Advantages, limitations, and effect. *Mayo Clin Proc.* 1994;69:44-9.
11. Castro MR, Gharib H. Thyroid fine-needle aspiration biopsy: Progress, practice, and pitfalls. *Endocr Pract.* 2003;9:128-36.
12. Gharib H, Goellner JR. Fine-needle aspiration biopsy of thyroid nodules. *Endocr Pract.* 1995;1:410-7.
13. Jeffrey PB, Miller TR. Fine-needle aspiration cytology of the thyroid. *Pathology (Phila).* 1996;4:319-35.
14. Moon HG, Jung EJ, Park ST, Ha WS, Choi SK, Hong SC, et al. Role of ultrasonography in predicting malignancy in patients with thyroid nodules. *World J Surg.* 2007;31:1410-6.
15. Cappelli C, Castellano M, Pirola I, Cumetti D, Agosti B, Gandossi E, et al. The predictive value of US findings in the management of thyroid nodules. *QJM.* 2006;100:29-35.
16. Dwarakanathan AA, Staren ED, D'Amore MJ, Kluskens LF, Martirano M, Economou SG. Importance of repeat fine-needle biopsy in the management of thyroid nodules. *Am J Surg.* 1993;166:350-2.
17. Howlett DC, Harper B, Quante M, Berresford A, Morley M, Grant J, et al. Diagnostic adequacy and accuracy of fine needle aspiration cytology in neck lump assessment: results from a regional cancer network over a one year period. *J Laryngol Otol.* 2007;121:571-9.
18. Kopald KH, Layfield LJ, Mohrmann R, Foshaq LJ, Giuliano AE. Clarifying the role of fine-needle aspiration cytologic evaluation and frozen section examination in the operative management of thyroid cancer. *Arch Surg.* 1989;124:1201-5.
19. Cohen MB, Reznicek MJ, Miller TR. Fine needle aspiration biopsy of the salivary glands. *Pathol Annu.* 1992;27:213-45.
20. Al-Khafaji BM, Nestok BR, Katz RL. Fine needle aspiration of 154 parotid masses with histologic correlation: ten year experience at the University of Texas M.D. Anderson cancer center. *Cancer.* 1998;84:153-9.
21. Wong DSY, Li GKH. The role of fine needle aspiration cytology in the management of parotid tumors: a critical clinical appraisal. *Head Neck.* 2000;22:469-73.
22. Hee CGQ, Perry CF. Fine needle aspiration cytology of parotid tumors: is it useful? *ANZ J Surg.* 2001;71:345-8.
23. Zhang S, Bao R, Bagby J, Abreo F. Fine needle aspiration of salivary glands: 5-year experience from a single academic center. *Acta Cytol.* 2009;53(4):375-82.

Cite this article as: Chowdhury B. Efficacy of fine needle aspiration cytology in the early diagnosis of different head and neck malignancies: a hospital based prospective study. *Int J Otorhinolaryngol Head Neck Surg* 2020;6:510-4.