

Case Report

Efficacy of tympanometry screening methods for early clinical diagnosis of otosclerosis

Prabina R. Mohanty*, Abam Fasal

Department of ENT, Al Ameen Medical College and Hospital, Athani Road, Vijayapur, Karnataka, India

Received: 11 November 2019

Accepted: 19 December 2019

*Correspondence:

Mr. Prabina R. Mohanty,

E-mail: mohantyaudiologist@gmail.com

Copyright: © the author(s), publisher and licensee Medip Academy. This is an open-access article distributed under the terms of the Creative Commons Attribution Non-Commercial License, which permits unrestricted non-commercial use, distribution, and reproduction in any medium, provided the original work is properly cited.

ABSTRACT

The diagnosis is suspected clinically based on microscopic otoscopy, audiometry, and tympanometry. Thin-section computed tomography of the temporal bone helps to confirm the diagnosis. This case report aimed to promote the importance of tympanometry screening as a diagnostic tool for middle ear pathology. A case of 27-year-old patient came to ENT-OPD at Al-Ameen Medical College and Hospital, Vijayapur with the complaint of decreased hearing since 2 years. The history of intermittent tinnitus and swimming habit with head bath regularly were found in the patient. Also, there were no significant family history of hearing loss, ear discharge, and ear pain. This case report concluded that the continuous head bath may leads to middle ear pathologies like otosclerosis and give importance to tympanometry test for early clinical diagnosis and suggesting for avoiding swimming, and also use of ear plugs as necessary during head bath.

Keywords: Head bath, Otosclerosis, Tympanometry

INTRODUCTION

Patients frequently experience conductive hearing loss after petrous temporal bone fracture, possibly related to haemorrhagic filling of the middle ear, or ossicular dislocation or fracture, usually involving the incus.¹ The diagnosis is suspected clinically based on microscopic otoscopy, audiometry and tympanometry. Thin-section computed tomography of the temporal bone helps to confirm the diagnosis.²

Otosclerosis, classically described as an osteodystrophic change localized to the bony labyrinth and stapes footplate, is of autosomal dominant inheritance with incomplete penetrance and variable expressivity. Although no etiology or pathogenesis has been identified, certain clinical and epidemiologic characteristics have been reported.

- Otosclerosis is more common in women in a ratio of 2.5:1, and frequently accelerated with pregnancy or use of contraceptives.
- Otosclerosis is usually bilateral and symmetrical, beginning at the fissula ante fenestram in 70-90% of cases.
- Symptomatic otosclerosis usually begins between the ages of 11 and 30 in 70% of individuals, and in only 2-3% prior to age 15.³

Clinical otosclerosis as a rule becomes manifest in early adult life, however, histological otosclerosis has been observed at as early as one year.⁴ The exact incidence of clinical and histological otosclerosis per racial sector is unknown. Clinical otosclerosis has been reported in the white population in a ratio of 1:100, and in the American Negro in a ratio of 1:1000.⁴ Furthermore, few clinical and histological studies address otosclerosis in childhood and none discuss racial incidence.^{5,6} Guild et al, demonstrated

histological otosclerosis in 44 of 589 "normal" temporal bones, with 4 under the age of fifteen; otosclerotic foci occurred in only 0.6% of temporal bones in patients under age 5, and 4% over age 5, rising to an incidence of 10% in males and 18% in females between the ages of 30 and 50.⁷

Determining the aetiology of conductive hearing loss with an intact tympanic membrane has been a challenge for the otologists for over decades. Diagnostic tools like pure tone audiometry, tympanometry and high resolution computed tomography scans have been routinely used with very less specificity and sensitivity. The otologist frequently has to resort to exploratory tympanotomy in order to establish a diagnosis and to allow for further management. When exploratory tympanotomy is undertaken in such a setting, studies reveal that the common causes of hearing loss are otosclerosis, ossicular fixation and ossicular discontinuity.⁸

Middle ear exploration using microscope has been the choice of approach for many years but with the advent of endoscopes with superior optical properties, otoendoscopes are increasingly being used as a diagnostic, surgical and a teaching tool.⁹

This case report aimed to promote the importance of tympanometry screening as a diagnostic tool for early clinical diagnosis of otosclerosis.

CASE REPORT

A case of 27-year-old patient came to ENT OPD at Al-Ameen Medical College and Hospital, Vijayapur with the complaints of decreased hearing (hg) since 2 years. The history of intermittent tinnitus and swimming habit with head bath regularly were found in the patient. Also, there was no significant family history of hearing loss, ear discharge or ear pain.

Pure-tone audiometry (125, 250, 500, 1000, 2000 4000 and 8000 Hz) showed right conductive hearing loss with an audiometric air-bone gap of 20 dB HL. Speech audiometry confirmed the results of pure-tone audiometry with normal hearing in the left ear.

Audiogram demonstrated a 45 dB speech reception threshold (SRT) with a 40 dB air-bone gap and 96% discrimination in the right ear (his subjectively worst hearing ear), and a 35 dB SRT with a 30 dB air-bone gap and 96% discrimination in the left ear (Figure 1).

On tuning fork testing, Rinne showed negative (-ve) in right ear and positive (+ve) in left ear and Weber lateralized to left. Pure tone audiometry test revealed in Figure 1. These results showed; right ear mild (HF) conductive hearing (Hg) loss and left ear normal hg sensitivity. Tympanometry screening (MT-10 Interacoustics screening) finding revealed in Figure 2. Standard tympanometry produced a type A_s curve

bilaterally. Generally, type A_s tympanometry curve is seen with a 220 Hz probe tone in otosclerosis. In this case, bilateral A_s type tympanogram with presence of no reflexes were found in both ears.

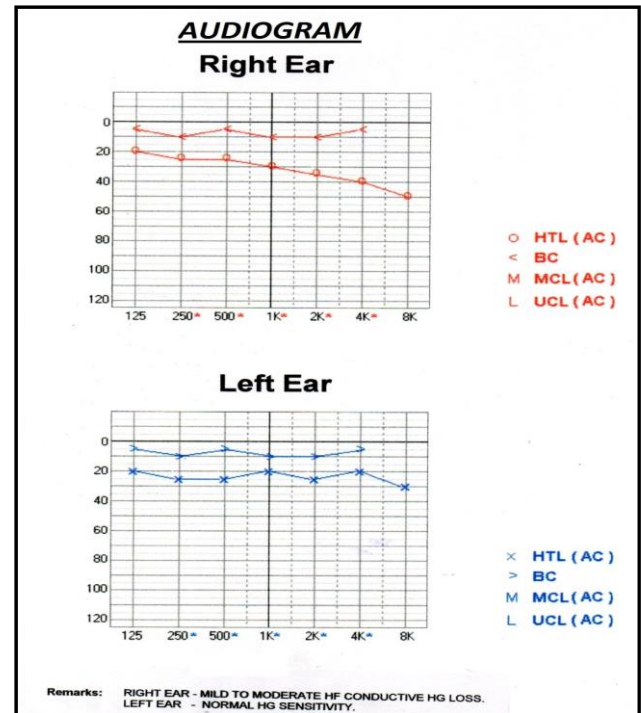


Figure 1: Pure tone audiometry report.




Figure 2: A_s type tympanogram of otosclerosis diagnosis.

DISCUSSION

A case of 27-year-old patient complained of decreased hearing since 2 years. The history of intermittent tinnitus and swimming habit with head bath regularly were found in the patient. Also, there were no significant family history of hearing loss, ear discharge or ear pain. Furthermore, Otolaryngologic physical examination was unremarkable. On tuning fork testing, Rinne showed negative (-ve) in right ear and positive (+ve) in left ear and Weber lateralized to left. Standard tympanometry produced a Type A_s curve bilaterally with presence of no reflexes in both ears. Generally type A_s tympanometry curve is seen with a 220 Hz probe tone in otosclerosis. Loss of the high frequency type D pattern has been reported in otosclerosis.¹⁰ Furthermore, a type E or undulating pattern has been associated with ossicular discontinuity.¹¹ Therefore, high-frequency probe-tone tympanometry in conjunction with evaluation of acoustic reflex and static middle ear impedance may prove useful in the differential diagnosis of conductive hearing loss without middle ear effusion with an otherwise normal standard 220 Hz probe-tone tympanogram.

In another study, analyzed the various middle ear pathologies on performing endoscopic exploratory tympanotomy in 88 patients with conductive hearing loss having an intact tympanic membrane. During this study exploration of middle ear has been exclusively done endoscopically with comparing results to other similar studies which are done by microscopic and endoscopic approach.¹²

Intraoperatively 5.7% of patients had normal middle ear status both structurally and functionally in spite of clinical and audiological conductive hearing loss. Bess et al found pathologic third windows to be a potential cause of conductive hearing loss in 20% of patients who failed to obtain hearing gain after exploratory tympanotomy and ossiculoplasty.¹³ Of the congenital middle ear abnormalities observed, congenital stapes agenesis was seen in 1 patient and it was first reported by Mcaskile et al in two patients who had conductive hearing loss.¹⁴ Another middle ear abnormality encountered was a high jugular bulb which can be present in 10%–15% of individuals and can be dehiscent in 0.5%–1.7% which can also be the cause of hearing loss.¹⁵

CONCLUSION

This case report concluded that the continuous head bath leads to middle ear pathologies like otosclerosis and give importance to tympanometry test for early clinical diagnosis and suggesting for avoiding swimming and also use of ear plugs as necessary during head bath.

Funding: No funding sources

Conflict of interest: None declared

Ethical approval: Not required

REFERENCES

1. Muzaffar S, Orr L, Rickard R, Coulson C, Irving R. Mitigating noise-induced hearing loss after blast injury. *Trauma*. 2019;21(2):121-7.
2. Kanavati O, Salamat AA, Tan TY, Hellier W. Bilateral temporal bone fractures associated with bilateral profound sensorineural hearing loss. *Postgraduate Med J*. 2016;92(1087):302-3.
3. Singla S, Dempsey C, Warren R, Enikolopov AG, Sawtell NB. A cerebellum-like circuit in the auditory system cancels responses to self-generated sounds. *Nature Neurosci*. 2017;20(7):943.
4. Sharaf RA. Prevalence and pathogenesis of otosclerosis: A review. *Biosci Biotech Res Comm*. 2019;12(1):54-9.
5. Page JC, Gau VL, Allsopp T, King D, Jervis-Bardy J, Dornhoffer JL. Outcomes of Primary Pediatric Stapedotomy. *Otol Neurotol*. 2019;40(8):1054-8.
6. Asik B, Binar M, Serdar M, Satar B. A meta-analysis of surgical success rates in Congenital stapes fixation and juvenile otosclerosis. *The Laryngoscope*. 2016;126(1):191-8.
7. Rudic M, Keogh I, Wagner R, Wilkinson E, Kiros N, Ferrary E, et al. The pathophysiology of otosclerosis: review of current research. *Hearing Research*. 2015;330:51-6.
8. Carter JM, Hoff SR. Endoscopic middle ear exploration in pediatric patients with conductive hearing loss. *Int J Pediatr Otorhinolaryngol*. 2017;96:21-4.
9. Bhattarai H. Endoscopy on Otology-In Retrospect and Prospects. *Nepalese J ENT Head Neck Surg*. 2012;3(1):21-3.
10. Jacobson JT, Mahoney TM. Admittance tympanometry in otosclerotic ears. *J Am Audiol Society*. 1977;3(2):91-8.
11. Alberti PW, Jerger JF. Probe-tone frequency and the diagnostic value of tympanometry. *Arch Otolaryngol*. 1974;99(3):206-10.
12. Park JH, Park YK, Kim KS, Kim BS. A Case of Conductive Hearing Loss by Heterotopic Neuroglial Tissue in the Middle Ear. *Korean J Otorhinolaryngol-Head Neck Surg*. 2003;46(8):696-8.
13. Bess F, Miller G, Bratt G. Unexplained conductive hearing loss. *Southern Med J*. 1980;73(3):335-8.
14. McAskile K. Surgical management of congenital atresia of the ear. *The Laryngoscope*. 1957;67(7):691-4.
15. Huang B-R, Wang C-H, Young Y-H. Dehiscent high jugular bulb: a pitfall in middle ear surgery. *Otol Neurotol*. 2006;27(7):923-7.

Cite this article as: Mohanty PR, Fasal A. Efficacy of tympanometry screening methods for early clinical diagnosis of otosclerosis. *Int J Otorhinolaryngol Head Neck Surg* 2020;6:400-2.