

Case Report

Rhinolith causing unilateral chronic rhinosinusitis: a case report

Sumit Prinja, Garima Bansal*, Jailal Davessar, Simmi Jindal, Suchina Parmar

Department of Otorhinolaryngology, Guru Gobind Singh Medical College and Hospital, Faridkot, Punjab, India

Received: 04 November 2019

Accepted: 31 December 2019

***Correspondence:**

Dr. Garima Bansal,

E-mail: garimabansal64@gmail.com

Copyright: © the author(s), publisher and licensee Medip Academy. This is an open-access article distributed under the terms of the Creative Commons Attribution Non-Commercial License, which permits unrestricted non-commercial use, distribution, and reproduction in any medium, provided the original work is properly cited.

ABSTRACT

Rhinolith or nasal stone is formed by mineralization within nasal cavity. They are calcareous concretions that are formed by the deposition of salts on an intranasal foreign body. It is an uncommon disease that may present asymptotically or cause symptoms like nasal obstruction, consecutive sinusitis with or without purulent rhinitis, post nasal discharge, epistaxis, anosmia, nasal malodour and headache. They are usually diagnosed incidentally on radiographic examinations or depending on the symptoms. In this paper we report a 28-year-old woman admitted in the ENT department of GGS Medical College and Hospital, Faridkot with a calcified mass in the right nasal cavity causing long standing unilateral nasal obstruction for 3 years, rhinorrhoea (usually malodourous foetid), post nasal discharge and headache for 1 year. The calcified mass was thought to contain the air cell and removed by endonasal approach. The aim of this study is to report a case of rhinolith with chronic maxillary sinusitis along with a review of literature.

Keywords: Rhinolith, Rhinosinusitis, Nasal obstruction

INTRODUCTION

Rhinolith is a mass resulting from calcification of foreign body within the nasal cavity.¹ The foreign body can be either endogenous or exogenous. If a rhinolith occurs around a body mass such as ectopic tooth, clotted blood, dried pus/secretions, desquamated epithelium, sequestered bone fragments or leucocytes, it is termed as endogenous and if it occurs around a foreign object such as forgotten piece of stone, cotton wool, bead, grains, plastic parts, parasites, sand or fruits, it is termed as exogenous.

It is usually found in the floor of the nose about midway between anterior and posterior portion of nares.

Rhinoliths can have various clinical presentations like unilateral nasal obstruction, rhinorrhoea (usually malodorous foetid and purulent) and epistaxis or postnasal bleeding. Other less common symptoms are headache, facial pain and epiphora.² Foreign bodies of

high radiodensity are easily identified and localised using conventional radiography. However, computed tomography (CT) scan often helps in identifying the extent of the lesion and the choice of surgical approach.³

Here we present the case of a patient with right sided rhinolith containing air cell and left sided deviated nasal septum with right maxillary sinusitis.

CASE REPORT

A 28 year old woman was admitted to our institution with the complaints of long standing unilateral nasal obstruction, post nasal discharge, anosmia and headache. An anterior rhinoscopy revealed right sided rhinolith and left sided deviated nasal septum. Further anterior rhinoscopy revealed foul smelling discharge from the right nasal cavity and narrowed nasal cavity. Rigid nasal endoscopy noted right sided rhinolith in the inferior meatus (Figure 1 and 2). Her coronal paranasal sinus CT scan revealed a hyperdense shadow involving the right

nasal cavity at inferior turbinate (Figure 3 and 4). The radiopaque mass was thought to contain air cell. Right maxillary sinus shows mucosal oedema suggestive of sinusitis. Initial diagnosis was rhinolith. Operation was done under general anesthesia. An uncinectomy was done during ESS and rhinolith was removed from the right nasal cavity (Figure 5). Maxillary ostium was widened and septoplasty was done on the left side for deviated nasal septum. The patient's complaints of nasal obstruction, post nasal discharge, anosmia and headache were completely relieved within a short time after surgery.

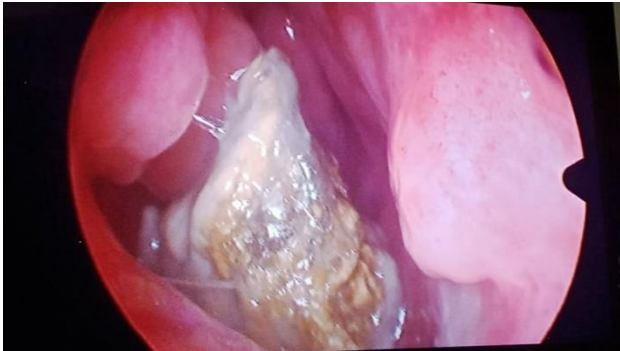

Figure 1: Right sided rhinolith seen on preoperative nasal endoscopy.

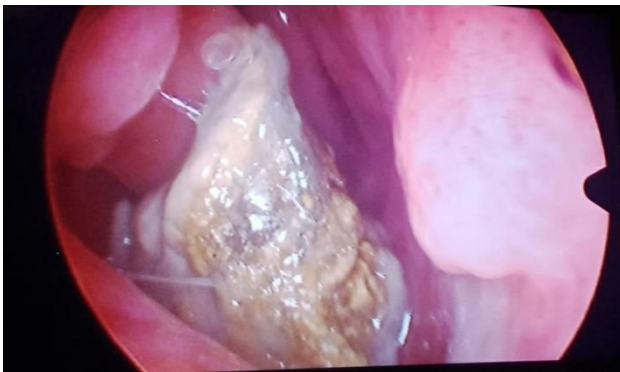

Figure 2: Right sided rhinolith seen during operative nasal endoscopy.

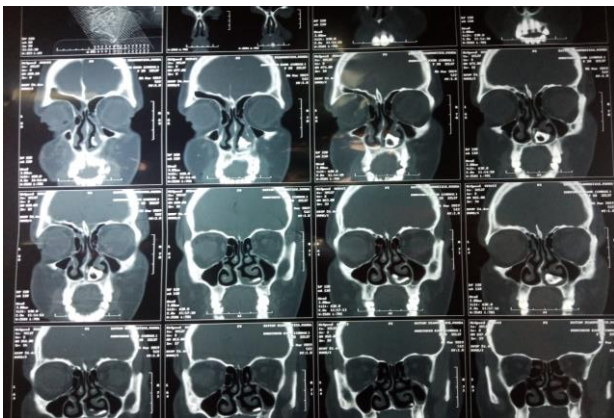


Figure 3: Right sided rhinolith seen on CT scan.

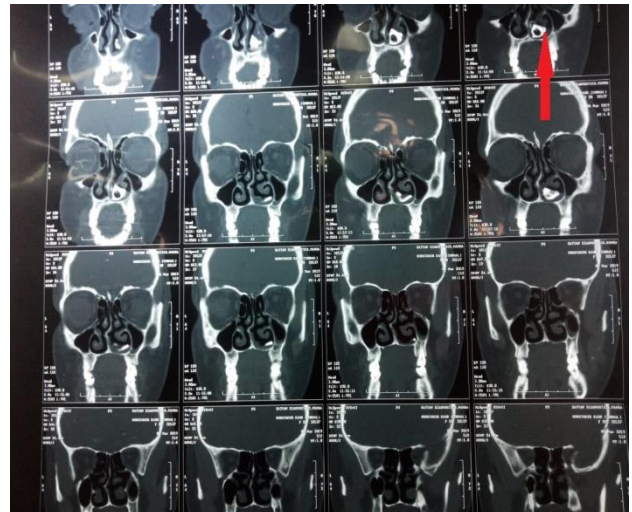


Figure 4: Arrow demonstrates right sided rhinolith with air cell seen on CT scan.

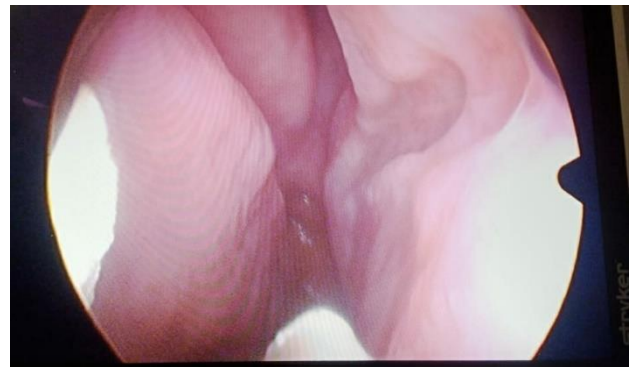

Figure 5: Right sided nasal cavity after the removal of rhinolith.

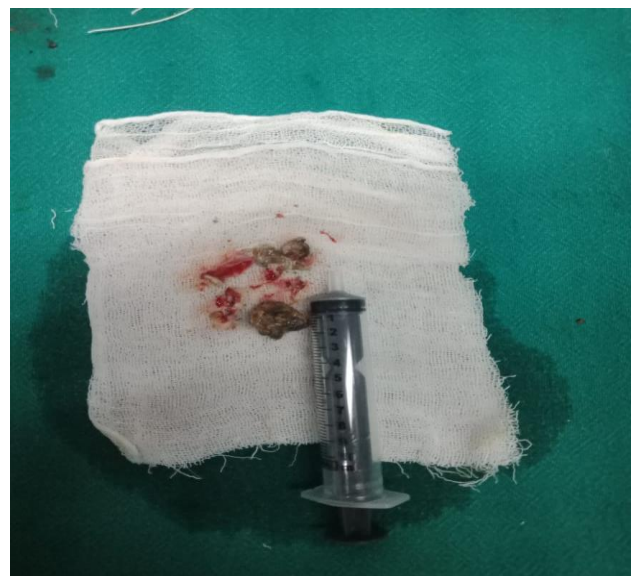


Figure 6: Specimen of rhinolith.

Macroscopy of the mass was a blackish, rough foreign body (Figure 6).

Histopathological examination of the right nasal mass showed fragments of non-viable tissue with areas of calcification suggestive of rhinolith (Figure 6).

After the surgery she was advised to perform nasal douching with normal saline. Oral antibiotic therapy, analgesics and nasal decongestants were prescribed. Patient was followed up 3 weeks postoperatively for repeat nasal endoscopy and nasal douching.

DISCUSSION

The term 'rhinolith' arises from the Greek words 'rhina' and 'lithos', meaning nose and stone.⁴ The first well documented case of rhinolithiasis was reported by Bartholin in 1654.⁵ It is a rare case and incidence is 1:10 000 in ear-nose-throat outpatients.⁶ In most of the cases it occur in the lower nasal meatus.⁷ Rhinoliths are almost always unilateral; however, it is possible to determine a bilateral rhinolith rarely.⁸

Rhinoliths are diagnosed in the third decade of life and mostly seen in females. They are rarely seen in children. In this present case, the patient was in her third decade and female, which are consistent with the literature.⁹

Although the pathogenesis of rhinolith remains unclear; a number of factors are thought to be involved in the formation of rhinoliths. These include entry and impaction of a foreign body in the nasal cavity, acute and chronic inflammation, obstruction and stagnation of nasal secretions, and precipitation of mineral salts.¹⁰ However, the most common cause of rhinolith is retained foreign bodies. Foreign bodies normally access the site anteriorly, but they may occasionally reach into the nasal cavity through the choana by cough or vomiting.³ Development and progression are believed to take a number of years. Most patients complain of purulent rhinorrhea and ipsilateral nasal obstruction. Other symptoms include fetor, epistaxis, sinusitis, headache and, in rare cases, epiphora.

The presence of nasal septum deviation as in the case with left sided deviation and perforation, destruction of the lateral wall of the nasal cavity, involvement of the maxillary sinus and production of oronasal or oronasal fistula are rare complications that may occur with the growth of the rhinolith.¹¹

In some patients, rhinoliths are discovered incidentally. Examination should include anterior rhinoscopy and rigid nasal endoscopy which is the main diagnostic method. Simple x-rays can also be done. Computed tomography of the paranasal sinuses can accurately determine the location and size of the rhinolith and identify any coexisting sinus disease and complications that might also require treatment.¹² In our case air cell was found within the rhinolith and the radiolucent centre of the mass might be the result of an organic nidus.

This advanced imaging method presents high sensitivity and specificity for identifying calcifications and foreign bodies, and can be applied most effectively for the diagnosis of rhinoliths.^{11,13}

The differential diagnosis should include calcified polyps, impacted tooth, odontomes, granulomas, sequestration following local osteomyelitis, osteomas, chondrosarcoma, osteosarcoma and sinonasal malignancy.¹⁴

The treatment is removal of rhinolith and the approach depends upon the size and site of the rhinolith. We preferred an endonasal approach for removal of the mass in order to reduce the morbidity. If it is large, it should be crushed and the fragments removed. Postoperative extensive nasal douching is important to prevent further complications.

CONCLUSION

Although rhinoliths are a rare occurrence, the doctors should be aware of it and should have a high index of suspicion in cases with progressive unilateral nasal obstruction, unilateral rhinorrhea, anosmia, headache and unilateral nasal bleeding.

Hence, rhinolith must be considered at differential diagnosis of masses observed in nasal structures and significance of radiologic inspection (especially computed-tomography) should not be forgotten as well as the routine physical examination of otorhinolaryngology.

Funding: No funding sources

Conflict of interest: None declared

Ethical approval: Not required

REFERENCES

1. Hsiao JC, Tai CF, Lee KW, Ho KY, Kou WR, Wang LF. Giant rhinolith: a case report. Kaohsiung J Med Sci. 2005;21:582-4.
2. Singh RK, Varshney S, Bist SS, Gupta N, Bhatia R, Kishor S. A case of rhinolithiasis. Online J Health Allied Scs. 2008;7(2):7-9.
3. Dib GC, Tangerina RP, Abreu EC, Santos RD, Gregório LC. Rhinolithiasis as cause of oronasal fistula. Braz J Otorhinolaryngol. 2005;71:101-3.
4. Igoumenakis D, Athanasiou S, Mezitis M. A bizarre cause of extensive oronasal fistula. J Craniofac Surg. 2013;24:483-4.
5. Al Mastour AS, Ghnam WM, Zubaidi AH. Rhinolith: delayed presentation after head trauma— a case report. Case Rep Otolaryngol. 2012.
6. Vedralam S, Sipaul F, Hill A, Porter G. Nasendoscopy for unusual nasal symptoms. BMJ Case Rep. 2010.
7. Yildirim N, Arslanoglu A, Sahan M, Yildirim A. Rhinolithiasis: clinical, radiological, and

- mineralogical features. *Am J Rhinol.* 2008;22:78-81.
8. Brehmer D, Riemann R. The rhinolith-a possible differential diagnosis of a unilateral nasal obstruction. *Case Rep Med.* 2010.
 9. Chatziavramidis A, Kondylidou-Sidira A, Stefanidis A, Soldatou S. Longstanding rhinolith leading to anatomical alterations of the ipsilateral inferior nasal meatus and turbinate. *BMJ Case Rep.* 2010.
 10. Ezsias A, Sugar AW. Rhinolith: an unusual case and an update. *Ann Otol Rhinol Laryngol.* 1997;106:135-8.
 11. Sumbullu MA, Tozoglu U, Yoruk O, Yilmaz A, Ucuncu H. Rhinolithiasis: the importance of flat panel detector-based cone beam computed tomography in diagnosis and treatment. *Oral Surg Oral Med Oral Pathol Oral Radiol Endod.* 2009;107:65-7.
 12. Aksungur EH, Binokay FB, Biçakçi K. A rhinolith which is mimicking a nasal benign tumor. *Eur J Radiol.* 1999;31:53-5.
 13. Sudhakar S, Kumar B, Prabhat M. Rhinolith: A case report and review of literature. *J Indian Acad Oral Med Radiol.* 2010;22:165-7.
 14. Hadi U, Ghossaini S, Zaytoun G. Rhinolithiasis: A forgotten entity. *Otolaryngol Head Neck Surg.* 2002;126:48-51.

Cite this article as: Prinja S, Bansal G, Davessar J, Jindal S, Parmar S. Rhinolith causing unilateral chronic rhinosinusitis: a case report. *Int J Otorhinolaryngol Head Neck Surg* 2020;6:414-7.