

## Case Report

# Ewing's sarcoma of sinonasal tract: a rare case

Ankur Gupta\*, Ancy S. Sofia, Kanwar Sen

Department of ENT, PGIMER Dr RML Hospital, New Delhi, India

**Received:** 10 October 2019

**Revised:** 29 November 2020

**Accepted:** 06 January 2020

**\*Correspondence:**

Dr. Ankur Gupta,

E-mail: [gupta.ankur39@yahoo.in](mailto:gupta.ankur39@yahoo.in)

**Copyright:** © the author(s), publisher and licensee Medip Academy. This is an open-access article distributed under the terms of the Creative Commons Attribution Non-Commercial License, which permits unrestricted non-commercial use, distribution, and reproduction in any medium, provided the original work is properly cited.

### ABSTRACT

Extra skeletal Ewing's sarcoma (EES) is a rare, rapidly growing, round cell malignant tumour that can develop in the soft tissue at any location. Involvement of the paranasal sinus is a very rare entity. Nearly 80% of patients are younger than 20 years. Diagnosis is made after histopathological examination, immunohistochemical studies and cytogenetic studies. Treatment includes a multidisciplinary approach with surgery as the first line followed by chemotherapy and radiotherapy.

**Keywords:** Ewing's sarcoma, EES, Peripheral neuroectodermal tumor, Paranasal sinus

### INTRODUCTION

Ewing sarcoma (ES) is an aggressive malignant round cell tumor that originates from primitive neuroectodermal cells. It is a rare disease making up only 4 % to 6 % of all primary bone tumors. Moreover, it involves head and neck region in only 1% to 4% of cases and primary sinonasal location is even rarer. It is described as a part of a family of neuro ectodermal differentiation, more specifically classified as a peripheral neuroectodermal tumor (PNET). Immunohistochemical (IHC) confirms the diagnosis of ES. Here we are reporting a case of ES involving the sinonasal tract.

### CASE REPORT

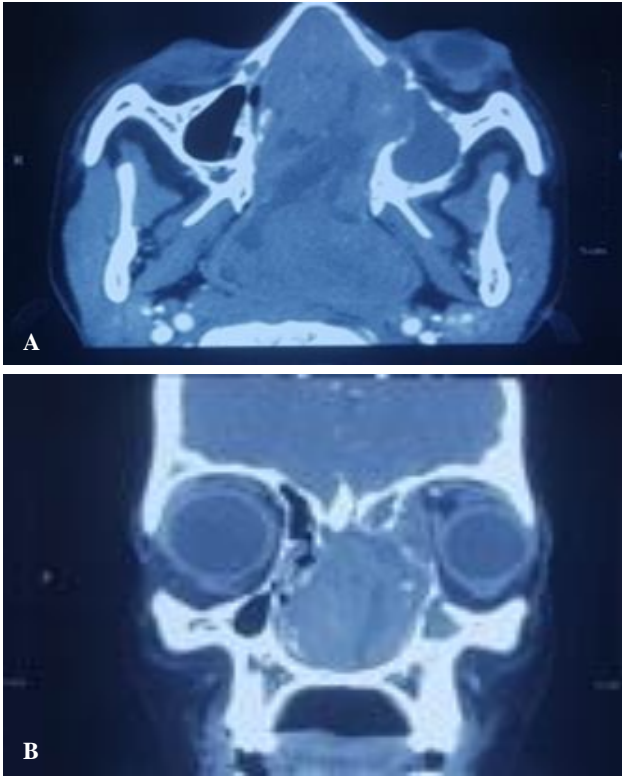
A 11-year-old male child presented to ENT OPD of Atal Bihari Vajpayee Institute of Medical Sciences and Dr RML Hospital New Delhi, a tertiary care referral hospital, with left sided nasal obstruction and intermittent epistaxis for four to five months. A pinkish friable mass was seen protruding through the left nasal cavity which was completely compressing the septum and therefore diagnostic nasal endoscopy (DNE) could not be done.

There was proptosis and associated serous otitis media on left side; however, no cheek swelling or lymph nodes were palpable.

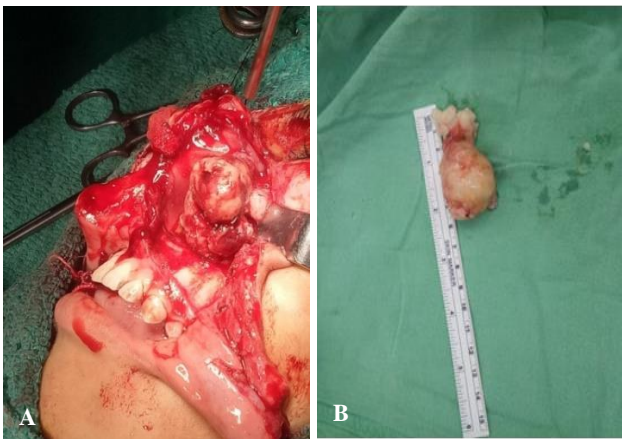Contrast enhanced computed tomographic scan of nose and PNS showed a large, heterogeneously enhancing, poorly marginated mass in the left nasal cavity, extending to left frontal, ethmoid, maxillary and sphenoid sinus (Figure 1).

There was complete obliteration of the nasopharyngeal lumen and breach in the lamina papyracea with extension of mass into medial orbital extraconal space. There was bony erosion of the posterior ethmoid and sphenoid sinus roof.

A differential diagnosis of Juvenile nasopharyngeal angiofibroma was made considering the patient's age, history and the imaging findings. Excision of the mass was planned by Weber Fergusson Dieffenbach incision and medial maxillectomy approach (Figure 2A). Specimen was sent for histopathological examination (HPE) (Figure 2B).

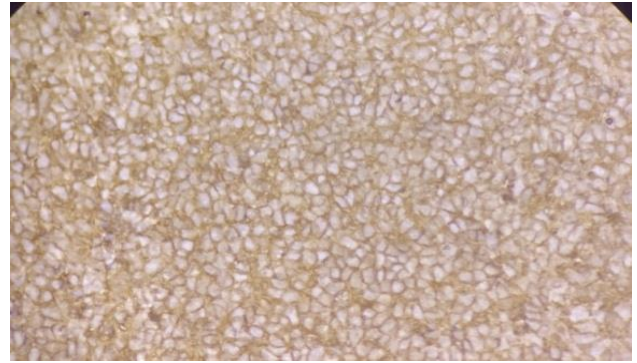


**Figure 1 (A and B): Large heterogeneously enhancing poorly margined mass is seen in the left nasal cavity, extending to left frontal, ethmoid sinuses, maxillary and sphenoid sinus with orbital extension.**

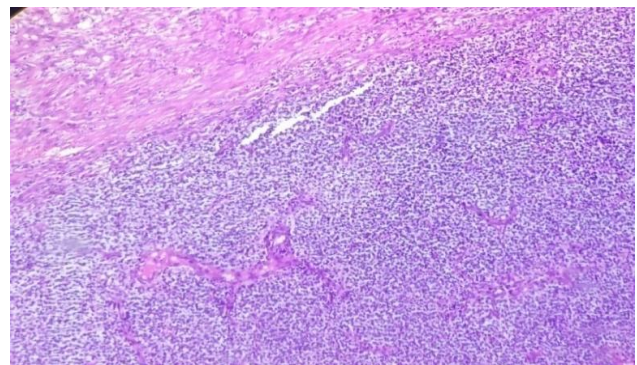


**Figure 2 (A and B): Excision of mass by medial maxillectomy approach.**

On HPE, tissue was seen partly lined by stratified squamous epithelium. Sub epithelium showed a tumor composed of monomorphic population of cells arranged in sheets with interspersed fibrous septae. The cells were small to intermediate in size showing mild pleomorphism, coarse granular chromatin, inconspicuous nucleoli and scanty amount of cytoplasm. IHC showed positivity for CD 99 and vimentin, while negative for synaptophysin, LCA, panCK and Desmin. The findings were suggestive of ES or PNET (Figure 3 and 4).



**Figure 3: CD 99 immunostain showing membranous positivity in the neoplastic cells.**



**Figure 4: Fragments of nasal mucosa with an infiltrating neoplasm composed of small round cells arranged in sheets.**

Patient was referred to the department of paediatric oncology, AIIMS New Delhi for further management. Patient is under our regular follow up.

## DISCUSSION

ES is a rare aggressive tumor that typically involves the long bones of extremities (skeletal form). The less common, extra skeletal, form involves soft tissue and rarely manifests in head and neck region.<sup>6</sup> Genetically, t (11, 22) chromosome translocation is a hall mark of diagnosis.<sup>6</sup>

Head and neck ES usually presents in patients younger than 30 yrs of age with a peak incidence in those aged 10 to 15 yrs. Males are affected more than females.<sup>5</sup> In the sinonasal tract, the differential diagnosis includes rhabdomyosarcoma, lymphoma, poorly differentiated carcinomas, melanoma, and olfactory neuroblastoma.<sup>7-9</sup> It is difficult to differentiate ES from these tumors based on clinical and radiological examination alone; hence it requires a HPE, IHC and cytogenetic analysis to reach a definitive diagnosis.<sup>1</sup>

The essential diagnostic test to differentiate ES from the many small round neoplasms is the CD99 marker, which can be detected in a specific IHC examination.<sup>1,3</sup> Lesion

that is positive for CD99 antigen & vimentin would be either alveolar rhabdomyosarcoma or ES/PNET. Staining for desmin or myogenin would help direct the clinician toward a diagnosis of ES/PNET in the former scenario and alveolar rhabdomyosarcoma in the latter. Strong membrane-only CD99 positivity would again point toward ES/PNET.<sup>5</sup>

Molecular analysis to detect chromosomal translocation can be used to confirm diagnosis of ES. Most cases of ES are characterized by translocation of the Ewing's sarcoma gene (EWS), which is located on 22q12. EWS is fused with the friend leukemia virus integration site 1 gene (FLI-1), which is located on 11q24. This fusion results in a t (11, 22) translocation which is found in 85 to 90% of the cases.<sup>3,10</sup>

Clinical manifestations of sinonasal ES include enlarging mass, nasal obstruction, rhinorrhea, and epistaxis.<sup>10</sup> Approximately 18% of the patients are presented with metastasis at time of diagnosis.<sup>11</sup> The most common sites of distant metastasis are the lungs and bones.<sup>10</sup> After diagnosis of ES is confirmed, additional necessary studies include CT and MRI to help anatomically define the lesion as a baseline before starting treatment as well as for surgical planning. Furthermore, positron-emission tomography should be performed to stage the disease and look for evidence of metastatic disease. Previous studies have found a rate of metastatic disease at diagnosis of around 12.5% for ES of the head and neck, and 20% to 30% for ES of all sites.<sup>12</sup>

The treatment of ES involves surgical resection followed by radiotherapy, and subsequent adjuvant chemotherapy.

The prognosis depends on the site of the primary tumor, the presence of distant metastasis at presentation, and the age of the patient. Researchers have found that patients younger than 15 years of age and patients with axial and sinonasal tract involvement have a better prognosis. While the 5-year survival of patients with metastases is around 22%, it is 55% in those without metastases.<sup>11,13</sup> However, the effective treatment of ES has improved the survival rate up to 86% in patients without metastatic disease.<sup>8,14</sup>

## CONCLUSION

ES is a highly malignant small round cell tumor that originates from primitive neuroectodermal cells and typically involves the long bones of extremities. Primary origin of ES in sinonasal tract is a rare presentation. Diagnosis of the disease is challenging hence it requires HPE, IHC and cytogenetic studies. Treatment includes a multidisciplinary approach with surgery as first line followed by chemotherapy and radiotherapy.

*Funding: No funding sources*

*Conflict of interest: None declared*

*Ethical approval: Not required*

## REFERENCES

1. Suzuki T, Yasumatsu R, Nakashima T, Arita S, Yamamoto H, Nakagawa T. Primary Ewing's Sarcoma of the Sinonasal Tract: A Case Report. *Case Reports in Oncology.* 2017;10(1):91-7.
2. Vaccani JP, Forte V, de Jong AL, Taylor G. Ewing's sarcoma of the head and neck in children. *Int J Pediatric Otorhinolaryngol.* 1999;48(3):209-16.
3. Liang J. Sinonasal Ewing Sarcoma: A Case Report and Literature Review. *Permanente J.* 2018;22:17086.
4. Balamuth NJ, Womer RB. Ewing's sarcoma. *The Lancet Oncology.* 2010;11(2):184-92.
5. Simons SA, Bridge JA, Leon ME. Sinonasal small round blue cell tumors- An approach to diagnosis. *Semin Diagn Pathol.* 2016;33(2):91-103.
6. Negru ME, Sponghini AP, Rondonotti D. Primary Ewing's sarcoma of the sinonasal tract, eroding the ethmoid and sphenoid sinus with intracranial extension: A rare case report. *Mol Clin Oncol.* 2015;3(4):807-10.
7. Yeshvanth SK, Ninan K, Bhandary SK, Lakshinarayana KPH, Shetty JK, Makannavar JH. Rare case of extraskeletal Ewing's sarcoma of the sinonasal tract. *Journal of Cancer Research and Therapeutics.* 2012;8(1):142-4.
8. Hafezi S, Seethala RR, Stelow EB, Mills SE, Leong IT, MacDuffet E, et al. Ewing's family of tumors of the sinonasal tract and maxillary bone. *Head Neck Pathol.* 2011;5(1):8-16.
9. Wenig BM. Undifferentiated malignant neoplasms of the sinonasal tract. *Arch Pathol Laboratory Med.* 2009;133(5):699-712.
10. Vaccani JP, Forte V, de Jong AL, Taylor G. Ewing's sarcoma of the head and neck in children. *Int J Pediatric Otorhinolaryngol.* 1999;48(3):209-16.
11. Howarth KL, Khodaei I, Karkanevatos A, Clarke RW. A sinonasal primary Ewing's sarcoma. *Int J Pediatric Otorhinolaryngol.* 2004;68(2):221-4.
12. Allam A, El-Husseiny G, Khafaga Y, Kandil A, Gray A, Ezzat A, et al. Ewing's sarcoma of the head and neck: A retrospective analysis of 24 cases. *Sarcoma.* 1999;3(1):11-5.
13. Souheil J, Skander K, Sawssen D, Sana M, Delia Y. Ewing sarcomas of the sino-nasal tract and maxillary bone. *Egyptian J Ear Nose Throat Allied Sci.* 2016;17(3):147-53.
14. La TH, Meyers PA, Wexler LH, lektiar KM, Healey JH, Laquaglia MP, et al. Radiation therapy for Ewing's sarcoma: results from Memorial Sloan-Kettering in the modern era. *Int J Radiation Oncol Biol Physics.* 2006;64(2):544-50.

**Cite this article as:** Gupta A, Sofia AS, Sen K. Ewing's sarcoma of sinonasal tract: a rare case. *Int J Otorhinolaryngol Head Neck Surg* 2020;6:565-7.