

Case Report

Cervical melioidosis: an infrequent cause of neck abscess

Nurul Alya Binti Azwan*, Ram Kumar Sharma Shanmugam, Kong Yin Teng

Department of Otorhinolaryngology, Bintulu Hospital, Sarawak, Malaysia

Received: 05 October 2019

Revised: 03 December 2019

Accepted: 04 December 2019

***Correspondence:**

Dr. Nurul Alya Binti Azwan,

E-mail: nalyaazwan@gmail.com

Copyright: © the author(s), publisher and licensee Medip Academy. This is an open-access article distributed under the terms of the Creative Commons Attribution Non-Commercial License, which permits unrestricted non-commercial use, distribution, and reproduction in any medium, provided the original work is properly cited.

ABSTRACT

Melioidosis remains as one of the rare infectious disease with high mortality and morbidity rate. It is caused by the gram-negative bacilli *Burkholderia pseudomallei* found in soil and water. We would like to share our experience of four case series that had been collected in Bintulu Hospital, Sarawak over a period of eight months starting from June 2018- January 2019. A total of four patients presented with neck abscess where the pus culture and sensitivity show *B. pseudomallei* but the blood culture and sensitivity show no culture or growth.

Keywords: Neck abscess, Melioidosis, *Burkholderia pseudomallei*, Sarawak

INTRODUCTION

Melioidosis, caused by the gram-negative *Burkholderia pseudomallei* bacillus, is an infectious disease associated with significant mortality due to an early onset of fulminant sepsis. The disease is endemic in Southeast Asia and Northern Australia and is being increasingly reported in other tropical regions of the world such as India, China, Brazil etc.¹ Diagnosis remains a challenge, as it mimics many other conditions, especially tuberculosis, hence its other name, the 'great mimicker'.²

Here we would like to share our experience of detecting *B. pseudomallei* bacillus by using paediatrics BD BACTEC bottle which to the best of our knowledge had never been reported before.

CASE REPORT

Case 1

A thirty-three years old lady with no known medical illness presented to the emergency department with

complaint of left neck swelling for 1 month. It was gradually increasing in size and associated with pain. There were no other constitutional symptoms. Clinical examination revealed a 4×3 cm circular swelling at level IV, fluctuant, erythematous and tender on palpation (Figure 1 A and B).

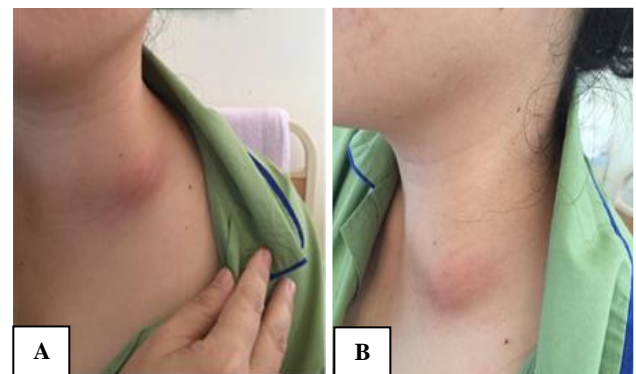

Figure 1: (A) Anterior view, (B) lateral view.

Fluctuant, erythematous, tender 4×3 cm swelling over lower one third of left sternocleidomastoid.

Patient had sought treatment at general practitioner and was treated for cervical lymphadenitis. She was given one course of antibiotics but swelling remained status quo.

Bedside needle aspiration done and samples were sent for pus for culture and sensitivity and pus for acid fast bacilli staining. Report for pus culture and sensitivity came back as *B. pseudomallei*. Patient was treated with intravenous antibiotics. Subsequently swelling reduced and patient was alive and well.

Case 2

A previously healthy fifteen years old boy came with complaint of fever for three weeks and bilateral neck swelling for one week. Swelling initially started on the left side which gradually increase in size and associated with pain. On early clinical assessment, there was swelling at level II measuring 3x2 cm with no skin changes. Blood for culture and sensitivity shows no growth.

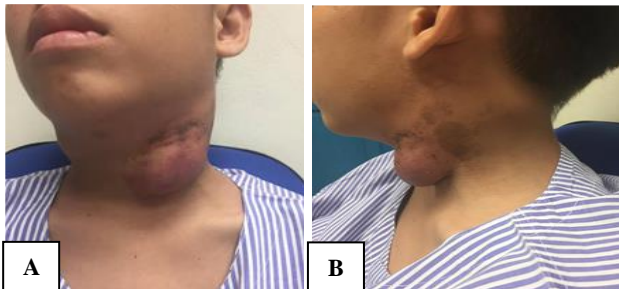


Figure 2: (A) Anterior view, (B) lateral view.

Left neck swelling at level II and III about 8x6 cm, fluctuant, erythematous skin changes and tender on palpation.

Patient was empirically treated as extrapulmonary tuberculosis. He was started with anti-tuberculosis and was discharged. He was seen back in otorhinolaryngology clinic 3 weeks later. It was noted that the left neck swelling at level II and III had tremendously increased in size about 8x6 cm, fluctuant, erythematous with underlying skin changes and tender on palpation (Figure 2 A and B).

Bedside needle aspiration was done and we are able to aspirate 16 cc of hemopurulent discharge from the swelling. Samples sent; pus for culture and sensitivity, pus for acid fast bacilli staining and pus for culture and sensitivity in BD BACTEC paediatrics bottle.

Formal report came back with pus for culture and sensitivity in BD BACTEC paediatrics bottle came back as gram negative cocci, *B. pseudomallei* while other samples shows no growth. By this time, patient had already completed day 39 of intensive phase for anti-tuberculosis drugs.

Patient was re-admitted back for intravenous antibiotics and anti-tuberculosis was stopped.

Case 3

Our next case is a two years four months old girl from Kakus. Child presented with left neck swelling for three months which was tender upon palpation. The swelling progressively increases in size. Otherwise, child had no other constitutional symptoms.

Mother had brought the child to a clinic and was treated as cervical lymphadenitis and was given oral antibiotics. However, swelling remains the same.

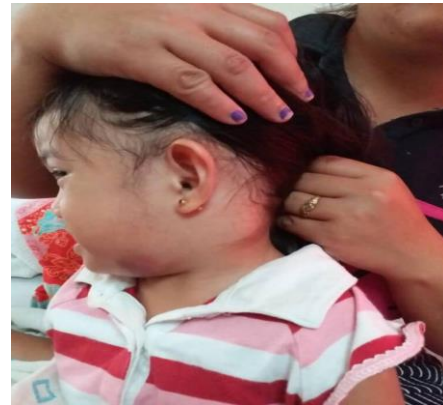

Figure 3: At level II measuring 2x1 cm, fluctuant, tender on palpation with erythematous skin changes.

On examination of the neck, noted swelling over left neck at level II measuring 2x1cm, fluctuant, tender on palpation with erythematous skin changes (Figure 3).



Figure 4: BD BACTEC paediatrics bottle.

We proceed with bedside needle aspiration and sent three samples namely pus for culture and sensitivity, pus for culture and sensitivity in BD BACTEC paediatrics bottle (Figure 4) and pus for acid fast bacilli staining.

Formal report came out as *B. pseudomallei*. All other cultures came back as no growth.

Subsequently child was given intravenous antibiotics and discharged well.

Table 1: Epidemiology and cultures report.

No. of cases	Epidemiology	Presentation	Duration	Pus culture and sensitivity	Blood culture and sensitivity	Pus culture and sensitivity in BD BACTEC paediatrics bottle
Case 1	Tatau	Left neck swelling	1 month	<i>B. pseudomallei</i>	No growth	Not taken
Case 2	Belaga	Bilateral neck swelling Fever	2 months	No growth	No growth	<i>B. pseudomallei</i>
Case 3	Kakus	Left neck swelling	3 weeks	No growth	No growth	<i>B. pseudomallei</i>
Case 4	Kakus	Bilateral neck swelling	2 months	No growth	No growth	<i>B. pseudomallei</i>

Table 2: Blood investigations and imaging.

No. of cases	WBC	ESR	AFB Stain	Melioidosis iFAT	Ultrasound abdomen
Case 1	8.2	59	No AFB	Positive 1: 640	No spleen micro abscess
Case 2	12.6	112	No AFB	Negative	No spleen micro abscess
Case 3	19.5	85	No AFB	Positive 1: 640	Spleen micro abscess
Case 4	13.7	118	No AFB	Positive 1: 1280	Spleen micro abscess

DISCUSSION

Melioidosis is a bacterial infection occurring in tropical regions of the world.¹ Factors that may influence the distribution of *B. pseudomallei* in the environment may include physical factors such as rainfall, humidity, UV radiation, and temperature; chemical factors such as soil composition, other vegetation, and the use of fertilizers; and recent soil disturbances such as excavation and plowing.³ In this case series, majority of the patient are from Tatau district mainly in Kakus area where most of the communities grow the paddy hill at a fertile land (Table 1). This condition affects all age group.

Melioidosis can affect multiple systems; however, the reports on head and neck regions are relatively uncommon.⁴ Positive histories from all cases is neck swelling mimicking a neck abscess with the earliest presentation is three weeks after the onset. It is worth mentioning that diagnosing cervical melioidosis is a challenge in view of the bacterium is often not readily isolated from clinical specimens and may not be correctly identified even when isolated. Serological tests are neither sensitive nor specific.⁴

Based on the cases discussed, blood culture and sensitivity failed to detect the bacterium and other blood investigations and ultrasound abdomen varies between patients (Table 2). However, we managed to culture *B. pseudomallei* by inserting the pus aspirate in BD BACTEC paediatrics bottle (Table 1). Thus, with positive culture, we are able to exclude other causes of neck swelling including extrapulmonary tuberculosis and treatment can be commenced immediately.

Ceftazidime is the drug of choice in systemic melioidosis. Ceftazidime (120 mg/kg/day) has shown to reduce the

mortality significantly in severe melioidosis.⁵ In all the cases, intravenous ceftazidime was given for two weeks followed by four weeks of oral Bactrim.

CONCLUSION

Early detection of cervical melioidosis is crucial to reduce morbidity and avoid misdiagnosis. We wish to highlight the detection of *B. pseudomallei* by using BD BACTEC paediatrics bottle. No surgical intervention is required, and antibiotics remains the mainstay treatment.

Funding: No funding sources

Conflict of interest: None declared

Ethical approval: Not required

REFERENCES

1. Kingsley PV, Leader M, Nagodawithana NS, Tipre M, Sathiakumar N. Melioidosis in Malaysia: A Review of Case Reports. PLoS Neglected Trop Dis. 2016;10(12):e0005182.
2. Singh M, Mahmood M. Melioidosis: The Great Mimicker. Journal of Community Hosp Intern Med Perspective. 2017;7(4):245-7.
3. Allen CC, Bart JC. Melioidosis: Epidemiology, Pathophysiology, and Management. Am Society Microbiol J. 2005;18(2):383-416.
4. How KT, Arul P. Melioidosis neck abscess: An Opportunistic Infection in Diabetes Mellitus. J Med Cases. 2016;7(8):358-60.
5. Lau SK, Sridhar S, Ho CC, Chow WN, Lee KC, Lam CW, et al. Laboratory diagnosis of melioidosis: Past, present and future. Exp Biol Med (Maywood). 2015;240(6):742-51.

Cite this article as: Azwan NAB, Shanmugam RKS, Teng KY. Cervical melioidosis: an infrequent cause of neck abscess. Int J Otorhinolaryngol Head Neck Surg 2020;6:388-90.