

## Case Report

# Tooth as a foreign body in trachea mimicking asthma in an adult patient

Ankur Batra<sup>1\*</sup>, Megha Goyal<sup>2</sup>

<sup>1</sup>Department of ENT, Yatharth Superspeciality Hospital, Noida, Uttar Pradesh, India

<sup>2</sup>Department of ENT, ESI Hospital, Sahibabad, Ghaziabad, Uttar Pradesh, India

**Received:** 04 October 2019

**Revised:** 01 December 2019

**Accepted:** 02 December 2019

### \*Correspondence:

Dr. Ankur Batra,

E-mail: [drankurbatra.orl@gmail.com](mailto:drankurbatra.orl@gmail.com)

**Copyright:** © the author(s), publisher and licensee Medip Academy. This is an open-access article distributed under the terms of the Creative Commons Attribution Non-Commercial License, which permits unrestricted non-commercial use, distribution, and reproduction in any medium, provided the original work is properly cited.

## ABSTRACT

Tracheobronchial foreign body aspiration is a life threatening emergency that requires prompt removal, but sometimes it may remain undetected because of atypical history, or misleading clinical and radiological findings. We present a case report of a 32 years old female who presented with progressive dyspnoea, misdiagnosed as asthma, not responding to bronchodilators and finally diagnosed as foreign body in trachea. The inclusion of foreign body aspiration in the differential for such patients allows for early recognition and appropriate management.

**Keywords:** Foreign body, Trachea, Tracheal stenosis, Tooth, Asthma

## INTRODUCTION

Tracheobronchial foreign body aspiration is a life threatening emergency that requires prompt removal, but sometimes it may remain undetected because of atypical history, or misleading clinical and radiological findings. Aspiration of foreign bodies into airway is rare occurrence in adults but an important consideration in certain clinical presentation like chronic cough, dyspnoea, hemoptysis, asthma like symptoms that are often diagnosed as obstructive airway disease and do not respond to anti-inflammatory or bronchodilator therapy.<sup>1,2</sup>

We describe rare cause of tracheal stenosis and chronic stridor caused by aspiration of foreign body misdiagnosed as asthma.

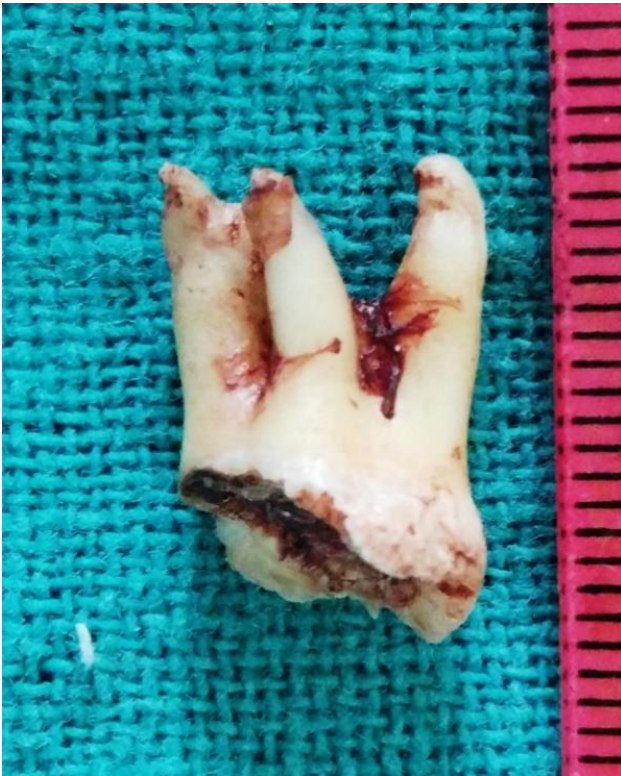## CASE REPORT

A 32-year-old lady presented to the emergency Department of Otorhinolaryngology with stridor for past

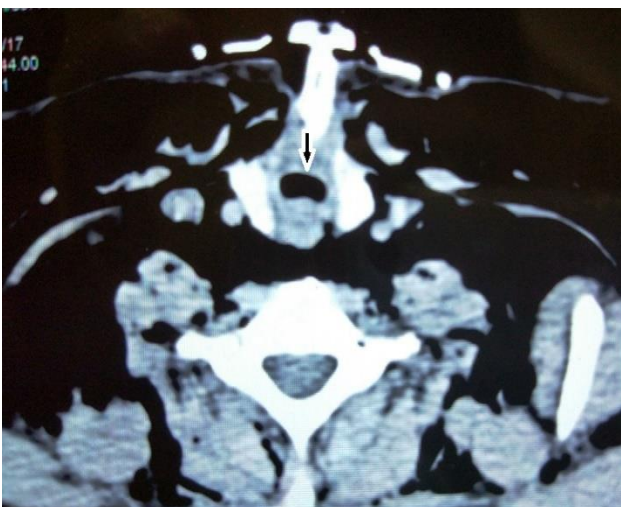1 month. The patient had difficulty in breathing for past 6 months which gradually progressed to biphasic stridor for past 1 month. The patient is non-smoker and had no prior history of coughing, frequent lower respiratory tract infection, tuberculosis, intubation or external trauma to the neck. She was being treated for asthma by the general practitioner who advised a chest radiograph which turned out to be normal. Her IgE levels were raised. Further management included MRI of neck and chest. The MRI showed soft tissue density in subglottis and upper trachea. Fiberoptic laryngoscopy (FOL) revealed reddish polypoidal mass in subglottis occupying almost 90% of the circumference 1 cm below vocal cords and the vocal cords had normal mobility. On pulse oximetry, oxygen saturation was 85% and bilaterally decreased air entry with conducted sounds in lungs on auscultation.

Decision was taken to perform emergency tracheostomy under local anesthesia. A gritty sensation was felt while giving tracheal incision over 2<sup>nd</sup>-3<sup>rd</sup> tracheal ring. As trachea was opened up, a tricuspid molar tooth was seen embedded in polypoidal tissue and removed (Figure 1).

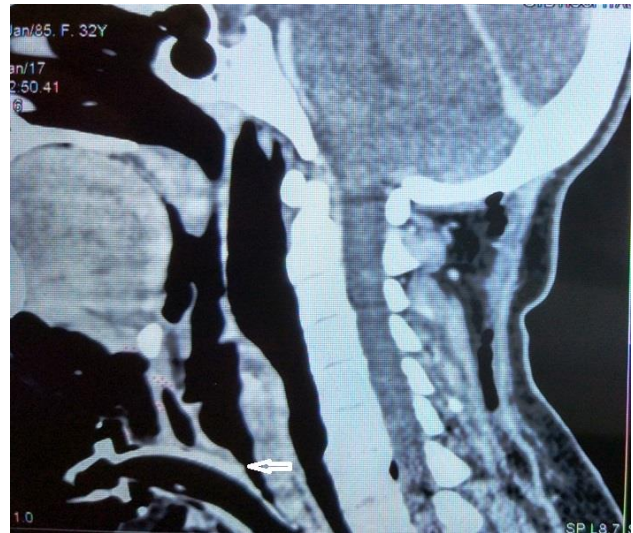
Post tracheostomy her saturation was 99% on room air and was stable. Careful and detailed history in retrospect revealed tooth extraction 6 months back following which she developed dyspnoea and later progressed to stridor. Histopathology of polypoidal tissue revealed granulation tissue. She was given intravenous prednisolone for one week and a computed tomography (CT) scan was done which revealed tracheal stricture of around 2 mm thick and 2 cm below the level of vocal cords, covering around 70% of the lumen (Figure 2-3). FOL was repeated which confirmed the radiographic findings.



**Figure 1: Foreign body (tooth) removed from trachea.**



**Figure 2: CT scan of neck showing stenosis (arrows)-axial view.**



**Figure 3: CT scan of neck showing stenosis (arrows)-sagittal view.**

She was then taken up for granulation tissue removal and balloon stricture dilatation with mitomycin C application under general anesthesia. Patient was decannulated on 3<sup>rd</sup> post-op day and discharged. Repeat FOL at 2 weeks showed normal subglottis. Patient is under follow-up for 1 year and is doing well.

## DISCUSSION

Chronic dyspnoea and stridor are frequently seen ENT emergencies. The main causes of chronic stridor are laryngeal malignancy, chronic laryngitis (e.g. inflammatory, tuberculosis, granulomatous) and in rare cases, foreign body aspiration into the airway. Laryngeal malignancy is commonly seen in smokers and drinkers, aged between 30-60 years. The most frequently seen manifestation is gradual onset hoarseness (glottal tumors), dyspnoea and stridor in advanced cases.<sup>3</sup>

In long standing case of stridor, granulomatous conditions of larynx like amyloidosis, sarcoidosis etc. should always be taken into consideration. The clinical presentation varies; dyspnoea, stridor, dysphonia, dysphagia may occur but almost a third of patients are asymptomatic. In India, tuberculosis should always be kept as a differential diagnosis. Laryngeal tuberculosis patients may present in stridor (3.8%) but majority present as dysphonia (84.6%). The glottis is the most frequent site of involvement in 80.8% of the cases, while the subglottis is involved in 3.8% of the patients. The laryngoscopy findings are ulceration (50%), granuloma (50%), leukoplakia (38.5%) and non-specific inflammation (26.9%).<sup>4</sup>

Tracheobronchial foreign bodies aspiration in adults is a rare occurrence and is commonly overlooked. Laryngeal foreign bodies present a rare, dramatic circumstance with prevalence rates ranging from 2% to 11% in cases where the airways are involved. The risk factors for airway

foreign body in adults include psychiatric and neurological disorders, stroke, seizures, severe trauma, a history of heavy alcohol consumption, sedative use, poor dentition, dental procedure complications and advanced age.<sup>5-8</sup> In the study carried out by Limper et al, dental objects are found to be the second most frequent cause of aspiration.<sup>7</sup> Dental aspirations could occur during dental procedures, maxillofacial trauma, stroke etc. Initial presentation of aspiration includes choking sensation with an intermittent dry cough. Although a history of choking episodes may increase suspicion of aspiration into the airway, it may not always be apparent in all patients.<sup>9</sup> The most common presenting symptoms in case of long-standing aspiration are respiratory distress, chronic cough, voice problems, recurrent lung infections, abscess and complications like bronchiectasis. The failure of asthma to respond to conservative management and gradual worsening of symptoms should raise clinical suspicion of incorrect diagnosis. So, a detailed history and clinical examination forms the mainstay of diagnosis in such patients which is supplemented by performing radiological studies.

Radiological assessment should be performed if there is suspicion of aspiration. A postero-anterior and lateral radiograph of chest with neck should be performed after getting anamnesis and physical examination if there is suspicion of foreign body aspiration.<sup>2</sup> The most common radiographic findings are unilateral hyperaeration, mediastinal shift, atelectasis and pneumonic infiltration. If the aspirated material is radiopaque, it could be seen directly in postero-anterior radiograph. However, in case of getting the exact size and location of the foreign body, lateral and oblique graphs should be used. Normal views in postero-anterior lung graphs have been reported in 25% of the cases.<sup>10</sup> In a review of 59 patients, Limper et al found that routine chest radiograph are successful in locating aspirated foreign bodies in 41 of 57 cases.<sup>7</sup> CT is clearly more accurate than chest radiography in detecting radiolucent foreign bodies and Pinto et al advocated CT to be performed in patients with low level of clinical suspicion of foreign body aspiration in whom chest radiograph is negative.<sup>2</sup>

The failure of asthma to respond to bronchodilators and corticosteroids should raise clinical alternate diagnoses. The tooth was radio-opaque and in retrospect could had been visualized radiographically.

## CONCLUSION

This case shows the importance of a detailed history, clinical examination and further investigation in patients with obstructive airway disease who are unresponsive to routine therapies. The radiological investigation should

not only include chest but neck as well. The inclusion of foreign body aspiration in the differential for such patients allows for early recognition and appropriate management, thereby decreasing the incidence of costly and unnecessary complications.

*Funding: No funding sources*

*Conflict of interest: None declared*

*Ethical approval: Not required*

## REFERENCES

1. Kam JC, Doraiswamy V, Dieguez JF, Dabu J, Cholankeril M, Govind M, et al. Foreign Body Aspiration Presenting with Asthma-Like Symptoms. *Case Reports Med.* 2013;317104:4.
2. Pinto A, Scaglione M, Pinto F, Guidi G, Pepe M, Del Prato B, et al. Tracheobronchial aspiration of foreign bodies: current indications for emergency plain chest radiography. *Radiol Med.* 2006;111(4):497-506.
3. Thekdi AA, Ferris RL. Diagnostic assessment of laryngeal cancer. *Otolaryngol Clin North Am.* 2002;35(5):953-69.
4. Wang CC, Lin CC, Wang CP, Liu SA, Jiang RS. Laryngeal tuberculosis: a review of 26 cases. *Otolaryngol Head Neck Surg.* 2007;137(4):582-8.
5. Chen CH, Lai CL, Tsai TT, Lee YC, Perng RP. Foreign body aspiration into the lower airway in Chinese adults. *Chest.* 1997;112(1):129-33.
6. Al-Majed SA, Ashour M, al-Mobeireek AF, al-Hajjaj MS, Alzeer AH, Al-Kattan K. Overlooked inhaled foreign bodies: late sequelae and the likelihood of recovery. *Respir Med.* 1997;91(5):293-6.
7. Limper AH, Prakash UB. Tracheobronchial foreign bodies in adults. *Ann Intern Med.* 1990;112(8):604-9.
8. Zissin R, Shapiro-Feinberg M, Rozenman J, Apter S, Smorjik J, Hertz M. CT findings of the chest in adults with aspirated foreign bodies. *Eur Radiol.* 2001;11(4):606-11.
9. Baharloo F, Veyckemans F, Francis C, Bieltlot MP, Rodenstein DO. Tracheobronchial foreign bodies: presentation and management in children and adults. *Chest.* 1999;115(5):1357-62.
10. Cataneo AJ, Cataneo DC, Ruiz RL Jr. Management of tracheobronchial foreign body in children. *Pediatr Surg Int.* 2008;24(2):151-6.

**Cite this article as:** Batra A, Goyal M. Tooth as a foreign body in trachea mimicking asthma in an adult patient. *Int J Otorhinolaryngol Head Neck Surg* 2020;6:403-5.