

Original Research Article

Outcomes of type III tympanoplasty: our experience

Ravishankar Chandrashekhar, Ramya Bandadka*

Department of Otorhinolaryngology, Bangalore Medical College and Research Institute, Bengaluru, Karnataka, India

Received: 23 August 2019

Revised: 20 November 2019

Accepted: 02 December 2019

***Correspondence:**

Dr. Ramya Bandadka,

E-mail: ramyab187@gmail.com

Copyright: © the author(s), publisher and licensee Medip Academy. This is an open-access article distributed under the terms of the Creative Commons Attribution Non-Commercial License, which permits unrestricted non-commercial use, distribution, and reproduction in any medium, provided the original work is properly cited.

ABSTRACT

Background: Type III tympanoplasty involves complete disease clearance from middle ear cleft and retaining or improving the serviceable hearing by ossiculoplasty. Various auto and allografts have been used with variable outcomes. The objective of the study was to evaluate hearing improvement and healing of cavity in patients who underwent type III tympanoplasty.

Methods: A retrospective chart review of 21 patients who underwent type III tympanoplasty at Bowring and Lady Curzon Hospital from January 2018 to December 2018 was done. In 7 patients autologous incus, 6 tragal cartilage and 8 teflon prosthesis was used for ossiculoplasty. Intra and postoperative events were assessed. Pure tone audiograms done after 3 and 6 months were compared.

Results: 15 patients who underwent canal wall down procedure (CWDP) had a mean hearing gain of 20.33 dB and 26.67 dB while in 5 patients of canal wall up procedure (CWUP) group mean hearing gain was 22.5 dB and 27.5 dB at 3 and 6 months after surgery respectively. Hearing gain was similar in both groups irrespective of the prosthesis used. Autologous materials were used in most of the CWUP with intact stapes and teflon prosthesis was used in majority of CWDP where only mobile stapes foot plate was present. Prosthesis extrusion was not encountered in any of our cases so far in this series.

Conclusions: The post-operative hearing gain with autologous incus, tragal cartilage and teflon middle ear prosthesis are similar. Teflon prosthesis is an effective material for ossiculoplasty, especially useful when incus and stapes are absent while autologous incus or tragal cartilage are preferred in cases with intact stapes head.

Keywords: Type III tympanoplasty, Autologous incus, Teflon prosthesis

INTRODUCTION

Chronic otitis media (COM) is a common otologic disease in India often associated with conductive hearing loss due to tympanic membrane perforation and in some cases ossicular chain discontinuity or fixation.¹ Along with complete disease clearance hearing preservation and/or improvement by ossiculoplasty should be an important goal in tympanomastoidectomies to enhance the quality of life and productivity of patients.

Incus is the most common ossicle affected in COM due to its delicate anatomy and poor blood supply.²⁻⁴ In such

cases type III tympanoplasty can be performed for better hearing gains. In type III tympanoplasty ossicular prosthesis is placed on the stapes superstructure (myringostapediopexy (MSP), IIIa) or mobile stapes footplate (myringoplastinopexy (MPP), IIIb) and the graft (neotympanum).

Ossiculoplasty is done using autologous materials such as incus, malleus, cartilage or synthetic materials like teflon, titanium, hydroxyapatite, and plastipore.^{5,6} Advantages of autologous materials are good biocompatibility, low extrusion rate, low cost and easy availability.⁷ Disadvantages being uncertain disease free state of

remnant ossicle, resorption and need for surgical expertise and time for refashioning the prosthesis.⁸ Synthetic prosthesis have good strength and sound conducting property but are often not preferred due to high cost, high extrusion/displacement rates and unsatisfactory hearing gains.⁵

Our study aims to evaluate the efficacy in terms of postoperative hearing gain and complications suffered in patients who underwent type III tympanoplasty using autologous incus/tragal cartilage and teflon prosthesis.

METHODS

A retrospective chart review of 21 patients who underwent type III tympanoplasty at Bowring and Lady Curzon hospital from January 2018 to December 2018 was done. Patients between 10 to 60 years who had undergone type III tympanoplasty for COM with purely conductive hearing loss and complete regular documented follow-up were included in the study. Patients with sensorineural or mixed hearing loss, traumatic ossicular chain discontinuity, complications of CSOM, uncontrolled diabetes or immunocompromised status or cleft palate and revision cases were excluded from the study. Information regarding the indications, type of surgery, prosthesis used and any adverse post-operative events encountered were collected. Pre-operative pure tone average of hearing thresholds in dB at 500, 1000, 2000 Hertz and during follow-up at 3 and 6 months intervals and otoendoscopic examination findings were tabulated.

After univariate comparison of pre- and postoperative air-bone gap (ABG) in the different subgroups, multivariate ANOVA was conducted in order to verify the

independence of the prognostic factors, both found and known. P values less than 0.05 were considered statistically significant for all the bilateral tests used.

RESULTS

Among the twenty-one patients who underwent type III tympanoplasty majority (13) were males. Most of the patients were in the 2nd and 3rd decade of life.

Out of 21 patients, 15 had undergone canal wall down procedure (CWDP) while the remaining 6 patients Canal wall up procedure (CWUP) (atticotomy with conchal cartilage reconstruction of outer attic wall). For the ossiculoplasty, prosthesis used were autologous incus (7), autologous tragal cartilage (6) and teflon middle ear prosthesis (8).

Among 6 patients who underwent CWUP, 5 had intact mobile stapes. Autologous grafts were used to reconstruct ossicular chain in most of these cases. In 67% of CWDP group MPP mainly with teflon prosthesis was performed as in these cases only mobile stapes footplate was present.

Tables 1 and 2 show hearing gain at 3 and 6 months post-surgery using the different graft materials in MSP or MPP.

Figure 1 shows hearing gain at 3 and 6 months with various prosthesis used. Autologous Incus showed a hearing gain of 22.05 dB and 25.5 dB while autologous tragal cartilage 15.8 dB and 25 dB, teflon middle ear prosthesis 23 dB and 28.5 dB at 3 and 6 month post op respectively.

Table 1: Hearing gain at 3 months post-operative.

	Pre op ABG (dB)	Post op ABG (dB)	Hearing gain (dB)		Pre op ABG (dB)	Post op ABG (dB)	Hearing gain (dB)
MSP	44	24.5	19	Autologous incus	43	20	22.5
				Tragal cartilage	43	28.3	13.3
				Teflon prosthesis	47	26.6	20
MPP	54	30.9	22.7	Autologous incus	53	31.6	21.6
				Tragal cartilage	52	33.3	18.3
				Teflon prosthesis	55	29	26

Table 2: Hearing gain at 6 months post-operative.

	Pre op ABG (dB)	Post op ABG (dB)	Hearing gain (dB)		Pre op ABG (dB)	Post op ABG (dB)	Hearing gain in (dB)
MSP	44	19	25	Autologous incus	43	15	28
				Tragal cartilage	43	20	23
				Teflon prosthesis	47	23	24
MPP	54	25	29	Autologous incus	53	30	23
				Tragal cartilage	52	25	27
				Teflon prosthesis	55	22	33

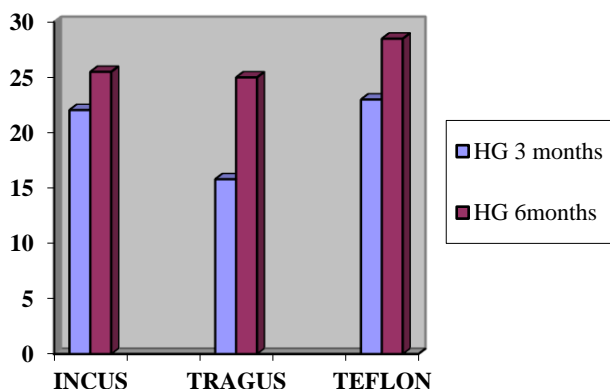


Figure 1: Hearing gain with various prosthesis used.

Hearing gain in CWUP cases was 22.5 dB and 27.5 dB while in CWDP cases 20.33 dB and 26.67 dB at 3 and 6 months post-operative as shown in Figure 2.

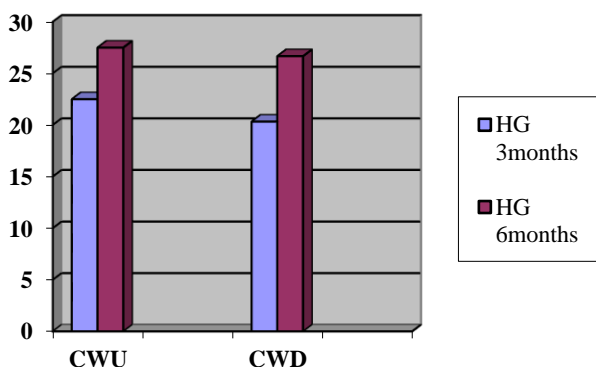


Figure 2: Hearing gain based on type of surgery.

Post-operative oto endoscopy showed granulation in two cases which was mainly observed at the bony cartilaginous junction of external auditory canal. Both the patients had undergone CWUP. These patients were successfully treated with local antibiotic and steroid drops. Granulation was probably due to the inadequate flap cover of the bone of external auditory canal. No cases of extrusion of the prosthesis were noted in this series so far.

DISCUSSION

Various graft materials are used for ossiculoplasty which include auto grafts and allograft (bioactive, bioinert and biocompatible).⁹ Each have their own merits and demerits. Autologous grafts are preferred by some surgeons due to their easy availability and lower extrusion rates while allografts provide better prosthesis stability and ease of surgery.¹⁰

The closure of ABG achieved by all the different modalities of ossicular reconstruction in this study was

similar (Figure 1). There was no statistically significant difference observed when different prosthesis was employed ($p > 0.05$).

Mean hearing gain in CWUP and CWDP groups which was achieved at the end of 3 months was 22.5 dB and 20.33 dB respectively. This improvement continued during the next 3 months and the mean was 27.5 dB and 26.67 dB. Hence, we can infer from this observation that optimal hearing gain was seen at the end of 6 months.

In two cases (one CWDP with teflon total ossicular replacement prosthesis (TORP) and the other CWUP with incus MSP) the hearing gained at 3 months was lost subsequently. The reason for this could not be found as these patients refused a second look surgery. This could be possibly due to displacement of prosthesis.¹¹

The hearing gain in CWUP was relatively better than CWDP though not statistically significant reinforcing the usefulness of retaining the posterior meatal wall without compromising disease clearance for better hearing outcomes (Figure 2). This is similar to the results published by Faramarzi et al where the success rate in CWUP was more than CWDP patients but the difference was not significant.¹² However CWUP may not be feasible in all scenarios because of extent of disease – as more extensive involvement of mastoid requires CWDP for complete disease clearance.

In a retrospective chart review of 17 cases of tympanomastoidectomies using titanium prosthesis, it was found that CWUP with partial ossicular replacement prosthesis and CWDP with TORP reconstruction showed best hearing outcomes.¹³

CONCLUSION

The post-operative hearing gain with autologous incus, tragal cartilage and teflon middle ear prosthesis were similar. Autologous incus/tragal cartilage though readily available, refashioning them is labour intensive and time consuming. Teflon middle ear prosthesis is an effective material for ossiculoplasty especially useful when incus and stapes are absent with a mobile stapes footplate. Autologous incus or tragal cartilage are preferred in cases with intact stapes head and CWUPs. A prospective study with larger sample size and longer follow-up period is recommended.

Funding: No funding sources

Conflict of interest: None declared

Ethical approval: Not required

REFERENCES

1. Mudhol RS, Naragund AI, Shruthi VS. Ossiculoplasty: Revisited. Indian J Otolaryngol Head Neck Surg. 2013;65(3):451-4.

2. Bihani A, Jyoti D. Use of incus as an interposition graft in ossiculoplasty for type IIb tympanoplasty. *Int J Clin Trial.* 2015;2(2):43-6.
3. O'Reilly RC, Cass SP, Hirsch BE, Kamerer DB, Bernat RA, Poznanovic SP. Ossiculoplasty using incus interposition: Hearing results and analysis of the middle ear risk index. *Otol Neurotol.* 2005;26:853-8.
4. Athanasiadis-Sismanis A, Poe DS. Ossicular chain reconstruction. In: Gulya AJ, Minor LB, Poe DS, eds. *Glasscock-Shambaugh Surgery of the ear.* 6th ed. Ch. 29. USA: People's Medical Publishing House; 2010: 489-500.
5. Mahanty S, Maiti AB, Naskar S, Das SK, Mandal S, Karmakar M. A comparative study of outcome of ossiculoplasty using cartilage graft, bone and different alloplasts in chronic otitis media. *Indian J Otol.* 2015;21:144-8.
6. Naragund AI, Mudhol RS, Harugop AS, Patil PH. Ossiculoplasty with autologous incus versus titanium prosthesis: A comparison of anatomical and functional results. *Indian J Otol.* 2011;17:75-9.
7. Mardassi A, Deveze A, Sanjuan M, Mancini J, Parikh B, Elbedeiwy A, et al. Titanium ossicular chain replacement prostheses: prognostic factors and preliminary functional results. *Euro Annals Otorhinolaryngol Head Neck Dis.* 2011;128:53-8.
8. Kartush JM. Ossicular chain reconstruction. Capitulum to malleus. *Otolaryngol Clin North Am.* 1994;27:689-715.
9. Thamizharasan P, Ravi K. Comparative study of autologous ossicular graft versus titanium prosthesis (torp and porp) in ossiculoplasty. *Bengal J Otolaryngol Head Neck Surg.* 2017;25(1):1-7.
10. Zeitler DM, Lalwani A. Are postoperative hearing results better with titanium ossicular reconstruction prostheses?. *Laryngoscope.* 2010;120(1):2-3.
11. Cox MD, Russell JS, Dornhoffer JL. TORP ossiculoplasty outcomes with and without a stapes footplate prosthesis. *Otolaryngol Head Neck Surg.* 2015;152(3):501-5.
12. Faramarzi M, Jahangiri R, Roosta S. Comparison of titanium vs. polycel total ossicular replacement prosthesis. *Iran J Otorhinolaryngol.* 2016;28(85):89-97.
13. Sayal A, Taneja V, Gulati A. Preliminary hearing results of tympanomastoidectomies using titanium prostheses: scenario in a developing country. *Int J Otolaryngol Head Neck Surg.* 2013;2(5):195-200.

Cite this article as: Chandrashekhar R, Bhandarkar R. Outcomes of type III tympanoplasty: our experience. *Int J Otorhinolaryngol Head Neck Surg* 2020;6:287-90.