

## Original Research Article

DOI: <http://dx.doi.org/10.18203/issn.2454-5929.ijohns20195697>

# Role of anatomical variations in chronic rhinosinusitis on diagnostic nasal endoscopy and computed tomography scan of paranasal sinuses

Falguni J. Parmar\*, Avani D. Patel

Department of ENT, Parul Institute of Medical Science and Research, Waghodia, Gujarat, India

**Received:** 14 August 2019

**Revised:** 20 November 2019

**Accepted:** 02 December 2019

### \*Correspondence:

Dr. Falguni J. Parmar,

E-mail: [drfalguni89@gmail.com](mailto:drfalguni89@gmail.com)

**Copyright:** © the author(s), publisher and licensee Medip Academy. This is an open-access article distributed under the terms of the Creative Commons Attribution Non-Commercial License, which permits unrestricted non-commercial use, distribution, and reproduction in any medium, provided the original work is properly cited.

## ABSTRACT

**Background:** Diagnostic nasal endoscopy (DNE) and computed tomography (CT) of para nasal sinuses play an important role in the diagnosis and treatment of chronic rhinosinusitis (CRS). The aim and objective of the study is to see the anatomical variations of the sinonasal region in CRS on DNE and CT paranasal sinuses (PNS).

**Methods:** A descriptive type retrospective study of 30 patients attending the ENT outpatient department of our tertiary care center clinically diagnosed as CRS with symptoms persisting for 12 weeks or more, along with previously failed medical management, including topical nasal steroids, systemic decongestant and extended courses of antibiotics and who were willing to undergo endoscopic sinus surgery are included.

**Results:** Majority of the patients had septal deviation either an anterior or posterior deviation but majority of the cases are asymptomatic for the deviation. Anatomical variations of uncinate process, middle turbinate, inferior turbinate, frontal recess, agger nasi cells, haller cells were studied as well.

**Conclusions:** Prolonged duration of rhinosinusitis symptoms (more than 8-12 weeks) is the primary reason to evaluate a patient for CRS and making the choice between CT PNS or DNE is patient and disease dependent. Understanding the advantages and disadvantages of each helps us realize that they are of synergistic in nature and not competitive.

**Keywords:** CT scan paranasal sinus, Endoscopic sinus surgery, Paranasal sinuses, Septal deviation, Paradoxical middle turbinate, Concha bullosa

## INTRODUCTION

Chronic rhinosinusitis is a common condition in which the cavities around nasal sinuses become inflamed for at least 12 weeks, despite treatment attempts. This condition interferes with drainage and causes mucus buildup. Microorganisms play a very significant role in the persistence and origination of this inflammatory process, although their exact role is unclear. According to the diagnostic guidelines by the Rhinosinusitis Task Force of the American Academy of Otolaryngology, Head and Neck Surgery and revised by the Sinus and Allergy Health Partnership, chronic rhinosinusitis is diagnosed by clinical symptoms and signs which are divided into minor

and major criteria. The major symptoms of chronic sino nasal diseases includes nasal obstruction, nasal discharge or purulence, Facial pressure or pain, fever, hyposmia or anosmia. The minor symptoms includes headache, halitosis, fatigue and dental pain.<sup>1,2</sup>

The purpose of this retrospective study of anatomical variations of nose and paranasal sinuses in computed tomography (CT) scan and chronic sinusitis is to determine the mucosal abnormalities and bony anatomic variations of paranasal sinus and assess the possible pathogenicity of these findings in patients undergoing evaluation for sinusitis. The revolutionary changes in the surgical treatment of rhino sinusitis in recent years,

particularly in endoscopic surgery, require the surgeons to have detailed knowledge of the anatomy of the lateral nasal wall, paranasal sinuses and surrounding vital structures and of the large number of anatomical variants in the region, many of which are detectable only by the use of CT. Presumably these variations might induce osteomeatal obstruction, preventing mucus drainage and predisposing to chronic rhino sinusitis. Identifying predisposing factors for chronic sinusitis are therefore very important.<sup>3,4</sup>

If a person has had two or more of the symptoms listed for a period of at least 12 weeks; direct endocavitary observation enables the anatomical and functional state of the mucosa to be evaluated, as well as that of the ostial region. Sinus endoscopy is an office procedure which allows the clinician to take a sample of mucus from inside the sinuses to examine under the microscope. CT paranasal sinuses are aimed at delineating the extent of the disease; define any anatomical variants and relationship of the sinuses with the surrounding important structures. Recently, combination of diagnostic nasal endoscopy (DNE) and CT paranasal sinuses in the coronal plane has become the corner stone in the evaluation of the paranasal sinus disease. This is the basis for the concept of functional endoscopic sinus surgery.<sup>1,2</sup>

Functional endoscopic sinus surgery is being preferred as treatment of choice for chronic sinusitis. Surgeons should require a detailed anatomy of osteomeatal complex of nose and paranasal sinuses and its anatomical variations to prevent complications during surgery.<sup>1,2</sup>

### Objective

The objectives of the study is to see the Role of anatomical variations in chronic rhinosinusitis on DNE and CT paranasal sinuses. It focusses on the utility of both.

### METHODS

Descriptive type using Graph Pad retrospective study of 30 patients attending the ENT outpatient department of our tertiary care center, Parul Institute of Medical Science and Research during January 2018 to January 2019, clinically diagnosed as chronic rhinosinusitis with symptoms persisting for 12 weeks or more. Along with previously failed medical management, including topical nasal steroids, systemic decongestant and extended courses of antibiotics and who were willing to undergo endoscopic sinus surgery are included.

### Exclusion criteria

Patients with acute sinusitis, below 10 years of age, pregnant, or already operated for sino nasal diseases, with complications of chronic rhinosinusitis and with sinusitis of dental origin/previous history of facial trauma or

sinonasal malignancy confirmed with histopathology were excluded from the study.

The cases selected were subjected to detailed history taking and examination. Routine investigations were carried out. All the patients in active stage of the disease were treated with course of antibiotic, systemic antihistamines and local decongestants and other medical conditions. No patient received systemic steroid therapy or immunotherapy. Each patient underwent DNE and CT paranasal sinuses after the active stage of the disease was treated.

### RESULTS

#### Age distribution

In the present study, age of patients varies between 16 and 60 years, with the maximum number of patients in 17-22 years age group (30%). The mean age group in the present study is 30.2 years.

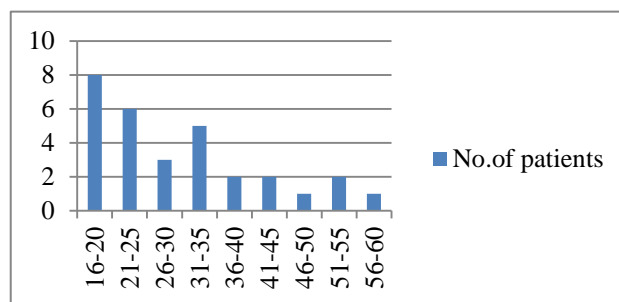


Figure 1: Age distribution of patients.

#### Sex distribution

In the present study of 30 patients, 19 cases are male while 11 cases are females which accounts for 63% being males and 37% being females and have a male predominance than female.

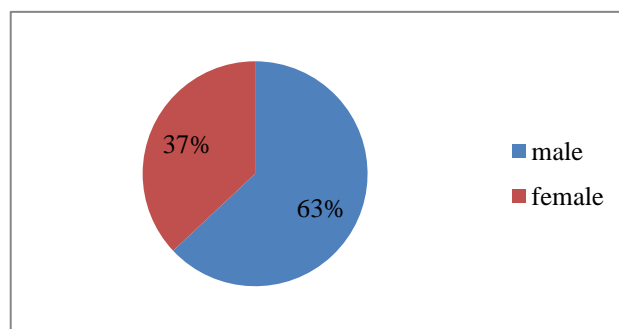


Figure 2: Sex distribution.

#### Symptoms

Nasal obstruction was the commonest symptom which is present in 27 (90%) cases. The next frequently occurring

complaint is nasal discharge present in 25 (83%) cases. Middle meatal secretions which are one of the diagnostic criteria for chronic rhinosinusitis which is seen only in DNE and not by CT scan thereby indicating DNE has to be done in all cases.

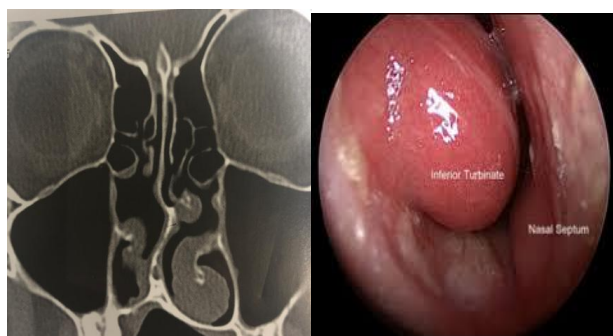
**Table 1: Percentage of nasal symptoms.**

Symptoms	No. of cases	%
Nasal obstruction	27	90
Nasal discharge	25	83
Headache	20	67
Sneezing	5	17
Anosmia/hyposmia	2	7

Majority of the patients (93.3%) in our study had septal deviation either an anterior or posterior deviation but majority of the cases is asymptomatic for the deviation.

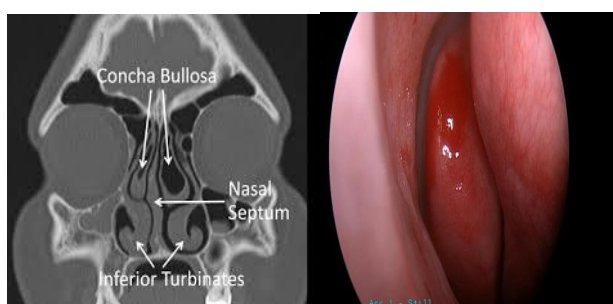
CT scan is having a better diagnostic value for deviated nasal septum (DNS) than DNE mainly in cases of gross anterior DNS and extensive nasal mass occupying lesion.

66.6% had hypertrophy of the inferior turbinate and could be visualized and analyzed by CT scan as well as DNE but DNE has a better diagnostic value than CT scan because it shows the mucosal changes.



**Figure 3 (A): Inferior turbinate hypertrophy in CT paranasal sinuses and nasal endoscopy.**

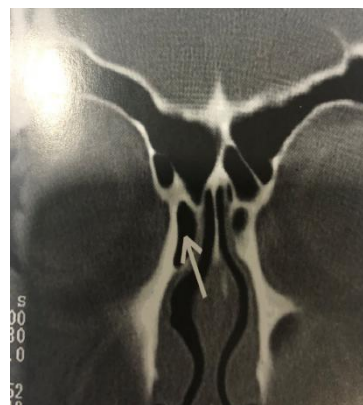30% had middle turbinate variations like concha bullosa and paradoxical and were better seen on CT scan than DNE.



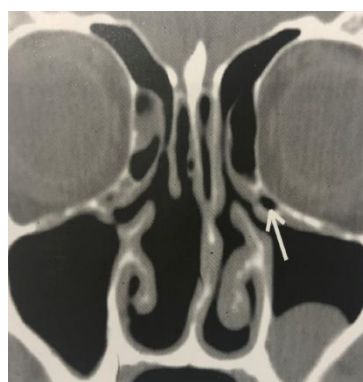
**Figure 3 (B): Concha bullosa in CT paranasal sinuses and nasal endoscopy.**

Agger nasi cells are well assessed by CT scan but only over pneumatized agger nasi cells are appreciated on DNE. Thereby indicating CT scan has a better diagnostic value indicating for agger nasi cells.

Haller cells could only be appreciated by CT scan. Thereby indicating DNE has no diagnostic value at all for evaluating Haller cells.

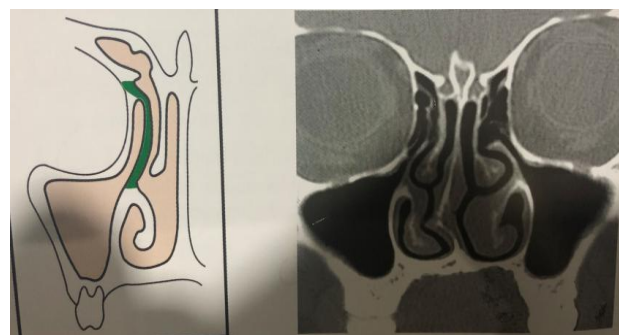


**Figure 3 (C): Agger nasi cell.**

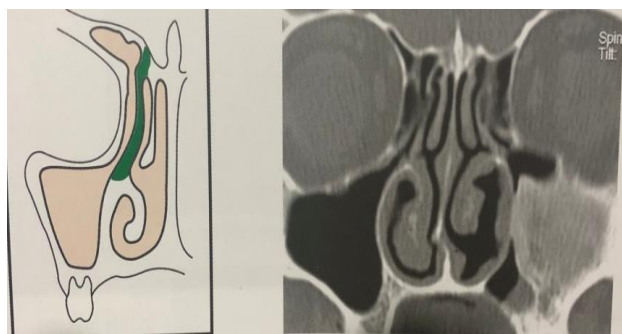


**Figure 3 (D): Haller cell.**

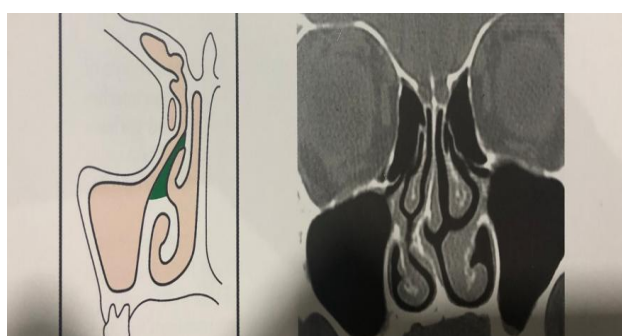Superior attachment of uncinate process can be appreciated both in CT scan and DNE. But DNE being a blind procedure to assess the attachments to lamina papyracea and skull base, thus CT scan gives a much better visualization of its attachments.



**Figure 3 (E): Uncinate process attached to lamina papyracea.**



**Figure 3 (F): Uncinate process attached to skull base.**



**Figure 3 (G): Uncinate process attached to middle turbinate.**

Frontal recess can be evaluated better by CT than DNE.

**Table 2: Anatomical variation in nose.**

Anatomical variations	No. of cases	%
DNS	28	93
Variations in inferior turbinate	20	67
Variations in middle turbinate	9	30
Variations in uncinate process	7	21
Agger nasi cell	1	3
Haller cell	0	0

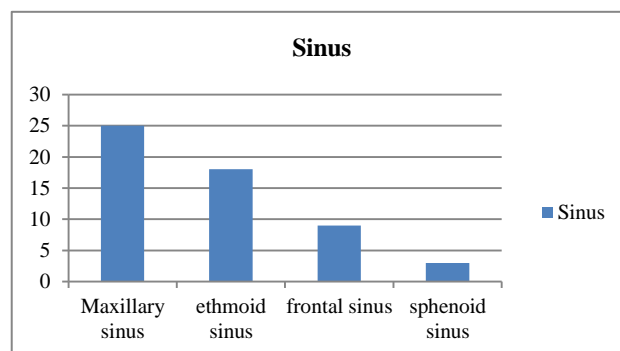
**Table 3: Variations in middle turbinate.**

Variations	No. of cases	%
Concha bullosa	8	27
Paradoxically bent	1	3
Duplication	0	0

**Table 4: Variations in uncinate process.**

Variations	No. of cases	%
Medially bent	3	10
Laterally bent	2	7
Pneumatization	2	7
Free lying	0	0
Attached to cribriform	0	0

Sinus haziness could only be seen with CT scan thereby knowing the extent of the disease and plan for better management of the disease.



**Figure 4: Paranasal sinuses involvement.**

The most commonly involved was Maxillary sinus in 83%, followed by ethmoid (60%), frontal (30%) and sphenoid (10%).

## DISCUSSION

Sinonasal region have many different anatomical variations. Although their role in the development of sinusitis remains unclear, but complete knowledge of these variations is important before the surgical procedure to avoid dreadful complications. To know the extent and spread of the disease CT scan gives a better understanding than DNE by Van Alyea OE et al, Mafee MF et al.<sup>5,6</sup>

The reported prevalence of DNS varies widely. In the present study of 30 patients, 20 (66%) patients had septal deviation on nasal endoscopy and 28 (93%) patients on CT scan. It was the most common anatomical variant seen. In the study conducted by Shahizon et al, 25% of cases had septal deviation on nasal endoscopy and in 40% patients on CT scan. Kasapoglu et al reported DNS in 41.9% cases on CT scan and Jareoncharsri et al, detected it in 72.3% cases on DNE as a most common finding. Severe septal deviation has been noted as a contributing factor for sinusitis by Shahizon et al, Kasapoglu F et al and Jareoncharsri et al.<sup>2,7,8</sup>

Unilateral or bilateral concha bullosa was detected in 27% of patients in the present series. Scribano estimated that it is only 3.5%. Krzeski et al, Stallman et al, and Ozcan et al reported incidences of 37.5%, 44% and 48.1%, respectively. The uncinate process is another important structure in relation to paranasal sinus drainage, and the incidence of variations in this structure is 21% in our study. The rate of uncinate process variations in Krzeski et al, Stallman et al, and Ozcan et al studies has been reported to be from 1-9% by Krzeski et al and Stallman et al.<sup>9,10</sup>

The ostiomeatal complex (OMC) is a functional entity of the anterior ethmoid middle meatal complex that represents the final common pathway for drainage and ventilation of the frontal, maxillary and anterior ethmoid cells. Thus, anatomical variations that redirect nasal airflow or narrow the OMC have been implicated in the development of chronic rhinosinusitis. In this study, the patients with pathologies at OMC (07/30) had involvement of multiple sinuses and were found to have increased symptom severity by Krzeski et al and Stallman et al.<sup>9,10</sup>

## CONCLUSION

Understanding the advantages and disadvantages of each helps us realize that they are of synergistic in nature and not competitive. This study proved that there is a strong association between presences of these variants on development of chronic inflammation in the paranasal sinuses. Nasal septal deviation was the commonest variation report. Nasal obstruction was the most common symptom. Maxillary sinus was the most common sinus involved. In variations of middle turbinate- concha bullosa was the most common. In variations of uncinate process medially bent was the most common. Hence, endoscopy and CT have revolutionized the understanding and management of chronic sinusitis in recent times.

*Funding: No funding sources*

*Conflict of interest: None declared*

*Ethical approval: The study was approved by the Institutional Ethics Committee*

## REFERENCES

1. Lanza DC. Diagnosis of chronic rhinosinusitis. Ann OtolRhinol Laryngol. 2014;193:10-4.
2. Shahizon AM, Suraya A, Rozmnan Z, Aini AA, Gendeh BS. Correlation of computed tomography and nasal endoscopic findings in chronic rhinosinusitis. Med J Malaysia. 2008;63(3):211-5.
3. Bradoo R. Endoscopic anatomy. In: Anatomic principles of Endoscopic sinus surgery: A step by step approach. 1st ed. New Delhi: Jaypee Bros; 2005: 59-70.
4. Meltzer EO, Hamilos DL, Hadley JA, American Academy of Allergy, Asthma and Immunology, The American Academy of Otolaryngic Allergy, et al. Rhinosinusitis: establishing definitions for clinical research and patient care. J Allergy Clin Immunol. 2004;113(6S):S1-62.
5. Van Alyea OE. Sphenoid sinus: anatomic study, with consideration of the clinical significance of the structural characteristics of the sphenoid sinus. Arch Otolaryngol. 1941;34(2):225-53.
6. Mafee MF, Chow JM, Meyers R. Functional endoscopic sinus surgery: anatomy, CT screening, indications, and complications. Am J Roentgenol. 1993;160(4):735-44.
7. Kasapoglu F, Onart S, Basut O. Preoperative evaluation of Chronic rhinosinusitis in patients by conventional radiographies, computed tomography and nasal endoscopy. Kulak Burun Bogazlhtis Derg. 2009;19(4):184-1.
8. Jareoncharsri P, Thitadilok V, Bunnag C, Ungkanont K, Voraprayoon S, Tansuriyawong P. Nasal endoscopic findings in patients with perennial allergic rhinitis. Asian Pac J Allergy Immunol. 1999;17(4):261-7.
9. Stallman JS, Lobo JN, Som PM. The incidence of concha bullosa and its relationship to nasal septal deviations and paranasal sinus disease. Am J Neuroradiol. 2004;25:1613-8.
10. Krzeski A, Tomaszewska E, Jakubczyk I, Galewicz-Zielińska A. Anatomic variations of the lateral nasal wall in the computed tomography scans of patients with chronic rhinosinusitis. Am J Rhinol. 2001;15:371-5.

**Cite this article as:** Parmar FJ, Patel AD. Role of anatomical variations in chronic rhinosinusitis on diagnostic nasal endoscopy and computed tomography scan of paranasal sinuses. Int J Otorhinolaryngol Head Neck Surg 2020;6:101-5.