

Original Research Article

Composite chondro-perichondrial clip myringoplasty: our experience

Shrikrishna B. H.*, Jyothi A. C.

Department of Otolaryngology and Head & Neck Surgery, Navodaya Medical College, Raichur (Karnataka), India

Received: 13 August 2016

Accepted: 07 September 2016

***Correspondence:**

Dr. Shrikrishna B. H.,

E-mail: drshrikrishna@gmail.com

Copyright: © the author(s), publisher and licensee Medip Academy. This is an open-access article distributed under the terms of the Creative Commons Attribution Non-Commercial License, which permits unrestricted non-commercial use, distribution, and reproduction in any medium, provided the original work is properly cited.

ABSTRACT

Background: There are several studies on the efficacy of the commonly used temporalis fascia for myringoplasty where the temporalis fascia is placed by underlay method after incising external canal wall skin. This study was conducted to assess the success rate and efficacy of use of a composite chondro-perichondrial graft in a combined overlay-underlay fashion where the external canal wall is not incised.

Methods: A prospective study was conducted where 30 cases of non-marginal perforation of tympanic membrane were properly selected based on the inclusion criteria. All the 30 cases underwent myringoplasty using composite chondro-perichondrial graft harvested from tragal cartilage and placed in a combined overlay-underlay fashion.

Results: There was complete closure of the perforation in 27 of the total 30 cases. Also there was reduction in the air-bone gap post-operatively in all the 27 cases with complete closure of the tympanic membrane perforations.

Conclusions: Composite chondro-perichondrial clip myringoplasty is an effective method of closing non-marginal perforations of the tympanic membrane.

Keywords: Tympanic membrane, Myringoplasty, Grafts, Perichondrium, Cartilage, Otitis media

INTRODUCTION

The temporalis fascia is the most commonly used graft for myringoplasty all over the world. It is placed by the underlay technique. The use of the temporalis fascia for myringoplasty has got more than 90 percent of success rate.¹⁻⁵ Heerman was the first to consider temporalis fascia as a grafting material. Storrs successfully employed it thereafter.⁶ However while using temporalis fascia graft the external canal wall needs to be incised to elevate the tympano-meatal flap. This may sometimes lead to disturbing bleeding at the surgical field as well as may compromise the free area for manipulating the instruments in the surgical field. Sometimes flap tears while elevating the tympano-meatal flap will compromise the results of the surgery. The concept of grafting tragal cartilage and perichondrium was introduced by Goodhill.⁶ Tragal cartilage with perichondrium fulfills all the required qualities of an ideal graft material namely low

rejection rate, sufficient quantity, good tensile strength, conductive properties similar to that of tympanic membrane and easy availability.⁷ Fernandes has described in his study that the composite chondro-perichondrial clip prepared from the autologous tragal cartilage provides an excellent material for the myringoplasty to close non-marginal perforations of the tympanic membrane.⁸ Our study was done in the same fashion of using the tragal cartilage and perichondrium for non-marginal perforations of the tympanic membrane and analyzes the graft uptake rate and the reduction of air-bone gap after surgery.

METHODS

This prospective clinical study was done over 1 period of 2 years from 1st September 2013 to 31st August 2015 at the Department of ENT and Head Neck Surgery of Navodaya Medical College Hospital, Raichur, Karnataka.

The study was approved by the Institutional Ethical Committee before its commencement. Also, a written informed consent was taken from all the patients. The study included 30 cases of non-marginal perforation of tympanic membrane that were selected based upon the inclusion and exclusion criteria. The inclusion criteria were age more than 16 years, presence of a non-marginal perforation in the tympanic membrane with a clear view of all the margins, air-bone gap which is no more than 35 dB, presence of cochlear reserve, at least 1 year of otoscopic follow-up with no spontaneous healing of the perforation and a patent eustachian tube as tested by valsalva manoeuvre. Patients were excluded in case of age under 16 years, marginal perforation of the tympanic membrane, large sub-total or total perforations of the tympanic membrane as they have no residual margins, air-bone gap of more than 35 dB, only hearing ear, narrow or tortuous external auditory canals, myringitis or if there were extensive adhesions connecting the tympanic membrane and/or malleus with the promontory. Although type I tympanoplasty has a good success rate in children, they were generally excluded from this study because any transcanal technique is not feasible with a smaller ear canal.

All the cases underwent endoscopic myringoplasty under local anaesthesia. With the patient lying supine, parts were prepped, painted and draped. Local anaesthetic infiltration was given to all 4 quadrants of the external auditory canal and both sides of the tragal cartilage. Using the straight pick and the sickle knife, the margin of the perforation is freshened and the mucosa underneath was roughened to facilitate healing. The dimensions of the perforation are measured using the help of the 90 degree ball probe as shown in Figure 1. Tragal cartilage is harvested with perichondrium intact on both sides and the wound is sutured with chromic catgut. The cartilage is trimmed keeping 2 mm extra size all around compared to the size of the perforation. Perichondrium on one side of the harvested cartilage is removed off. On the other side, the perichondrium is elevated from the underlying cartilage only about a distance of 2 mm all around as given in Figure 2. The cartilage graft is then inserted through the perforation such that the cartilage part becomes underlay and the perichondrium becomes overlay on the tympanic membrane remnant as in Figure 3. The perichondrium is spread out over the margin of the perforation. Thus, the clip formed by the edges of the cartilage and the perichondrium hold the margin of the perforation in an underlay-overlay fashion. An antiseptic layered cotton ball is kept over the tragal incision site and plaster applied. The cotton ball is removed after 1 week. Patients are discharged the same day evening and called for follow-up at 1, 4, 8, 12 and 24 weeks interval. They were advised against forceful nose blowing and sniffing, lifting heavy weights, and air travel for three weeks. The post-operative results with respect to closure of the perforation and improvement in the air-bone gap in audiometry are recorded at 12 and 24 weeks follow-up

period as seen in Figure 4. The pre- and post-operative findings are compared and statistically analysed.

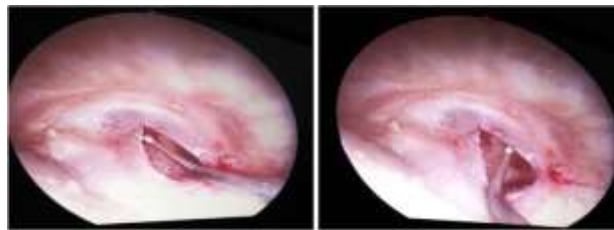


Figure 1: The dimensions of the perforation are measured using the help of the 90 degree ball-probe.

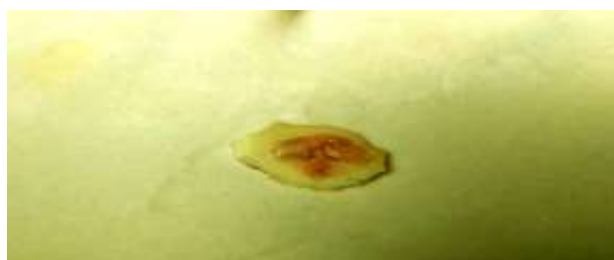

Figure 2: The perichondrium is elevated from the underlying cartilage all around at the edges about a distance of 2 mm from the edges.

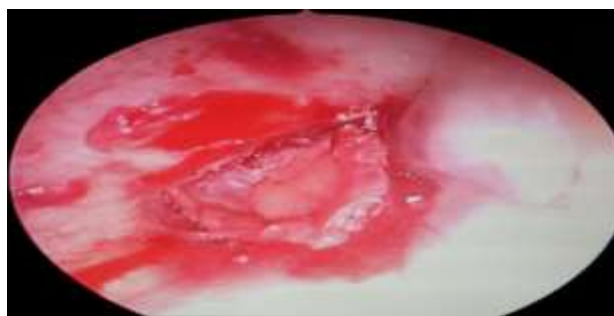

Figure 3: The cartilage graft is inserted through the perforation such that the cartilage part becomes underlay and the perichondrium becomes overlay on the tympanic membrane remnant.

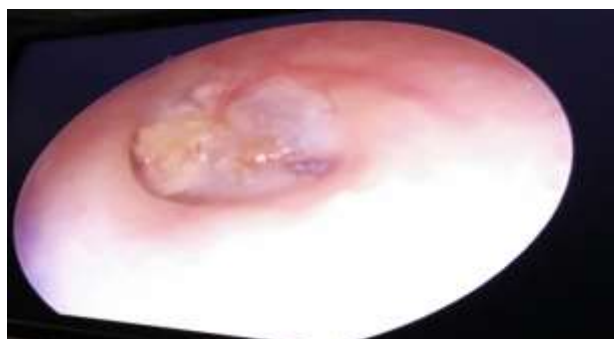

Figure 4: Oto-endoscopic finding at the end of 6 months follow-up showing complete closure of the tympanic membrane perforation.

RESULTS

In our study group of 30 patients, 18 (60%) were male and 12 (40%) were female. The age of the patients ranged from 17 years to 42 years (average 25.6 years). Among the 30 cases with non-marginal perforations, 17 cases (56.7%) were single quadrant perforations, 11 cases (36.7%) were two quadrant perforations and 2 cases (6.6%) were larger than two quadrant perforations. The time taken for the surgery was less than 30 minutes in 22 cases (73.3%), 30 to 40 minutes in 6 cases (20%), 40 to 50 minutes in 1 case (3.3%) and 50 to 60 minutes in 1 case (3.3%). The latter two cases which took long time were the initial two cases in the beginning of the study. With subsequent surgeries the surgery time reduced and towards the end of the study period, the surgery could be done in less than 30 minutes. At the end of the 24 weeks follow-up, complete closure of the perforation was observed in 27 (90%) cases and residual perforation was found in 3 (10%) cases. Among the 3 cases with residual perforation, 2 cases were having perforation of more than two quadrants and 1 case had developed post-operative infection and patient had delayed to come for follow-up to treat infection. Among the 30 cases, only 27 cases had complete closure of the perforation, hence we took the audiometric results of only those for statistical analysis. The mean air-bone gap during the pre-operative period of these 27 cases was 22 dB (maximum 30 dB, minimum 12 dB). In the same 27 cases, the mean air-bone gap observed at the end of 6 months in the post-operative period was 10 dB (maximum 20 dB, minimum 4 dB). Thus, there was a significant decrease in the air-bone gap after this surgery. Among the 17 cases with single quadrant perforation, the mean gain in the air bone gap was 10.53 dB (maximum 18 dB, minimum 4 dB). Among the 11 cases with two quadrant perforation, the mean gain in the air bone gap was 13.45 dB (maximum 18 dB, minimum 6 dB). Both the cases with more than 2 quadrant perforations had residual perforation at the end of 6 months follow-up and accordingly both had an enhanced air-bone gap post-operatively. One case which developed post-operative infection and had residual perforation had also developed increase in air-bone gap post-operatively.

DISCUSSION

Central perforations of the tympanic membrane are a common middle-ear condition. The commonly used techniques to deal with the central perforation are the overlay technique, the underlay technique and interlay technique.⁹ These surgeries can be done via via transcanal, endaural and postaural approaches. Each approach has its own advantages and disadvantages.¹⁰ Temporalis fascia is the most commonly used graft material for myringoplasty. The use of cartilage and fat is limited to specific situations only.^{11,12}

In our study, we have used the tragal cartilage and perichondrium for myringoplasty. Cartilage, perichondrium, and fascia are derived from mesenchymal tissue.

Histologically, on healing, they are incorporated in the middle layer of the tympanic membrane providing the lamina propria.¹³⁻¹⁶ The use of cartilage in type I tympanoplasty (myringoplasty) to fill a membranous void appears inherently unphysiologic and innately unrelated to the principles of physics. Cartilage may be seen as a mass impeding vibration of the tympanic membrane. Palisade splitting of the cartilaginous segment may aid in reducing this mass effect. The mass effect of the cartilage must necessarily favour the lower frequencies.¹⁶ The stiffening of the perichondrium in the postoperative period will favour the higher frequencies. Fernandes, in his study, states that this stiffening factor contributes significantly to the results, with the greatest improvement occurring in the higher frequencies.⁸ Cartilage is the well-established graft material of choice in revision cases because of its resilience and reduced nutritional requirements which are met by diffusion alone.¹¹

The main advantage of the cartilage graft has been thought to be its very low metabolic rate. It receives its nutrients by diffusion, is easy to work with because it is pliable, and it can resist deformation from pressure variations.¹⁷ Cartilage is easier to tailor, manipulate, and position than fascia and supplies both the scaffolding necessary during healing (epithelialisation) and subsequent support from recurrence of perforations.^{15,18} During healing, the cartilage scaffolding stabilizes and fixes the perichondrium, thus preventing it from herniating into the middle ear cavity and contributing to a failure. Shrinking of the perichondrium is also minimized by its attachment to the cartilage. Temporalis fascia grafts rely on fixation by adhesion and can easily be displaced during healing.¹⁹ The cartilage does not appear to interfere significantly with tympanic membrane vibration.^{15,20,21} The perceived disadvantage of the cartilage graft is that it creates an opaque tympanic membrane, which could potentially hide a residual cholesteatoma.²²

Tos described 23 known cartilage tympanoplasty methods to reconstruct the eardrum and proposed a classification into six main groups. The Composite chondro-perichondrial clip myringoplasty technique belongs to group-F as per this classification.²³ Eavey was the first to describe the butterfly cartilage inlay grafting technique. The edges of the cartilage perichondrial composite graft curve out like butterfly wings when the edge is split.¹³ This technique may sometimes cause epithelialisation of the graft and accumulation of keratin under the wing of the cartilage causing displacement of the graft similar to a grommet. In our technique we did not face such issues.

When partial thickness cartilage with perichondrium on the lateral aspect alone is fashioned, there is curling of the cartilage possibly due to the pull by the perichondrium, this can be addressed to a certain amount by the composite chondro-perichondrial graft technique as here the perichondrium is raised all along the margins of the cartilage. There is very limited data regarding

curling of the cartilage, four incisions of the perichondrium “the anti-curling incisions” have been described by Tos but a systematic study is still required to validate them.⁷

Recent studies show no difference in hearing results between the full thickness and partial thickness grafts⁷. Also histomorphological studies of cartilage grafts of Hitari have shown that there is wide replacement of the chondrocytes by fibrous tissue and loss of lipid vacuoles over time which makes the cartilage graft more homogenous in nature. This transfers the acoustic energy better than normal cartilage.⁷ Studies by Gierek et al and Couloinger et al have proven that there is no significant hearing difference between the use of temporalis fascia and cartilage for myringoplasty.^{25,26}

The composite chondro-perichondrial “clip” myringoplasty using the tragal cartilage and transcanal approach has a lot of advantages such as its a minimally invasive surgery done transcanally with an endoscope, it can be done in less than 30 minutes duration, it has good post-operative results in the form of perforation closure and improvement in hearing and it is cost-effective as it can be done under local anaesthesia and there is reduced hospital stay. We have taken cases with less than 35 dB hearing loss for our study, as middle ear ossicular pathology is rare in this class. However, the same can be confirmed during surgery by passing the endoscope through the perforation.⁸ There is no need to remove contiguous myringosclerosis plaques and there is not even a problem with exposed malleus. In fact, the stiffness of the myringosclerosis plaques and the malleus enhance the procedure by providing a rigid, interlocking surface for the graft. Patient comfort is improved as no external canal packing or middle ear support is necessary because the graft is instantly stable. Therefore, hearing is not compromised by packing materials and no office packing removal or canal suctioning has been necessary. Since the only incision is in the tragus, aural comfort and tidiness are enhanced.¹³

Careful removal of the circum-perforation squamous epithelium will reduce the risk of postoperative intratympanic cholesteatoma. However, the incidence of such should they occur should be no higher than with the use of the temporalis fascia technique. Also, it is imperative that the patient know about the use of cartilage to inform future health providers. This averts the future risk of inadvertently exploring the ear with the suspicion of an intratympanic cholesteatoma as a result of appearance of the cartilage.⁸

Graft failure in myringoplasty is due to post-operative infection.²⁶⁻²⁸ In our study, 1 of the 3 graft failures had developed post-operative infection. The other two cases had larger than 2 quadrant perforation. However, a 100% success rate has also been obtained in other studies using cartilage and perichondrium.^{13-16,20} Use of careful selection criteria for the surgery improves the success rate. Even though temporalis fascia is the widely

preferred graft for myringoplasty, cartilage grafts with minimally invasive techniques such as the composite chondro-perichondrial “clip” myringoplasty technique may replace fascia for small to moderate sized non-marginal perforations. With the use of endoscope coming in vogue for myringoplasty, the use of this technique may become popular because of its above mentioned advantages.⁷

CONCLUSION

Composite chondro-perichondrial clip myringoplasty is an effective method of closing non-marginal perforations of the tympanic membrane. It is simple, requires minimal training, and is particularly suited for noncompliant patients. It avoids a tympanotomy, with virtually no manipulation of middle-ear structures. It is a cost-effective technique for small to medium-sized perforations in cases with large ear canals and no ossicular pathology. Further studies involving a larger cohort of patients are needed to further clarify the efficacy of this technique.

Funding: No funding sources

Conflict of interest: None declared

Ethical approval: The study was approved by the Institutional Ethics Committee

REFERENCES

1. Prescott CAJ, Robartes WJ. Tympanoplasty surgery at the Red Cross War Memorial Children's Hospital: 1986-1988. *Int J Pediatr Otorhinolaryngol.* 1991;21:227-34.
2. Kessler A, Potsic WP, Marsh RR. Type I tympanoplasty in children. *Arch Otolaryngol Head Neck Surg.* 1994;120:487-90.
3. Francois M, Juvanon JM, Contencin P, et al. Myringoplastie chez l'enfant. *Ann Otolaryngol Chir Cervicofac.* 1985;102:321-7.
4. Lau T, Tos M. Tympanoplasty in children: an analysis of late results. *Am J Otol.* 1986;7:55-9.
5. Ophir D, Porat M, Marshak G. Myringoplasty in the paediatric population. *Arch Otolaryngol Head Neck Surg.* 1987;113:1288-90.
6. Glasscock, ME, Shambaugh GE. Surgery of the Ear. In: Pathology and Clinical Course of Inflammatory Disease of the Middle Ear. 5th Ed. 2006;21:428-9.
7. Parelkar K, Nagle S, Jagade M, Thorawade V, Khairnar P, Attakil A, et al. Triple-c Cartilage Tympanoplasty: Case Series. *International Journal of Otolaryngology and Head & Neck Surgery.* 2015;4:26-31.
8. Fernandes SV. Composite Chondro-perichondrial Clip Tympanoplasty: The Triple-C Technique. *Otolaryngology Head and Neck Surgery.* 2003;128:267-72.
9. Farrior JB. Risks and complications of tympanoplasty. In: Wiet RJ, eds. *Ear and Temporal Bone Surgery. Minimizing Risks and*

- Complications. New York, NY: Thieme; 2006: 58–70.
10. Wehrs RE. Grafting techniques. *Otolaryngol Clin North Am.* 1992;32:443–55.
 11. Merchant SN. Ossiculoplasty and tympanoplasty in chronic otitis media. In: Nadol JB, McKenna MJ, eds. *Surgery of the Middle Ear and Temporal Bone.* Philadelphia: Lippincott Williams and Wilkins; 2005: 305-324.
 12. Ozgursoy OB, Youralmaz I. Fat graft myringoplasty: a cost effective but underused procedure. *J Laryngol Otol.* 2005;119:277-9.
 13. Eavey RD. Inlay tympanoplasty: cartilage butterfly technique. *Laryngoscope.* 1998;108:657-61.
 14. Jansen C. Cartilage-tympanoplasty. *Laryngoscope.* 1963;73:1288-302.
 15. Levinson RM. Cartilage-perichondrial composite graft tympanoplasty in the treatment of posterior marginal and attic retraction pockets. *Laryngoscope.* 1987;97:1069-74.
 16. Dornhoffer JL. Hearing results with cartilage tympanoplasty. *Laryngoscope.* 1997;107:1094-9.
 17. Yung M. Cartilage Tympanoplasty: Literature Review. *The Journal of Laryngology & Otology.* 2008;122:663-72.
 18. Milewski C. Composite graft tympanoplasty in the treatment of ears with advanced middle ear pathology. *Laryngoscope.* 1993;103:1352-6.
 19. Borkowski G, Sudhoff H, Luckhaupt H. Autologous perichondrium-cartilage graft in the treatment of total and subtotal perforations of the tympanic membrane. *Laryngorhinootologie.* 1999;78:68-72.
 20. Amedee RG, Mann WJ, Reichelmann H. Cartilage palisade tympanoplasty. *Am J Otol.* 1989;10:447-50.
 21. Adkins WY. Composite autograft for tympanoplasty and tympanomastoid surgery. *Laryngoscope.* 1990;100:244-7.
 22. Ghanem MA, Monroy A, Alizadeh FS, Nicolau Y, Eavey RD. Butterfly Cartilage Graft Inlay Tympanoplasty for Large Perforations. *Laryngoscope.* 2006;116:1813-6.
 23. Tos M. *Cartilage Tympanoplasty: Classifications of Methods—Techniques—Results.* 1st Edition. Thieme; 2009.
 24. Gierek T, Slaska-Kaspera A, Majzel K, Klimczak-Gotqb L. Results of Myringoplasty and Type I Tympanoplasty with the Use of Fascia, Cartilage and Perichondrium Grafts. *Otolaryngologia Polska.* 2004;3:529-33.
 25. Couloigner V, Baculard F, El Bakkouri W, Viala P, Francois M, Narcy P, et al. Inlay Butterfly Cartilage Tympanoplasty in Children. *Ontology Neurotology.* 2005;26:247-51.
 26. Goodhill V. Tragal perichondrium and cartilage in tympanoplasty. *Arch Otolaryngol.* 1967;85:480-91.
 27. Glascock ME, Jackson CG, Nissen AJ, Schwaber MK. Postauricular undersurface tympanic membrane grafting: a follow-up report. *Laryngoscope.* 1982;92:718-27.
 28. Milewski CH. Fascia or perichondrium/cartilage in tympanoplasties. A comparative study regarding hearing results and recurrence of perforations in 1529 cases. In: Tos M, Thomsen J, Peitersen E, editors. *Cholesteatoma and mastoid surgery.* Amsterdam: Kugler & Ghedini Publications; 1989: 1113-1114.

Cite this article as: Shrikrishna BH, Jyothi AC. Composite chondro-perichondrial clip myringoplasty: our experience. *Int J Otorhinolaryngol Head Neck Surg* 2016;2:249-53.