

Original Research Article

Comparative study of endoscopic tympanoplasty and conventional tympanoplasty

Priyanka Aggarwal^{1*}, Barjinder Singh Sohal², J. P. Goyal²

¹Department of Ear, Nose, Throat and Head and Neck Surgery, Government Medical College, Bharatpur, Rajasthan, India

²Department of Ear, Nose, Throat and Head and Neck Surgery, Government Medical College, Patiala, Punjab, India

Received: 19 June 2019

Revised: 05 January 2020

Accepted: 07 January 2020

*Correspondence:

Dr. Priyanka Aggarwal,

E-mail: dr_piya34@yahoo.co.in

Copyright: © the author(s), publisher and licensee Medip Academy. This is an open-access article distributed under the terms of the Creative Commons Attribution Non-Commercial License, which permits unrestricted non-commercial use, distribution, and reproduction in any medium, provided the original work is properly cited.

ABSTRACT

Background: To compare the results of endoscopic tympanoplasty with that of conventional tympanoplasty and to evaluate and compare the graft uptake in both of these methods. The study was done to evaluate the improvement in hearing after tympanoplasty and the problems faced while doing the endoscope assisted tympanoplasty.

Methods: Between July 2010 to June 2013, 50 patients underwent tympanoplasty, 25 were endoscope assisted (group A) and 25 were microscope assisted (group B). Results of surgery were compared at the end of three and six months post operation.

Results: The success rate in terms of graft uptake rate was 88% with endoscope assisted tympanoplasty and 84% with other microscope assisted tympanoplasty. Overall success rate was 86.0%. Mean hearing improvement was (16.24±10.21 dB) and (14.28±7.10 dB) in group A and group B respectively.

Conclusions: Tympanoplasty with its visualization of hidden corners, justifies tympanoplasty by using endoscope in selected cases with comparable improved results in the literature. Furthermore, the cost of the endoscope is much less (about 10%) in comparison to operating microscope, making it more cost effective in developing countries. However, the endoscope cannot be employed in every case as one hand is blocked. In terms of Patient comfort, the endoscope assisted outnumbers the benefits of other conventional methods.

Keywords: Tympanoplasty, Endoscopy, Microscope, Hearing loss, Graft uptake

INTRODUCTION

Chronic suppurative otitis media is an important middle ear disease since prehistoric times. CSOM is the commonest cause of persistent mild to moderate hearing impairment in children and young adults in developing countries. The presence of a tympanic membrane perforation that does not heal spontaneously as in chronic otitis media represents an anatomical and functional defect that needs surgical correction in the majority of cases. Myringoplasty is indicated in cases with and without otorrhea, with a small or a large air-bone gap, and with no age limit.

The aim of reconstructing a tympanic membrane perforation is twofold; first, to allow the patient to have a normal social life with no restrictions, even regarding water entry into the ear, and second, to correct the hearing loss resulting from the perforation.

Tympanoplasty is the surgical operation performed for the reconstruction of the eardrum (tympanic membrane) and/or the small bones of the middle ear (ossicles). The term myringoplasty is reserved for the simple repair of a tympanic membrane perforation in which no ossicular reconstruction is involved. It is also called tympanoplasty-I.

The concept of surgical repair of tympanic membrane is attributed to Berthold who performed myringoplasty operation with thick skin graft and introduced the term.¹ Later Wullstein and Zollner published a method for closing TM with split thickness skin graft.^{2,3} They introduced the use of operating microscope, significantly enhancing surgical results by improving the accuracy of the technique. Mer first described the use of endoscopes for the middle ear and fibreoptic system delivered through the existing tympanic membrane perforations in two patients.⁴

Anterior, marginal tympanic membrane perforations can be operated using a postauricular approach to maximize exposure. The visualization of far anterior perforations may be especially difficult, and the anterior margin may be completely hidden from direct view behind a prominent anterior canal bony overhang. Anterior perforations may be managed through a transcanal approach, using the endoscope to visualize the anterior margin.^{5,6}

Keeping all this in view this study was undertaken with an aim to compare the methods of tympanoplasty i.e., using fiberoptic rigid endoscope or other conventional methods. The study aimed to evaluate the graft uptake and postoperative hearing as well. The study also helped to evaluate the problems faced while doing the endoscope assisted tympanoplasty.

METHODS

A cohort study was carried out on 50 patients admitted for tympanoplasty as per selection criteria in the department of ear, nose and throat, Government medical college and Rajindra Hospital, Patiala from August 2010 to January 2013.

Inclusion criteria were; CSOM with central perforation, the ear being dry for at least 3 weeks, mild to moderate conductive hearing loss and age >12 years and <50 years. Exclusion criteria were, age <12 and >50 years, patients with unsafe ear pathology, any other concomitant disease condition i.e. in nose or throat which could affect the result of study except the ear disease and patients with any eustachian tube dysfunction.

Procedure

A written consent was taken from selected patients. A detailed clinical history of each patient was taken and recorded. Tuning fork tests, PTA (Pure Tone Audiometry) to assess hearing loss and X-ray both mastoids lateral oblique view to assess the condition of mastoids was done in all the patients. Complete haemogram i.e. hemoglobin, bleeding time, clotting time, TLC, DLC and urine complete examination was carried out in all patients. Eustachian tube function tests e.g. Valsalva Maneuver and Miller Botnique test were done to rule out any eustachian tube dysfunction. The surgery

was performed under general or local anesthesia. For local infiltration 2% xylocaine with 1:100000 adrenaline was used. The 50 selected patients were divided into two groups, group A comprised of 25 patients who underwent endoscope assisted tympanoplasty and group B comprised of 25 patients who underwent conventional tympanoplasty. The patients were randomly selected.

The tympanoplasty was performed through postaural or permeatal approach; inlay or outlay technique was used. Graft used was temporalis fascia or tragal perichondrium. Rigid otoendoscope (0 degree/30 degree) was used to do tympanoplasty in patients forming group A. Preferably a transcanal approach was used in group A patients. The EAC was cleaned of any debris. The tympanic membrane perforation was visualized using the endoscope. The portion of the middle ear cavity visible through the perforation was examined. Margins of perforation are made raw. Semicircular incision from 2 o'clock to 8 o'clock positioned 3-4 mm lateral to the annulus was made. Tympanomeatal flap was elevated and retracted anteriorly. The middle ear cavity was examined endoscopically and reconstruction was done accordingly. Graft was placed by underlay technique. Tympanomeatal flap was reposed back. Gelfoam placed over the graft. Ear pack was put in EAC.

In group B where the patients were operated using microscope, the shaving of hair in the surgical field was got done 24 hours before surgery and betadine solution was applied. Sterile drapes are placed and 2% xylocaine with adrenaline was injected into the postauricular area at a dose of 4 mg/kg. A postauricular incision was made on the skin, along the natural fold of the ear. Then a bone deep incision was given through the soft tissue upto the mastoid part of temporal bone. The periosteum was cut and elevated anteriorly towards the posterior rim of the external auditory canal. The spine of Henle was identified and the osteomeatal flap was raised anteriorly. A horizontal oblique cut was given in this flap at the junction of the bone and cartilage. The self retaining Morrison's mastoid retractor was applied and the external auditory canal and tympanic membrane exposed and visualized. The tympanomeatal flap was elevated further and the cartilaginous ring was removed from the bony annulus. The middle ear cavity was inspecting after incising the mucosa along the medial wall of the middle ear cavity. Finally, tympanoplasty was done depending upon the middle ear status. Graft was placed by underlay technique and the tympanomeatal flap was reposed back. Gelfoam was placed over the graft. Closure was by planes and mersilk 3-0 was used for the skin using separate stitches. The surgical procedure was performed with surgical microscope with 10X magnifications.

Post operatively, the patients were prescribed broad spectrum antibiotics, analgesics and antihistaminics. Any postoperative complication was noted. Stitches were removed after 7 days and EAC pack was removed after 10-14 days. Patients were observed for graft uptake and

any complications after 4 weeks and 12 weeks of operation. PTA was repeated 3 months after surgery to assess the hearing and was compared with that of preoperative audiogram. Data collected was analyzed using SPSS Version 21 for windows (IBM Corp. Chicago, IL, USA).

RESULTS

Age incidence of patients in series ranged from 12 to 50 years. The minimum age was 15 years and maximum age was 50 years. The mean age in years was (31.65±10.94). So maximum number of patients 2 (42%) were in the age group of 21-30 years (Table 1).

Table 1: Age incidence.

Age in years	Group A N (%)	Group B N (%)	Total N (%)
12-20	2 (8)	3 (12)	5 (10)
21-30	10 (40)	11 (44)	21(42)
31-40	2 (8)	7 (28)	9 (18)
>40	11 (44)	4 (16)	15 (30)
Total	25 (100)	25 (100)	50 (100)

Sex distribution in the two groups shows that in group A 17 (68%) and in group B 16 (64%) patients were females which suggest that female patients outnumber the male patients. The male female ratio was 1:2 (Figure 1).

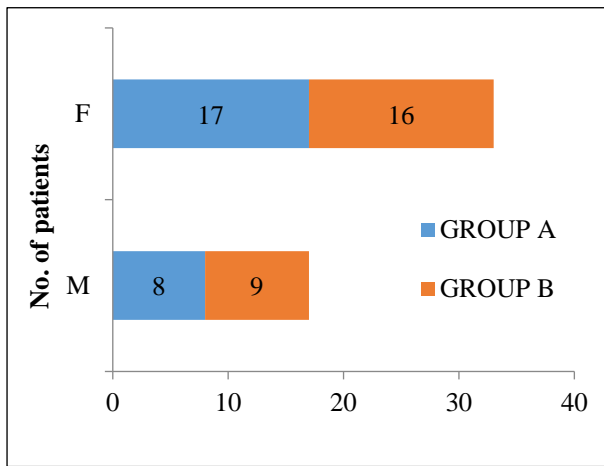


Figure 1: Sex incidence.

It was observed that in group A 17 (68%) and in group B 13 (52%) belonged to rural background. This shows more of rural population as compared to urban in our study groups. Left ear was more involved in both the groups with 13 patients in group A and 15 (60%) in group B.

In maximum number of patients, 13 (52%) in group A and 16 (64%) in group B, the duration of ear discharge was 1-5 years. In group A 14 (56%) and in group B 15 (60%) of patients had dry ear of <3 months of duration (Table 2).

Table 2: Duration of dry year.

Duration of dry year	Group A N (%)	Group B N (%)	Total N (%)
<3 months	14 (56)	15 (60)	29 (58)
3-6 months	9 (36)	8 (32)	17 (34)
6-12 months	2 (8)	2 (8)	4 (16)

AB gap of >30 dB in 40% patients of group A and 15% of group B patients (Figure 2). 20-30 dB, AB gap was recorded in 24% of group A and 44% of group B. Less than 20 dB AB gap was seen in 36% of group A and 28% of group B patients.

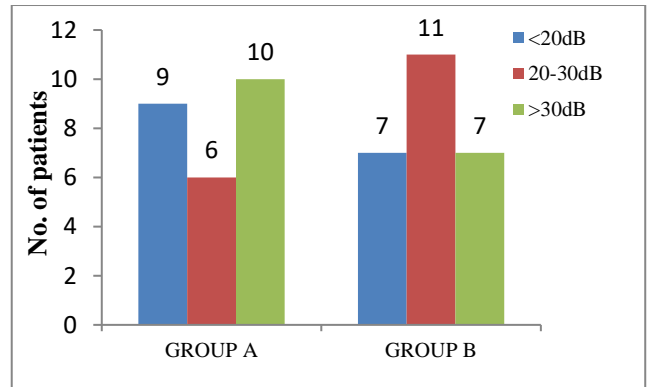


Figure 2: Preoperative AB gap.

Patients were taken under local and general anesthesia. (Table 4) shows that all patients of group A were taken under local anesthesia. In group B only 2 patients (8%) were taken under general anesthesia in the study.

Table 3: Site of perforation.

Site of perforation	Group A N (%)	Group B N (%)	Total N (%)
AIQ	3 (12)	5 (20)	8 (16)
ASQ	2 (8)	1 (4)	3 (6)
BAQ	2 (8)	4 (16)	6 (12)
BIQ	4 (16)	7 (28)	11 (22)
BPQ	2 (8)	1 (4)	3 (6)
PIQ	12 (48)	7 (28)	19 (38)
PSQ	0 (0)	0 (00)	0 (0)

Patients were divided into two subgroups where permeatal and postaural approach was used. Majority of the patients of group A 21 (84%) were operated by permeatal route and 4 (16%) by postaural route. 9 (36%) cases of group B were operated by permeatal route and 16 (64%) by post aural route. So permeatal route was used in 60% of the cases.

Results were taken as positive if graft was taken up and negative if it was not taken up. Figure 3 shows graft uptake at 3 months postoperatively. It shows that in group

A graft take up rate was 88% and in group B it was 84% (Figure 3). PIQ was involved in 19 (38%), AIQ in 8 (16%), ASQ in 3 (6.0%) and PSQ in 0 (0%) of patients (Table 3). BIQ were involved in 11 (22%), BAQ in 6 (12%) and BPQ in 3 (6.0%) of patients. Thus PIQ (38%) was most commonly involved. Radio-logical condition of the mastoid was noted in every patient. Pneumatic mastoid was observed in 34 (68%) patients and sclerotic mastoid in 16 (32%) patients. In 22 (88%) patients of Group A and 19 (76%) patients of Group B, type I tympanoplasty was done. Type II tympanoplasty was done in 2 (8%) patients of Group A and 3 (12%) patients of Group B. 3 (12%) patients in Group B and single patient in Group A underwent type III tympanoplasty (Figure 4).

Table 4: Type of anesthesia.

Type of anesthesia	Group	
	A (%)	B (%)
G/A	0.0	8.0
L/A	100	92.0

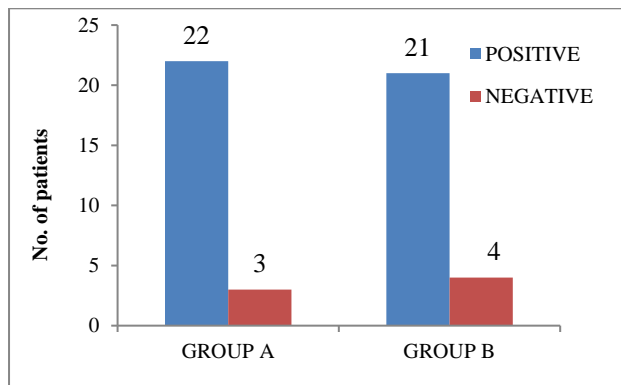


Figure 3: Graft uptake at 3 months.

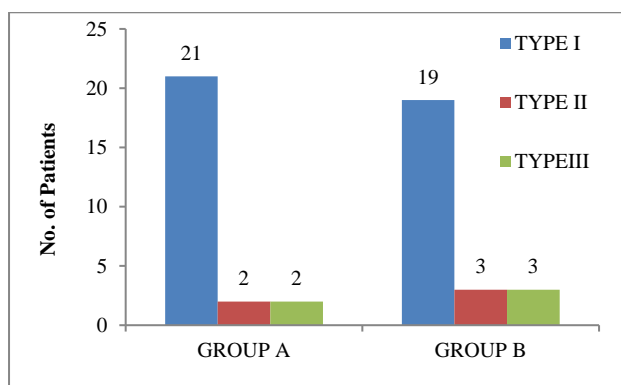


Figure 4: Type of tympanoplasty.

Improvement in hearing at 3 months postoperatively (Figure 5). One patient in group A showed no hearing improvement. 30% of total patients had <10dB, 34% had 11-20 dB and 34% of patients had >20 dB of hearing improvement.

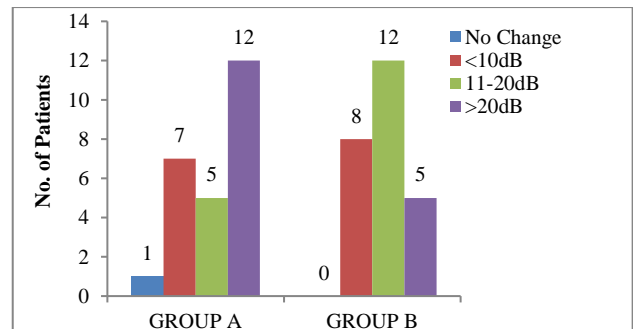


Figure 5: Improvement in hearing.

DISCUSSION

Chronic suppurative otitis media is a persistent disease capable of causing destruction of middle ear structure with irreversible sequelae which manifests as deafness and discharge.⁷

Tympanoplasty is one of the most frequently performed procedure in otorhinolaryngology. Great variability exists not only in surgical technique but also in its outcome throughout the world. It is an effective procedure for the repair of conductive mechanism. In patients timely tympanoplasty has good chances of restoring function with the potential for reducing further complications and deterioration. It yields very satisfying results for both to the patient and the surgeon.

Endoscopic guided technique of myringoplasty is a rapid, safe, reliable and efficient procedure and recommended as procedure of first intention for selected indications.⁸

In the present study, 50 patients in the age group of 12-50 years of either sex with dry and safe perforation and mild to moderate conductive hearing loss and good eustachian tube function were selected. Detailed history, clinical examination and investigations were done. Pure tone audiometry was done to assess the hearing loss.

The tympanoplasty was performed using endoscope or microscope through postaural or permeal approach; inlay or outlay technique was used. Graft used was temporalis fascia or tragal perichondrium under general or local anesthesia.

In our study, the age group ranged from 12 to 50 years. The patient’s mean age in group A was 34.84±11.65 and in Group B was 30.16±10.75 with the range, 12-50 years. All the patients were above 12 years of age with maximum number of patients above 40 years in groups A (44%) and in the age group of 21-30 years in group B. Patients below 12 years were excluded from this study because of generally high incidence of upper respiratory tract infections. Glasscock gave young age as relative contraindication to tympanoplasty because younger children under the age of 3 to 4 years are prone to

respiratory tract infections and recurrent attacks of otitis media.⁹

In our series there was female preponderance as compared to male patients. In group A 17 (68%) and in group B 16 (64%) patients were females. Overall 66.0% were females while rest of patients were males. In the study carried by Awan et al 53.3% subjects were females while 46.7 were males.¹⁰ In study by Kontantinidis et al male preponderance in the subjects was seen. There were 66.7% males and 33.3% females.¹¹ Graft uptake was seen in 22 cases (88%) of group A and in 21 cases (84%) of group B. No relation was seen between the age of the patient and graft uptake.

In our study most of the patients were from rural background. Overall 30 (60.0%) were from rural background and 20 (40.0%) were from urban background. In the study by Singh et al 60% subjects were from rural background.¹² The rural urban proportion seen in our study may be just reflection of rural-urban distribution of patients attending the outpatient department of our hospital. Also, lack of awareness about the disease and its sequelae and lack of proper referral to specialized centers from the rural areas may be responsible for the higher proportion of patients from the rural areas in our study.

In our study majority of the patients presented with history of discharge for 1-5 years i.e. 29 (58.0%), 14 (28.0%) had discharge for more than five years and only 7 (14.0%) had history of discharge less than one year. Longer duration of ear discharge shows lack of awareness about the disease and its complications. There is also lack of proper and adequate referral services especially in those with rural background and misunderstanding about the results of ear surgery may have contributed to the delayed seeking of specialized care. This factor had not been discussed much in the previous studies. All the patients were adequately treated with conservative treatment and had a dry ear for at least four weeks prior to surgery. Majority of cases were done under local anaesthesia. For local anaesthesia, 2% xylocaine with 1:100,000 adrenaline was used. No significant problem was encountered with local anaesthesia. Only 2 cases were operated under general anaesthesia in Group B as both of them were children. Some extra bleeding was seen in these cases as compared to local anaesthesia.

In our study, permeal and postaural approaches were employed. Post-aural approach was used in 20 cases (40.0%) and permeal approach was used in 30 cases (60.0%). Permeal approach was used in most of the cases (84%) under group A where the endoscope was also used. Only 4 patients in Group A were operated by postaural approach to overcome the problem of narrow EAC or anterior prominent bulge. In our study, these approaches had almost equal success in terms of graft uptake. Usami et al carried out 22 endoscope assisted myringoplasty in patients in whom the margin of the

perforation of TM was not visible due to curved EAC and stated that endoscopic assisted myringoplasty allows exquisite views and avoids blind surgical procedures.¹³

The type of tympanoplasty procedure done was depending upon the degree of hearing loss and intraoperative status of middle ear ossicles. In group A, 22 patients underwent tympanoplasty type I and 2 patients underwent tympanoplasty type II and 1 patient underwent tympanoplasty type III. In group B, 19 patients underwent tympanoplasty type I, 3 patients underwent tympanoplasty type II and type III each. Tympanoplasty was done by underlay technique in all patients. In tympanoplasty II PORP was used in 2 patients, incus interposition in 1 patient and TORP in 2 patients. Ossicular prosthesis extrusion rate at 3 months in our study was 0%. Olusesi et al operated 45 patients (51 years) between 8-52 years. Type 1 tympanoplasty was done in 41 patients and type 3 in 4 patients. Objective hearing improvement was observed in all. The study recommends that subjective hearing assessment should form part of indicators for success following tympanoplasty.¹⁴ Demir et al compared the functional results of incus interposition and the use of bone cement in patients who underwent type 2 tympanoplasty due to isolated incus defects in 47 patients including 12 patients with incus interposition and 35 patients with bone cement. They observed that in all patients, there was a statistical significant improvement in terms of the mean air conductance threshold and decrease in the mean air-bone gap ($p < 0.001$, $p = 0.001$). The comparison of percentage changes of functional gain between incus interposition and bone cement groups showed no statistically significant difference ($p = 0.542$, $p = 0.534$).¹⁵

Healing of perforation was complete in most of the cases in 3 months except in 2 cases where tragal perichondrium was used and it took about 4 months for healing. Failure rate in our study was 14.0%. Among the 7 cases of failure 5 were of temporalis fascia and 2 of tragal perichondrium. Failure might be due to infection mainly and large perforation thereby getting poor blood supply and less attachment with the rim of perforation margins or may be due to poor hygiene and inattentive postoperative advice. Jyothi P et al conducted a prospective randomized control trial on 50 subjects to evaluate the comparative efficacy of temporalis fascia and tragal perichondrium as grafting material in underlay tympanoplasty. Surgical success was evaluated in terms of intact drum membrane during the follow up period and closure of A-B gap within 10dB. Temporalis fascia achieved a graft uptake of 84% and a satisfactory hearing improvement in 76% of the patients. Tragal perichondrium achieved a success rate of 80% graft uptake and 75% hearing gain. They concluded that the rates are comparable with no statistical significance of the difference between them.¹⁶

The most common post operative complication was the discharge from the ear which was seen in 3 cases of

group A and 1 case of group B. The discharging ears postoperatively responded to conservative management. Another complication was granuloma formation at the tympanomeatal flap incision site in 1 case of group A and 3 cases of group B who responded to curettage and TCA cautery and healing occurred. Stitch abscess was seen in 2 cases of group B which responded to conservative management but increased the number of visits to hospital. Patient satisfaction was seen more in cases under group A as no complication related to postaural stitches like wound infection, pain etc was concurred. Aural polyp was seen in a case of group B which was managed by curetting it. No vertigo was seen in any patient. Karhuketo et al have emphasized that endoscopic myringoplasty fulfills the criteria of minimally invasive surgery, with the least trauma to normal tissue and that almost excludes pre and postoperative complications.¹⁷

In our study, preoperative mean A-B gap in group A and B was (31.84±12.54 dB) and (25.91±10.23 dB) respectively. Overall total preoperative AB gap was (28.88±11.72 dB). Postoperatively mean AB gap was (13.9±13.16 dB) in group A and (10.96±5.63 dB) in group B. Overall total post operative AB gap was (12.43±10.12 dB). Mean improvement in hearing was (17.92±10.68 dB) and (14.66±7.35 dB) in group A and B respectively. Mohindra and Panda conducted myringoplasty in 49 patients and recorded a success rate of 91.5% with 22.24-12.28 db improvement in air bone gap.¹⁸

In the present study, the success was defined as intact graft at least 3 months postoperatively. The success rate was in terms of graft uptake rate is 87.5% with temporalis fascia, and 80% with tragal perichondrium. The overall success rate was 88% in group A and 84% in group B. In our study we achieved satisfactory anatomical and hearing gain results which are comparable to other reported studies in the literature.^{16,19,20}

Tympanoscope-assisted myringoplasty, which is a new tool in the otologist's basket, produced results that are comparable to others in the literature. We used the otoendoscope for the inspection of the remnants of the tympanic membrane, as well as for the status of the ossicular chain. With the aid of the endoscope and curved instruments, it was possible to remove the epithelial ingrowths from the medial surface of the remnants of the tympanic membrane. The importance of this inspection of the medial surface of the residual tympanic membrane was emphasized by Somers et al in their study. Thus, the endoscope was helpful in excluding and treating the possible unwanted presence of the epithelium in the middle ear, which is almost impossible to do in conventional microscopic myringoplasty.²¹ Thommasin et al reported that endoscopic guided technique is a rapid, safe, reliable and efficient procedure and recommended it as procedure of first intention for selected indications.²² Kakehata et al stated that as opposed to conventional methods, endoscopic procedure does not require much

surgical exposure and avoids the substantial risk of unnecessary injury to the chorda tympani.²³ Endoscopic transtympanic tympanoplasty is an adequate and minimally invasive procedure and should prove to be a useful surgical procedure in future endoscopic tympanoplasty. Karhuketo et al have emphasized that endoscopic myringoplasty fulfills the criteria of minimally invasive surgery, with the least trauma to normal tissue and that almost excludes pre- and postoperative complications.²⁴

Endoscopic technique has indisputable advantages over traditional surgical microscopy when applied to elucidate the character and extent of the pathological process in the middle ear. This method allows revealing granulation and cholesteatoma in difficult of access pockets and folds of the middle ear without enlargement of the extent of surgical intervention, to evaluate the "continuity" of the chain of auditory ossicles. At the same time the use of an endoscope during performance of the majority of tympanoplastic procedures creates some difficulties related to the necessity of regular cleaning of the instrument and the impossibility of application of the bimanual technique.²⁵

CONCLUSION

Tympanoscopy, with its visualization of hidden corners, justifies tympanoplasty by using endoscope in selected cases with comparable improved results in the literature. Furthermore, the cost of the endoscope is much less (about 10%) than the operating microscope, thus it is more cost-effective, especially in developing countries. However, the endoscope cannot be employed in every case as one hand is blocked while the surgeon holds the endoscope, and the meatal space becomes crowded because of the endoscope and the instrument being used. There may be fogging and soiling of the endoscope, which requires repeated withdrawal and cleaning, and the magnification is less than the microscope; however, this drawback can be overcome by using a monitor or taking the endoscope nearer to the structures being visualized. Difficulty in patients with narrow external auditory canal was overcome using a wide bore dull colored ear speculum and giving an endaural incision within the incisura terminalis. Furthermore, this technique requires a definite expertise. In terms of patient comfort, the endoscope assisted procedure outnumbers the benefits of other conventional methods.

Funding: No funding sources

Conflict of interest: None declared

Ethical approval: The study was approved by the Institutional Ethics Committee

REFERENCES

1. Berthold E. In: Closure of tympanic membrane perforations. Glasscock ME and Shambaugh GE

- (eds.). Volume 4. Surgery of the Ear, Hamilton, Elsevier India; 1990: 334.
2. Wullstein H. In: Tympanoplasty. Glasscock ME and Shambaugh GE (eds.). Volume 5. Surgery of the ear, Hamilton, Elsevier India; 2004: 400.
3. Zollner F. In: Tympanoplasty. Glasscock ME and Shambaugh GE (eds.). Volume 5. Surgery of the ear, Hamilton, Elsevier India; 2004: 400.
4. Glasscock ME, Shambaugh GE. Endoscope-Assisted Middle Ear Surgery. Volume 5. Surgery of the Ear. Hamilton, Elsevier India; 2003: 325.
5. Guindy A. Endoscopic transcanal myringoplasty. *J Laryngol Otol.* 1992;106:493-5.
6. Pyykkö I, Poe DS, Ishizaki H. Laser-assisted myringoplasty: technical aspects. *Acta Otolaryngol Suppl (Stockh).* 2000;543:1-4.
7. Shenoi PM. Management of chronic suppurative otitis media. Volume 5. Scott-Brown's Otolaryngology, London, Butter worth; 1987: 3215-31.
8. Thomassin JM, Facon F, Gabert K. The effectivity of otoendoscopy in myringoplasty using adipose graft. *Ann Otolaryngol Chir Cervicofac.* 2004;121(6):346-9.
9. Glasscock ME. Contraindications to tympanoplasty II: an exercise in clinical judgment. *Laryngoscope.* 1976;86:70-6.
10. Awan Z, Bashin H, Hussain A. Myringoplasty: A comparative study of different graft materials and various surgical procedures. *Ann Pak Inst Med.* 2008;4(4):209-11.
11. Kontantinidis I, Malliari H, Tsakiropoulou E. Fat myringoplasty as an office based procedure. *Otorhinolaryngol-Head and Neck Surgery.* 2010;42:25-8.
12. Klacansky J. How I do it cartilage myringoplasty. *Laryngoscope.* 2009;119:2175-77.
13. Usami S, Iijima N, Fujita S, Takumi Y. Endoscope assisted myringoplasty. *Journal for Oto-Rhino-Laryngology, Head and Neck Surgery.* 2001;63(5): 287-90.
14. Olusesi AD, Opaluwah E, Hassan SB. Subjective and objective outcomes of tympanoplasty surgery. *Eur Arch Otorhinolaryngol.* 2011;268(3):367-72.
15. Demir UL, Karaca S, Basut O. Bone cement or incus interposition in type 2 tympanoplasty: prognostic factors and functional outcomes. *Kulak Burun Bogaz Ihtis Derg.* 2012;22:299-304.
16. Dabholkar JP, Vora K, Sikdar A. Comparative study of underlay tympanoplasty with Temporalis fascia and Tragal perichondrium. *Indian J of Otolaryngol and head and neck sur.* 2007;59(2):116-9.
17. Karhuketo TS, Illomaki JH, Puhakka HJ. Tympanoscope assisted myringoplasty. *Journal for Oto-Rhino-Laryngology, Head and Neck Surgery.* 2001;63(6):352-8.
18. Mohindra S, Panda NK. Ear surgery without microscope; is it possible. *Indian J Otolaryngol Head Neck Surg.* 2010;62(2):138-41.
19. Slaska Kaspera, Geirek T, Maizel K, Klimczak Gołab L. The evaluation of cartilage and perichondrium graft for reconstruction of tympanic membrane. *Otolayngol Pol.* 2003;57(6):889-92.
20. Gierek T, Slaska-Kaspera A, Majzel K, Klimczak-Gołab L. Results of myringoplasty and type I tympanoplasty with the use of fascia, cartilage and perichondrium grafts. *Otolaryngol Pol.* 2004;58(3):529-33.
21. Somers TH, Houben V, Goovaerts G, Govaerts PJ, Offeciers FE. Histology of the perforated tympanic membrane and its mucoepithelial junction. *Clin Otolaryngol Allied Sci.* 1997;22:162-6.
22. Thomassin JM, Facon F, Gabert K. The Effectivity of otoendoscopy in myringoplasty using adipose graft. *Ann Otolaryngol Chir Cervicofac.* 2004;121(6):346-9.
23. Kakehata S, Futai K, Sasaki A, Shinkawa H. Endoscopic transtympanic tympanoplasty in the treatment of conductive hearing loss: early results. *Otol Neurotol.* 2006;27(1):14-9.
24. Karhuketo TS, Illomaki JH and Puhakka HJ. Tympanoscope-assisted myringoplasty. *Journal for oto-rhino-laryngology, head and neck surgery.* 2001;63(6):352-8.
25. Semenov FV, Misiurina IV. Advantages and disadvantages of the application of endoscopic techniques at different stages of tympanoplasty. *Vestn Otorinolarngol.* 2010;6:48-50.

Cite this article as: Aggarwal P, Sohal BS, Goyal JP. Comparative study of endoscopic tympanoplasty and conventional tympanoplasty. *Int J Otorhinolaryngol Head Neck Surg* 2020;6:1804-10.