

Original Research Article

DOI: <http://dx.doi.org/10.18203/issn.2454-5929.ijohns20193875>

Facial nerve paralysis: a clinical study

Shilpa K. Sudhakaran¹, Sagesh Madayambath^{2*}

Department of ENT, ¹Malabar Medical College Hospital, ²Government Medical College, Kozhikode, Calicut, Kerala, India

Received: 13 May 2019

Revised: 06 July 2019

Accepted: 19 July 2019

***Correspondence:**

Dr. Sagesh Madayambath,

E-mail: drsageshm@gmail.com

Copyright: © the author(s), publisher and licensee Medip Academy. This is an open-access article distributed under the terms of the Creative Commons Attribution Non-Commercial License, which permits unrestricted non-commercial use, distribution, and reproduction in any medium, provided the original work is properly cited.

ABSTRACT

Background: A facial paralysis is one of the most emotionally traumatic deficits a person can experience. It is essential to understand the cause and nature of nerve injury and undertake proper measures for restoration and rehabilitation of facial symmetry. The present study was conducted to evaluate the various aetiologies of lower motor neuron facial paralysis that presented to our department. The aim of the present study is to investigate into the demographic data and etiology associated with peripheral facial nerve paralysis and to assess the site of lesion, severity grade and treatment outcome of peripheral facial nerve paralysis.

Methods: A prospective longitudinal study conducted in a tertiary care hospital, over a time period of one and a half years from November 2014 to April 2016. All the patients were assessed regarding the time of onset of symptoms, rapidity of progression, duration and completeness of paralysis. Topo diagnostic tests were done to assess the site of lesion and response to treatment monitored.

Results: The most common cause for LMN facial nerve paralysis was external trauma and Bell's palsy. The mean age group was 37.5 years with a male preponderance. Majority of the lesions were suprageniculate and had a House Brackmann grade IV severity score.

Conclusions: Peripheral facial paralysis showed a good response to treatment and timely intervention would result in a full or partial recovery at the end of a follow up.

Keywords: Facial paralysis, Topo diagnostic tests, House Brackmann grading, Bell's palsy

INTRODUCTION

Face is often regarded as the mirror of the soul. The facial nerve is the seventh cranial nerve, serving the vital functions of lacrimation, salivation, taste, acoustic reflexes and the most important being facial expressions.¹ Its functional integrity protects the eye and cochlea, aids mastication, speech and communication. The patient who suffers with facial paralysis experiences not only its functional consequences but also psychological impact of a change in self-image and impaired communicative ability.² A facial paralysis is thus one of the most emotionally traumatic deficits a person can experience. Unquestionable therefore, is the need for urgent measures to understand the cause and nature of nerve injury and

undertake proper measures for restoration and rehabilitation of facial symmetry.

Most of the facial nerve disorders, whether inflammatory, traumatic or neoplastic occur along its complex intra temporal course.³ Over the past two decades, a lot more details have been learned, yet some controversies and concerns about the diagnosis and management of facial palsy, still persists. Newer technologic advancements in radiologic and electrical diagnosis and the emergence of intraoperative monitoring are helping to clear these grey areas.

A protracted course within a bony canal, congenital dehiscence, complex branching and interconnections,

segmental blood supply, all these factors contribute significantly to the causation and final outcome of insults to the nerve. In most cases of facial palsy, the inaccessibility of intratemporal facial nerve to direct testing hinders an accurate assessment of the exact location and extent of nerve damage.

The present study was conducted to evaluate the various aetiologies of lower motor neuron facial paralysis that presented to our department. The objective of the study was to investigate into the demographic data and etiology associated with peripheral facial nerve paralysis. Attempts were made at systematized topo diagnosis as an exercise to determine the anatomic level of injury, assessment of the severity of lesion as well as the eventual severity grade and treatment outcome of peripheral facial nerve paralysis.

METHODS

The study was conducted in the Department of ENT at Malabar Medical College Calicut, over a time period of one and a half years from November 2014 to April 2016. All patients presenting to the ENT department with a clinical diagnosis of peripheral facial nerve paralysis during the study period were included in the study.

Study design

The study was a prospective longitudinal study.

Selection criteria

Participants within the study group comprised of patients diagnosed to have peripheral facial nerve paralysis of all age groups and both sexes, who were treated in ENT department during the study period. Those patients having a facial nerve paralysis as a part of upper motor neuron lesions were excluded from the study. All those patients presenting with congenital facial nerve palsy were also exempted from the study group.

Study method

All the patients in the study group were assessed with a thorough history including the time of onset of symptoms, rapidity of progression, duration and completeness of paralysis. They were also questioned regarding any previous episodes, family history, associated symptoms (auditory, vestibular, neurological), medical illness (diabetes, tuberculosis, autoimmune disorders, malignancy), history of trauma and any previous surgeries.

Assessment of functions of facial nerve were done by evaluation of the degree of voluntary movements present in facial musculature including wrinkling of forehead, eyelid closure, response to corneal and conjunctival reflexes, Bell's phenomenon, whistling, blowing out of cheeks, presence of nasolabial folds, deviation of angle of

mouth and status of facial symmetry at rest and during motion.

Topo diagnostic evaluation of facial damage included the Schirmer's test, taste sensations on the anterior two-third of tongue and stapideal reflex tests, wherever feasible. Sialometry being an invasive test and least reliable, was not included in this study.

The degree of facial paralysis was assessed clinically based on the House-Brackmann classification.⁴ A complete head and neck and ENT examination was done in all cases. Clinical assessment also included routine laboratory studies, pure tone and impedance audiometry. Nerve conduction study, CT scan, HRCT scan of temporal bone and MRI scan was done only in selected cases with traumatic, neoplastic or inflammatory etiologies.

The various surgical procedures (facial nerve decompression, end to end anastomosis, nerve grafting) that the patient underwent was noted and the surgical outcomes were analysed. All patients were followed up at biweekly intervals for first two months and then at two months intervals for a period of one year.

The results were tabulated and analyzed using the statistical software SPSS 16.0 and were compared with other studies.

RESULTS

A total of 34 cases of lower motor neuron facial paralysis were included in our study. All these patients were subjected to clinical examination and appropriate investigations to reach a final diagnosis. An attempt was made to classify them based on the aetiology, to determine the site of lesion by topo diagnostic tests and to assess the severity of paralysis in each of these cases employing the House-Brackmann grading system.

Of the total 34 patients, 25 patients (73.5%) were males and the rest nine patients (26.5%) were females. Our study group included patients in the age range from three years to 75 years, the mean age being 37.5 years. Majority of patients belonged to age group of 20-39 years (38.2%) closely followed by the 40-59 year age group (32.4%). We had five patients each in the two extremes of age groups. In our study, right side was affected in 20 (58.8%) cases and left in 14 cases (41.2%), which do not show a significant difference.

External trauma and idiopathic (Bell's palsy) were found to be the most common cause of facial nerve paralysis in our study, each accounting for about 26.5% of the total cases (Table 1). Infections and tumour ranked the second and there were four cases of iatrogenic facial nerve palsy accounting to 11.8% of the study population. Out of the nine cases of external trauma, eight were due to fracture temporal bone following road traffic accidents and one

following blunt injury to temporal bone. Of the four cases of iatrogenic trauma, two were following mastoidectomy, one following a cochlear implantation surgery and the fourth following a total parotidectomy surgery. In the infective group, two cases (33.3%) were the result of otitis media (cholesteatomas), three cases (50%) due to malignant otitis externa and one case had Ramsay Hunt syndrome. Among the six cases with tumours, two cases (33.3%) each was diagnosed to have a malignant parotid tumour and a malignancy of temporal bone. The other two had an acoustic neuroma and glomus tumour.

Table 1: Etiology of facial paralysis.

S. no	Etiology	Frequency	%
1	External trauma	9	26.5
2	Idiopathic (Bell's palsy)	9	26.5
3	Infections	6	17.6
4	Tumour	6	17.6
5	Iatrogenic	4	11.8
Total		34	100

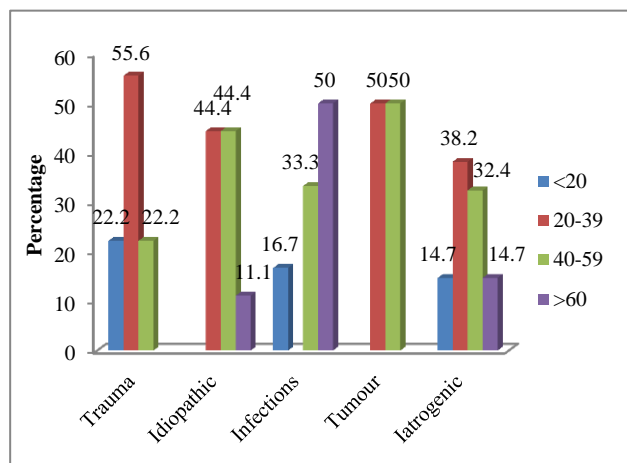


Figure 1: Age wise categorization of etiologies.

Most of the cases of traumatic facial palsy were found within the age group of 20-39 years (55.6%) (Table 2). The highest incidence of cases of Bell's palsy was distributed equally between the age groups of 20-39 and 40-59 years (44.4%). Figure 1 shows the age wise categorization of various etiologies of facial paralysis in our study.

The different sites of involvement in facial palsy were determined based on the topo diagnostic tests (Table 3). The level of lesion could not be determined in two cases. The lesion was found to be suprageniculate/ geniculate in majority of the cases (55.9%). In seven cases (20.6%) the lesion was found to be infrageniculate/suprastapedial in four cases (11.8%) infrastapedial/suprachordal and peripheral in two cases (5.8%). Most of the cases of Bell's palsy showed the level of lesion to be

suprageniculate whereas in iatrogenic trauma the site was trapped out to be infrastapedial.

Table 2: Age distribution.

Age group (in years)	Frequency	%
<20	5	14.7
20-39	13	38.2
40-59	11	32.4
>60	5	14.7
Total	34	100

Table 3: Level of lesion.

Level	No. of cases	%
Indeterminable	2	5.9
Suprageniculate/geniculate	19	55.9
Infrageniculate/suprastapedial	7	20.6
Infrastapedial/suprachordal	4	11.8
Peripheral	2	5.8

The severity of the paralysis at presentation was assessed based on the House Brackman grading for facial paralysis (Table 4).¹ Majority of our patients (16 cases/47.1%) had a grade IV severity at presentation. Four cases (11.8%) had a grade V paralysis and one case (2.9%) had a complete grade VI paralysis.

Table 4: Severity grade.

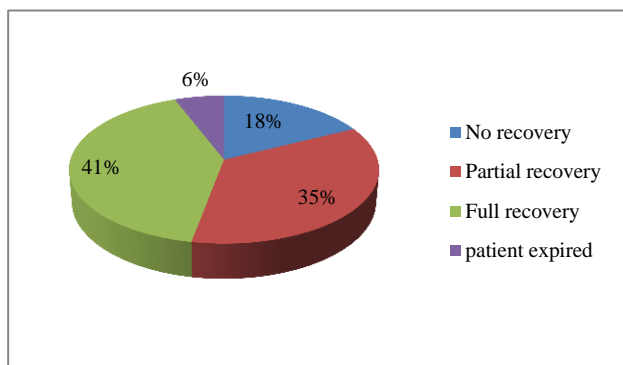
Grade	Frequency	%
I	-	-
II	2	5.9
III	11	32.4
IV	16	47.1
V	4	11.8
VI	1	2.9
Total	34	100

The treatment given to each patient was recorded and analysed (Table 5). No treatment intervention was done in two patients with advanced temporal bone malignancy. A conservative medical treatment and physiotherapy was offered to 19 patients (55.9%). A surgery on the facial nerve was done in 11 cases (32.4%), of which nine patients (26.5%) underwent facial nerve decompression and two cases (5.9%) had an end to end facial nerve anastomosis.

The cases were followed up at regular intervals for a period of one year and the recovery noted based on the severity grade (Figure 2). Of the total 34 cases, six patients (17.6%) showed no signs of any recovery at the end of one year. A total of 14 patients (41.2%) had a full recovery and 12 cases (35.3%) had a partial recovery at the end of follow-up. Two cases with advanced temporal bone malignancy expired during the period of follow-up.

Table 5: Treatment offered.

Treatment	Frequency	%
No intervention	2	5.9
Conservative management	19	55.9
Surgery for facial palsy	11	32.4
Surgical intervention for tumours	2	5.9

**Figure 2: Treatment outcome.**

DISCUSSION

We set out to study 34 patients with peripheral facial nerve paralysis to assess the demographic data, etiology and anatomical level of the lesion using topo diagnostic tests, severity of facial paralysis, surgical approaches and treatment response in peripheral facial nerve paralysis.

In our study, commonest causes for facial nerve paralysis were idiopathic (Bell's palsy) and trauma, each accounting for about 26.5%. Review of the literature of other studies highlight Bell's palsy as the commonest cause of facial paralysis. In a study by Schiatkin in 3454 patients, the incidence of Bell's palsy was 48.3%.⁵ Santos-Lasaso et al had a series with much larger group of idiopathic cases between 62% and 93%, probably due to the fact the study was carried out in patients attending basic health units.⁶ In a study by Peitersen 2570 cases of peripheral facial nerve palsy were studied during a period of 25 years and it included 1701 cases of Bell's palsy (66.2%).⁷ Hohman et al studied 1989 patients of facial paralysis which had 38% cases of Bell's palsy, 7% cases of iatrogenic injuries and varicella zoster each and 5% of congenital palsy.⁸

In their study Schiatkin had presented 23% of traumatic cases, whereas Rodrigues et al labeled 7.8% of their cases as traumatic facial palsy.^{5,9} In a study with 82 patients, Pinna et al described just 2 cases of iatrogenic facial paralysis.¹⁰ Asma et al describes that the incidence of iatrogenic facial palsy associated with otology surgery has been estimated to be 0.6%-3.7%, which increased to 4%-10% in revision mastoid surgeries.¹¹

In our study we had a single case of herpes zoster oticus (Ramsay Hunt syndrome) accounting to 2.9% of the study population. Peiterson showed that these patients present with a more severe facial paralysis and only 21% achieve a complete recovery.⁷ In their 31 year series, Schiatkin found 7% of Ramsay-Hunt syndrome cases, whereas Rodrigues et al found two cases of Ramsay-Hunt syndrome among 38 cases.^{5,9}

In this study, out the total 34 cases, 5.9% cases were due to chronic otitis media and 8.8% cases were due to malignant otitis externa. In their study Rodrigues et al had noted 13.1% of infectious causes, which included acute otitis media, chronic otitis media and Ramay-Hunt syndrome, while Shiatkin had only 4% cases with an infective etiology.^{5,9}

The mean age of our study group was 37.5 years which is similar to a study by Meja et al, who in a study of 63 cases, presented the mean age to be 41 years.¹² Rodrigues et al also showed an increased incidence of facial paralysis in the fourth decade of life.⁹ In a study by Hohman et al the mean age at presentation was 44.5 years whereas Asma et al found a mean age of 47.14 years.^{8,11} In our study, the mean age group of patients with Bell's palsy was found to be 45.88 years and that with external traumatic facial palsy to be 27.1 years.

In our study, out of the 34 cases, 25 cases (73.5%) were males and nine (26.5%) were females. In the study by Meja et al 60% of the total 63 cases was men.¹² They found the left side of the face to be involved in 60% of cases, whereas we found right side predominance in 58.8% of cases. The percentage of female patients was 61% in the study by Hohman et al and 47.1% in case of Asma et al.^{8,11}

The topo diagnostic tests showed that majority of the lesions, in our study were confined to the suprageniculate/geniculate region accounting to 55.9% (19 cases). In most cases of Bell's palsy the level of lesion was found to be suprageniculate. Yanagihara et al studied 53 Bell's palsy patients with denervation verified by electrodiagnostic examinations.¹³ In 60% of these cases, the suprastapedial lesion was responsible for degeneration of the nerve and in the other 40%, degeneration involved the infrastapedial segment. In our study, the major site of iatrogenic trauma was mapped out to be infrastapideal. Asma et al had ten patients with iatrogenic immediate facial palsy secondary to mastoidectomy and the second genu was the commonest site of injury (60%).¹¹

Regarding the severity grading, 47.1% of cases presented with a House Brackmann grade of IV, which meant an obvious disfiguring weakness. A House-Brackmann grade III presentation with an obvious non disfiguring weakness was seen in 32.4% of cases. In the study by Zohrevandi et al in 121 patients, the most common grades

of nerve damage were IV and V based on House-Brackmann grading scale (47.1%).¹⁴

Regarding the treatment offered, about 32.4% of cases (those with temporal bone fractures, iatrogenic trauma, cholesteatoma with facial palsy and a single case of Bell's palsy which did not recover with steroid) were managed surgically. A conservative medical treatment with steroids, antivirals and physiotherapy, were employed in 55.9% of cases. In a meta-analysis by Quant et al, six trials were included with a total of 1145 patients with Bell's palsy of which 574 patients received steroids alone and 571 patients received steroids and antivirals.¹⁵ The pooled odds ratio for facial muscle recovery showed no benefit of steroids plus antivirals when compared with steroids alone. But in the clinical practice guideline proposed by Baugh et al, the development group recommended that the clinicians may offer oral antiviral therapy in addition to oral steroids within 72 hours of symptom onset for patients with Bell's palsy.¹⁶

The Cochrane database review regarding the early surgical intervention in Bell's palsy by McAllister et al included 44 participants in the surgical trial, who were randomized into surgical and non-surgical groups.¹⁷ A second study randomly allocated 25 participants into surgical or control groups using statistical charts. Both studies showed that the operated group and the non-operated group (who received oral prednisolone) had comparable facial nerve recovery at nine months.

Out of the surgically managed cases, nine cases (26.5% of the total study population) were managed by facial nerve decompression and two cases (5.9%) underwent end to end anastomoses. Hato et al had studied 66 patients with facial nerve paralysis after temporal bone trauma according to the fracture location and the period of time between trauma and surgery.¹⁸ The number of patients who achieved complete recovery of House-Brackmann grade I was 31 of 66 cases (47.0%). They found no difference in therapeutic outcomes among the subgroups classified by fracture location. The rate of recovery in patients undergoing decompression surgery within two weeks after trauma reached 92.9%, resulting in a significantly better outcome than that of patients undergoing later decompression surgery. Gantz et al also found that surgical decompression medial to the geniculate ganglion significantly improves the chances of normal or near-normal return of facial function when performed within two weeks of onset of total paralysis.¹⁹

At the end of one year follow up 14 cases (41.2%) showed a full recovery, 35.3% (12 cases) showed a partial recovery, six cases (17.6%) showed no signs of recovery and two cases (5.9%) expired. In the study by Peitersen, out of the 2570 cases of peripheral facial nerve palsy, in 85% of patients facial nerve function returned within 3 weeks and in the remaining 15% after 3-5 months.⁷

The demerits of this study are that the number of patients is comparatively less than that required for an effective epidemiological study. More over the duration of follow up is short and no long term analysis could be made.

CONCLUSION

According to our study, the most common cause for LMN facial nerve paralysis was external trauma and Bell's palsy. The mean age group of the study population was 37.5 years with a male preponderance and the right side being more affected. Majority of the lesions were suprageniculate and had a House Brackmann grade IV severity score at presentation. Peripheral facial paralysis showed a good response to treatment and most of our cases had a full or partial recovery at the end of a follow up for one year.

ACKNOWLEDGEMENTS

We acknowledge the cooperation of our patients included in this study and the moral support of the staff members of our department.

Funding: No funding sources

Conflict of interest: None declared

Ethical approval: The study was approved by the Institutional Ethics Committee

REFERENCES

1. Parnes S, Batniji R. Facial reanimation. In: Bailey BJ, Johnson JT, eds. *Head and Neck Surgery-Otolaryngology*. 4th ed. Philadelphia: Lippincott Williams; 2006: 2467-2479.
2. Wackym PA, Rhee JS. Facial paralysis. In: Snow JB, Ballenger JJ, eds. *Ballenger's Otorhinolaryngology Head and Neck Surgery*. 17th ed. Connecticut, US: BC Decker Inc; 2003: 489-520.
3. Luxon LM. Retrocochlear and facial nerve disorders. In: Gleeson M, George GB, eds. *Scott-Brown's Otorhinolaryngology, Head and Neck Surgery*. 7th ed. Edward Arnold Ltd; 2008: 3837-3892.
4. House JW, Brackman DE. Facial nerve grading system. *Otolaryngol and Head Neck Surg.* 1985;93:146-7.
5. Schiattkin B, May M. Disorders of the facial nerve. In: Kerr AG, Booth JB, eds. *Scott-Brown's Otolaryngology*. Volume 3. 6th ed. Butterworth-Heinemann, Oxford; 1997: 1-38.
6. Santos-Lasaosa S, Pascual-Millán LF, Tejero-Juste C, Morales-Asín F. Peripheral facial paralysis: etiology, diagnosis and treatment. *Rev Neurol.* 2000;30(11):1048-53.
7. Peitersen E. Bell's palsy: the spontaneous course of 2,500 peripheral facial nerve palsies of different etiologies. *Acta Otolaryngol Suppl.* 2002;549:4-30.

8. Hohman MH, Hadlock TA. Etiology, diagnosis, and management of facial palsy: 2000 patients at a facial nerve centre. *Laryngoscope*. 2014;124(7):283-93.
9. Rodrigues REC, Ceccato SB, Rezende CEB, Garcia RID, Costa KS, Campilongo M, et al. Paralisia Facial Periférica: análise de 38 casos. *Arq Med ABC*. 2002;27:62-6.
10. Pinna BR, Testa RG, Fukuda Y. Traumatic facial paralysis's study: clinical and surgical review. *Rev Bras Otorrinolaringol*. 2004;70(4):479-482.
11. Asma A, Marina M B, Mazita A, Fadzilah I, Mazlina S, Siam L. Iatrogenic facial nerve palsy: lessons to Learn. *Singapore Med J*. 2009;50(12):1154-7.
12. Ayala MA, Casqueiro SJC, Durio CE, Sanz FR. Peripheral facial palsy. Descriptive study at the University hospital in Getafe. *Acta Otolaryngol Esp*. 2007;58:52-5.
13. Yanagihara N, Kitani S, Gyo K. Topodiagnosis of lesions in Bell's palsy. *Ann Otol Rhinol Laryngol Suppl*. 1988;137:14-7.
14. Zohrevandi B, Monsef Kasmaee V, Asadi P, Tajik H. Report of 121 cases of Bell's Palsy referred to the emergency department. *Emergency*. 2014;2(2):66-70.
15. Quant EC, Jeste SS, Muni RH, Cape AV, Bhussar MK, Peleg AY. The benefits of steroids versus steroids plus antivirals for treatment of Bell's palsy: a meta-analysis. *BMJ*. 2009;339:b3354.
16. Baugh RF, Basura GJ, Ishii LE, Schwartz SR, Drumheller CM, Burkholder R, et al. Clinical practice guideline: Bell's palsy. *Otolaryngol Head Neck Surg*. 2013 Nov;149(3):1-27.
17. McAllister K, Walker D, Donnan PT, Swan I. Surgical interventions for the early management of Bell's palsy. *Cochrane Database Syst Rev*. 2013;(2):CD007468.
18. Hato N, Nota J, Hakuba N, Gyo K, Yanagihara N. Facial nerve decompression surgery in patients with temporal bone trauma: analysis of 66 cases. *J Trauma*. 2011;71(6):1789-92.
19. Gantz BJ, Rubinstein JT, Gidley P, Woodworth GG. Surgical management of Bell's palsy. *Laryngoscope*. 1999;109(8):1177-88.

Cite this article as: Sudhakaran SK, Madayambath S. Facial nerve paralysis- a clinical study. *Int J Otorhinolaryngol Head Neck Surg* 2019;5:1309-14.