

Original Research Article

Endoscopic butterfly graft myringoplasty in small to medium perforation in adolescent chronic otitis media: our experience in 15 cases

Dilesh A. Mogre*, Fazal M. Ahmed, Parvathi T. Bano

Department of ENT and Head Neck Surgery, Centenary Hospital, Govandi, Mumbai, Maharashtra, India

Received: 01 May 2019

Revised: 05 July 2019

Accepted: 11 July 2019

***Correspondence:**

Dr. Dilesh A. Mogre,

E-mail: damogre@gmail.com

Copyright: © the author(s), publisher and licensee Medip Academy. This is an open-access article distributed under the terms of the Creative Commons Attribution Non-Commercial License, which permits unrestricted non-commercial use, distribution, and reproduction in any medium, provided the original work is properly cited.

ABSTRACT

Background: Chronic otitis media is one of the most common paediatric conditions but ear surgery in children is challenging. The high rates of failure have often questioned surgical management of dry asymptomatic perforations in pediatric age group. This study aimed to assess the results of butterfly cartilage myringoplasty in adolescent population with small to medium perforation in chronic otitis media.

Methods: We studied 15 cases in our prospective cross sectional observational study performed in the department of ENT at a secondary health centre in the eastern suburbs of Mumbai between October 2016 and September 2017. Children aged between 12 to 18 years with chronic otitis media mucosal inactive type with a central, small to medium sized tympanic membrane perforation and mild to moderate conductive hearing loss were included in this study.

Results: Results showed that the average age was 14.63 (SD=1.79 years) with an M: F ratio of 1:1.14. The mean hearing gain in cases with medium perforation was 11.75 dB and 5.7 dB in cases having small perforations two cases showed residual crescentic perforation.

Conclusions: Our study shows that endoscopic butterfly graft myringoplasty in small to medium perforation in adolescent age group has good success rate and is safe, quick and minimally invasive day care procedure.

Keywords: Adolescent children, Butterfly graft myringoplasty, Endoscopic ear surgery

INTRODUCTION

Chronic otitis media is one of the most common paediatric condition causing significant morbidity and frequent visits to the clinic. Paediatric ear surgery has multitude challenges including the notorious low success rate. The surgical management of dry asymptomatic small to medium perforations in pediatric age group is often debated. The factors affecting the success rate of paediatric ear surgery are age, laterality of the disease, adenoid hypertrophy, eustachian tube function and surgical technique. Dornhoffer in 2003 showed that cartilage as graft material gives better closure rates in paediatric as well as adult patients with no significant

impact on hearing outcomes.¹ Most studies assessing impact of age on the success of pediatric tympanoplasty utilized temporalis fascia as a graft material. There is a lack of adequate literature on cartilage as a graft material in adolescent ear surgeries. Surgical microscope is the workhorse of modern otology since its inception in the early 1950's. The development of rigid Hopkins rod lens endoscope has brought in a paradigm shift in otology with more focus on minimal invasive techniques.

It was Eavey in 1998 that used cartilage inlay for the closure of non-marginal tympanic membrane perforation versus the conventional on lay or underlay methods.² This method provides a quick, efficient and minimally invasive technique for the closure of small to medium

perforations. We would like to share our experience of this novel, minimally invasive technique in adolescent patients visiting our clinic.

Aim

The aim of the present study is to assess the results of butterfly cartilage myringoplasty in adolescent population with small to medium perforation in chronic otitis media.

METHODS

A prospective cross sectional observational study was performed in the department of ENT at a secondary health centre in the eastern suburbs of Mumbai between October 2016 and September 2017. A total of 15 patients between the ages of 12 to 18 years with chronic otitis media mucosal inactive type with a central, small to medium sized tympanic membrane perforation and mild to moderate conductive hearing loss were included in this study. Patients with Bellucci’s prognostic classification type 1 and 2 were included after performing audiological investigations.³ Patients with active otitis media, squamous otitis media, mixed or sensorineural hearing loss were excluded from the study.

Demographic data, preoperative and postoperative audiometric tests and follow-up data was collected at 1, 3 and 6 months postoperatively. Hearing threshold was measured at 0.5, 1, 2 and 4 KHz and Pure tone average (PTA) calculated.

This study was performed according to the Declaration of Helsinki and prior approval of institutional ethics review committee.

Surgical technique

After obtaining written informed consent from parents and assent of their wards, cases were performed as day care cases under general anaesthesia. 2% lignocaine with 1 in 2,00,000 adrenaline was used for infiltration using Plester’s technique. All surgeries were performed using 4.0 mm rigid endoscope and HD endoscopy system (Cymo B.V. Netherlands).



Figure 1: Harvesting butterfly graft for myringoplasty.

Under endoscopic visualization the edges of the perforation were freshened, imprint of the bleeding edge were taken on gel film and size of graft required measured. Tragal cartilage graft with perichondrium harvested and trimmed to the desired size. The cartilage graft was then held by forceps and a circumferential groove cut to an approximate depth of 2 mm (Figure 1).

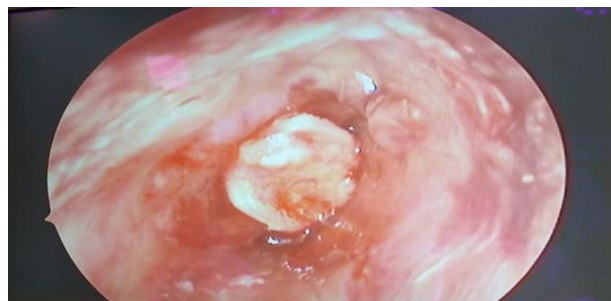


Figure 2: Intraoperative view of butterfly graft myringoplasty.

This forms the butterfly graft which was eased into the perforation using straight or curved picks and placed firmly into position (Figure 2). Once snugly fitted direct pressure was applied on the graft to assess stability, if found to be wobbling slight rotatory motion was performed till it fit properly. Medicated gel foam was used to pack the ear and tragal incision closed with a small dressing given to cover the ear.

RESULTS

In our study of 15 adolescent cases had an average age of 14.63 years with a standard deviation of 1.79 years with M: F ratio of 1: 1.14. The mean hearing gain in the nine cases with medium perforation was 11.75 dB, whereas in six cases having small perforations it was 5.7 dB (Figure 3).

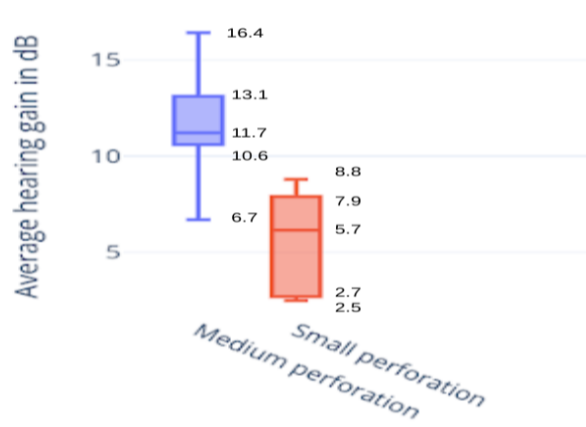


Figure 3: Comparison of hearing gain according to the size of the perforation.

The audiometric findings of each case were tabulated using Glasgow Benefit Plot and the hearing outcomes

grouped as symmetrical and asymmetrical hearing loss (Figure 4). In our series 13 patients had bilaterally symmetrical hearing at the end of six month while 2 had unilateral hearing impairment with the operated ear better.

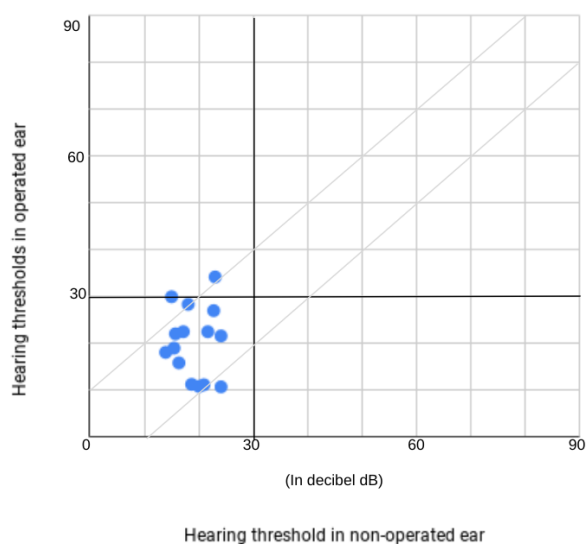


Figure 4: Glasgow benefit plot of 15 adolescent cases who underwent endoscopic butterfly graft myringoplasty.

Our series did not show any significant complications. In two cases the cartilage graft slipped leaving a crescentic residual perforation.

DISCUSSION

Management of chronic otitis media in children and adolescent patient group is one of the most common problem faced by paediatric otologists the world over. Ear surgery in adolescent age group has its challenges but it has been shown that between the ages of 8 to 16 appropriate case selection having dry middle ear, healthy contralateral ear along with diligent post-operative care help achieve promising results.⁴

The versatility of cartilage as a graft material has withstood the test of time. In 1998 Eavey proposed a novel interlay technique to tackle small to medium tympanic membrane perforations which traditionally were treated by either the overlay or the underlay method.^{2,5} He was a proponent of a minimally invasive approach for the management of paediatric otitis media. Neto modified this technique by avoiding the need for split thickness skin grafting.⁶ This technique was named so as the graft looks like a butterfly with wings. We found that harvesting and crafting of cartilage graft initially was difficult given the small anatomy and softness of cartilage. The thickness of cartilage gives a theoretical audiological disadvantage over thinner graft materials such as fascia or perichondrium but clinical studies fail to demonstrate such disadvantage.^{7,8} The use

of cartilage and perichondrium island graft, palisade technique and other have shown consistent healing results, the concern that the stiffness and mass of the cartilage graft may affect hearing results has not been proven so far.⁹ Our study also did not show any negative impact of cartilage as a graft material on hearing measured six months post-operatively. Bilaterally symmetrical and normal hearing was achieved in 13 cases. In our opinion cartilage as a graft material is a robust, versatile and easy to craft. Its thickness can offer advantage over future retraction and resorption.

Traditionally ear surgeries are performed under an operating microscope, the magnified stereoscopic vision being the chief advantage. But paediatric ear surgery often raises difficulties such as narrow ear canal, anterior hump in the auditory canal and more acute angle of the tympanic membrane make visualization difficult, especially the anterior aspect. The rigid endoscope offers a convenient minimally invasive alternative with options of angled vision. This helps reduction in incisions and dissection required to obtain adequate field of vision. Given these advantages the narrow space in the ear canal causes instrument crowding along with 2D picture and single hand for instrumentation increase the learning curve. Soakage due to bleeding requires frequent cleaning; these are a few disadvantages of endoscopic ear surgery.¹⁰

Our series achieves a success rate of 86.66% at 6 months, which is quite similar to studies using fascia in similar aged population.^{11,12} We chose to use the six month findings so as to assess long term outcomes. Studies have shown that outcomes of myringoplasty are influenced over time, more so in children due to the risk of recurrent respiratory infections. Occam's razor states that with the availability of numerous options for the resolution of same problem having similar outcomes, one should select the simplest solution.¹³ Thus, we suggest this novel surgical technique which is simple, quick and safe giving optimal hearing outcomes. This minimally invasive endoscopic technique to address small to medium perforations in adolescent age group requires a small incision and minimum dissection thus reducing the post-operative discomfort and medication; also the child can go home the same day reducing hospital stay. Lou et al have also come to a similar conclusion in their series performed endoscopically in children.¹⁴

CONCLUSION

Our study shows that endoscopic butterfly graft myringoplasty in small to medium perforation in adolescent age group has a good success rate and is safe, quick and minimally invasive day care procedure.

ACKNOWLEDGEMENTS

We are grateful towards our Chief Medical Officer Dr Rajashree Jadhav for her support and encouragement.

Funding: No funding sources

Conflict of interest: None declared

Ethical approval: The study was approved by the Institutional Ethics Committee

REFERENCES

1. Dornhoffer J. Cartilage tympanoplasty: indications, techniques, and outcomes in a 1,000-patient series. *Laryngoscope.* 2003;113:1844-56.
2. Eavey RD. Inlay tympanoplasty: cartilage butterfly technique. *Laryngoscope.* 1998;108(5):657-61.
3. Bellucci RJ. Dual classification of tympanoplasty. *Laryngoscope.* 1973;83:1754-58.
4. Uyar Y, Keles B, Koc S, Ozturk K, Arbag H. Tympanoplasty in pediatric patients. *Int J Pediatr Otorhinolaryngol.* 2006;70(10):1805-9.
5. Gersdorff M, Gerard JM, Thill MP. Overlay versus underlay tympanoplasty. Comparative study of 122 cases. *Rev Laryngol Otol Rhinol (Bord).* 2003;124(1):15-22.
6. Lubianca-Neto JF. Inlay butterfly cartilage tympanoplasty (Eavey technique) modified for adults. *Otolaryngol-Head Neck Surg.* 2000;123(4):492-4.
7. Kim JY, Oh JH, Lee HH. Fascia versus cartilage graft in type 1 tympanoplasty: audiological outcome. *J Craniofac Surg.* 2012;23(6):605-8.
8. Gerber MJ, Mason JC, Lambert PR. Hearing results after primary cartilage tympanoplasty. *Laryngoscope.* 2000;110(12):1994-9.
9. Yung M. Cartilage tympanoplasty: literature review. *J Laryngol Otol.* 2008;122(7):663-72.
10. Dundar R, Kulduk E, Soy FK, Aslan M, Hanci D, Muluk NB, et al. Endoscopic versus microscopic approach to type 1 tympanoplasty in children. *International J Pediatr Otorhinolaryngol.* 2014;78(7):1084-9.
11. Denoyelle F, Roger G, Chauvin P, Garabedian EN. Myringoplasty in children: predictive factors of outcome. *Laryngoscope.* 1999;109(1):47-51.
12. Knapik M, Saliba I. Pediatric myringoplasty: a study of factors affecting outcome. *Int J Paediatr Otorhinolaryngol.* 2011;75(6):818-23.
13. Halim A, Borgstein J. Pediatric myringoplasty: postaural versus transmeatal approach. *Int J Paediatr Otorhinolaryngol.* 2009;73(11):1580-3.
14. Lou ZC. The indication for endoscopic butterfly cartilage myringoplasty in children. *Auris Nasus Larynx.* 2017;44(4):498-9.

Cite this article as: Mogre DA, Ahmed FM, Bano PT. Endoscopic butterfly graft myringoplasty in small to medium perforation in adolescent chronic otitis media: our experience in 15 cases. *Int J Otorhinolaryngol Head Neck Surg* 2019;5:1299-302.