

## Original Research Article

# Comparison of magnetic resonance imaging and high frequency ultrasonography in carcinoma of tongue and its clinicopathological correlation: a prospective study

Javed A. Mir<sup>1</sup>, Sanober M. Masoodi<sup>2\*</sup>, Tajamul Rashid<sup>1</sup>, Suhail M. Masoodi<sup>3</sup>

<sup>1</sup>Department of Surgery, <sup>3</sup>Department of Anaesthesiology, Hamdard Institute of Medical Sciences and Research, New Delhi, India

<sup>2</sup>Department of Radiodiagnosis, Royale Kalindi Hospital, New Delhi, India

**Received:** 03 April 2019

**Revised:** 11 December 2019

**Accepted:** 13 December 2019

### \*Correspondence:

Dr. Sanober M. Masoodi,

E-mail: sanobermajid@rediffmail.com

**Copyright:** © the author(s), publisher and licensee Medip Academy. This is an open-access article distributed under the terms of the Creative Commons Attribution Non-Commercial License, which permits unrestricted non-commercial use, distribution, and reproduction in any medium, provided the original work is properly cited.

## ABSTRACT

**Background:** Carcinoma of oral tongue has a high propensity for cervical node metastasis. The thicker the tumour, the higher would be the risk of nodal metastasis and locoregional recurrence. Ultrasonography is used for evaluation of carcinoma tongue and tumour thickness and has a high correlation with histopathological findings.

**Methods:** Our study is a comparative prospective study conducted on 30 patients of carcinoma tongue. All patients underwent magnetic resonance imaging (MRI) scan and ultrasonography. The findings of MRI and ultrasound were correlated with clinical and pathological findings.

**Results:** MRI had a better correlation with histopathology for primary tumour characteristics and nodal assessment than ultrasonography. Ultrasound with a Pearson correlation coefficient of 0.809 correlated better than MRI for tumour thickness. Tumour thickness of >5 mm was associated with 27.2% nodal positivity rate whereas no patient with primary tumour thickness <5 mm had node positive disease.

**Conclusions:** Ultrasonography has a high correlation with histopathological thickness. Ultrasound thus seems to be an optimal technique in early stage, node negative tongue cancer for evaluation of tumour thickness and predict nodal status.

**Keywords:** Carcinoma tongue, MRI, Ultrasonography, Tumour thickness

## INTRODUCTION

Cancer of the oral cavity is group of distinct and overlapping disorders with differing etiology, clinical manifestation and treatment. Oral cancer arises in an individual who has used tobacco and alcohol. These lesions tend to occur on the lateral or ventral tongue, the floor of mouth (FOM), or the alveolar ridge, most often in men between the ages of 50 and 70 years, and are differentiated squamous cell carcinomas (SCC). Although most cases of oral SCC arise in individuals with

substantial exposure to tobacco and alcohol, cancer in the lateral oral tongue in younger persons without these risk factors has gained attention in recent years. Lichen planus and Fanconi anemia are associated risk factors in these cases.<sup>1,2</sup> Oral lesions are also seen in other persons who are immunosuppressed after bone marrow or other organ transplant attributed to graft-versus-host disease. In South Asia, buccal cancer is a common site for users of betel quid and associated substances including areca nut. Finally, while human papillomavirus is widely accepted as a causal factor for cancer arising in the

lymphoepithelium of the oropharynx, its presence in lesions of the oral cavity is less common, and its contribution to cancer development is uncertain.<sup>3-5</sup>

Tumor thickness >1.5 mm is associated with an increased risk of lymph node metastasis.<sup>6,7</sup> For tumors of the FOM or the oral tongue, spiro and others, in a review of 105 patients staged N0, reported a 12% rate of regional failure with a primary tumor thickness <2 mm as opposed to a failure rate of 47% for tumors thicker than 2 mm. Clearly, those patients with clinically N0 necks with a tumor thickness >1.5 to 2 mm warrant consideration for proactive management of the neck.<sup>8</sup> Whereas tumor thickness has been determined by microscopic evaluation of a full-thickness tumor biopsy, intraoral ultrasound has been explored as a noninvasive alternative.<sup>9</sup>

Carcinoma of tongue has a high propensity for cervical node metastasis which ranges from 37-58%.<sup>10,11</sup> The presence of lymph node metastasis is considered a bad prognostic indicator and is the most important prognostic marker for survival.<sup>12-14</sup> There is an unequivocal evidence that thicker the tumour, the higher would be the risk of locoregional recurrence, subclinical metastasis and poor prognosis.<sup>8,15,16</sup> In general, if the risk of occult metastasis exceeds 15-20%, then elective treatment of regional lymph nodes is recommended.<sup>17</sup> The actual incidence of occult disease in lymph nodes after initial treatment ranges from 21-42% and the treatment of clinically negative neck is a subject under debate.<sup>18</sup> Neck dissection has some complications and therefore unnecessary surgical treatment must be avoided. Clinical assessment of tumour size and thickness by visual inspection and palpation is insufficient in terms of objectivity and correction. Frozen section, cannot be used to study the entire margin and in addition is time consuming and do not clearly show the amount of clearance from invasive front of the tumour.<sup>19-21</sup>

Imaging techniques like computed tomography (CT) and magnetic resonance imaging (MRI) are useful for staging of the disease, but they are not adequate to assess the details of tumour, the structures involved and its morphological features. Imaging studies like CT or MRI also have limitations in accurately showing primary oral cancer that is less than 5 mm thick.<sup>22</sup> On the other hand, several studies have shown that tumour thickness on MRI directly correlates with the histologic thickness.<sup>23-25</sup> Preda et al found that tumour thickness of tongue carcinoma on MRI correlated directly with lymph node metastasis and mean tumour thickness in patients with lymph node metastasis was greater than those patients without metastasis.<sup>25</sup> The calculated sensitivity of MRI for detecting lymph node metastasis is 52.6% and the specificity is 94.5%.<sup>26</sup> The accuracy of MRI in identification of primary tumour is 87.1%.<sup>26</sup>

Recently ultrasonography (USG) for accurate pre-operative evaluation of the thickness of primary tongue cancer has become available.<sup>22,27-30</sup> USG is able to

visualize small changes in soft tissue accurately. For head and neck cancers, USG is used for observing primary lesions and cervical lymph nodes in pre-operative and follow up periods. It is also used to determine the sufficient surgical margin intraoperatively.<sup>29</sup> There is a good correlation between tumour thickness determined by USG and histologically proven thickness and is a useful adjunctive technique for assisting pre-treatment staging and preoperative evaluation of patients with oral tongue cancer.

At present, neck dissection with histological examination is the most reliable staging procedure, providing important prognostic information. There is a need for a non-invasive procedure that provides high quality prognostic information that approaches this gold standard.

Our study will be a part of this ongoing research and will help in formulating the best imaging modality in the pre-operative evaluation and staging of carcinoma tongue. Our study will compare the MRI and high frequency USG in delineating the disease extent and in measuring the tumour thickness of oral tongue SCC and correlate the findings keeping the histopathological findings as gold standard.

### **Objectives**

This prospective study aimed to compare the MRI and high frequency USG in squamous cell carcinoma of the oral tongue and its correlation with clinical and pathological findings. Primary objective is to measure the tumour thickness and its correlation with the pathological findings. Secondary objective is to compare the MRI and USG for their relative accuracy in determining the tumour thickness, extent of the disease and nodal involvement, keeping the histopathological findings as a gold standard.

## **METHODS**

### **Study area and population**

Our study is a comparative prospective study conducted on all the patients diagnosed with squamous cell carcinoma of oral tongue who reported to our out-patient department and were fulfilling the inclusion or exclusion criteria and were operated in our institution. The study was conducted after getting the necessary approval from the ethics and scientific committees of the institution.

The study was conducted over a period from July 2014 to May 2016.

### **Sample size**

Taking the Pearson product moment correlation of ultrasound and histopathological findings as 0.89, the sample size required is 10 with power 90 and  $\alpha$  (alpha)

5%.<sup>33</sup> Since the sample size is very small for the agreement study, we enrolled all patients for our study with minimum of 30 patients.

**Inclusion criteria**

All patients with biopsy proven squamous cell carcinoma of oral tongue were included in the study.

**Exclusion criteria**

Patients who have received neoadjuvant therapy, all metastatic and inoperable patients and patients who are medically unfit for surgery were excluded from the study.

All patients were advised MRI scan of face and neck and high frequency ultrasound of the tongue and neck was done in all patients. The patients were kept in supine position with neck extended. Dorsal and middle thirds of tongue as well as FOM were scanned from a submental access and the tip of the tongue directly with tongue stretched out of the mouth. The patient was asked to press the tongue onto the FOM. During a medial- sagittal scan, the patient was asked to lift the tip of the tongue which is identical to ventral thirds. When the free part of the tongue was raised, air entered between the inferior surface and FOM. Middle and dorsal thirds of tongue remained visible. Tongue movements like swallowing or speaking were at times of value to delineate infiltration.

The normal tongue has a homogenous echotexture. It was delineated by air in the oral cavity and by the acoustic shadows of the chin and hyoid bone on sagittal scans, as well as by the horizontal mandibular rami on transverse scans. Muscles of FOM and extrinsic muscles were hypochoic. Tumours appeared hypochoic.

On MRI, primary tumour had a signal intensity higher than that of normal tongue on T2 weighted images. On T1 weighted images the tumour was isointense with normal tongue.

The results of the MRI and USG were evaluated. Clinical staging of the patients was done as per the tumour, node, metastasis classification and the patients were operated upon. The specimen was oriented, marked and sent to the pathology laboratory in formalin container. Clinical findings and the results of pre-operative imaging were compared with the histopathology findings and evaluated statistically.

**Statistical analysis**

Data was described as mean±SD and percentages. For qualitative measurements such as size of tumour and tumour thickness, Pearson correlation coefficients have been worked out to find the degree of resemblance between the two. However, the conclusions are primarily based on agreement analysis where the individual differences between the values obtained by different

procedures have been studied. For this, the average difference and the 95% confidence interval (CI) for difference in means were calculated. If the C.I exceeded the clinical tolerance then the agreement has been considered to be poor.

For qualitative measurements, cross tabulation of data was done and Cohen kappa was calculated to assess the degree of agreement. The agreement is considered poor when kappa is 0.0, slight when kappa is 0.01-0.20, fair when kappa is 0.21-0.40, moderate when kappa is 0.41-0.60, substantial when kappa is 0.61-0.80 and almost perfect agreement when kappa is 0.81-0.99. Kappa of 1 means perfect agreement.

Statistical significance was defined as p<0.05. Software SPSS-19.0 was used for data analysis. MS excel and MS word were used for graphs, tables etc.

**RESULTS**

The age distribution of these 30 cases ranged from 38 to 86 years (mean=55.77±9.68 years) with a peak incidence in 51 to 60 years age group (43.3%, n=13) with a male preponderance (male=56.6%, n=17 and female 60%, n=13) (Table 1 and 2). 93.3 % patients (n=28) presented with the history of non-healing ulcer where as 6.6% patients (n=2) presented with complaints of non-healing ulcer and pain. 63% patients (n=19) were alcoholic, 50% patients (n=15) used to chew gutkha or tobacco, 63% patients (n=19) were cigarette smokers. No patient had family or personal history of cancer of upper aerodigestive tract. 13.3% patients (n=4) had sharp tooth on the side of the ulcer.

**Table 1: Socio-demographic characteristics of the studied population.**

Demographic characteristics	N	%
Age (in years)	31-40	3.3
	41-50	26.6
	51-60	43.3
	Above 60	26.6
	Total	100.0
	Mean±SD (range)	55.77±9.68 (38-86)
Gender	Male	56.6
	Female	43.33
Dwelling	Urban	73.3
	Rural	26.6
Occupation	Unskilled	26.6
	Semi-skilled	40.0
	Skilled	33.3

**Clinical tumour characteristics**

53.3% patients had maximum tumour dimension of <2 cm, 43.3% patients had maximum tumour dimension of 2-4 cm and 3.3% patients had maximum tumour

dimension of >4 cm. In 96.6% patients no lymph node was palpable in the neck. One patient (3.3%) had N2b nodal status. Enlarged nodes were seen at level 2, 3 and 4. 53.3% patients were stage 1, 40% patients were stage 2, one patient was stage 3 and one patient was stage 4a. 53.3% patients were T1N0, 40% patients were T2N0, one patient was T3N0 and one patient was T2N2b.

**Ultrasound tumour characteristics**

63.3% patients had maximum tumour dimension of <2 cm, 23.3% patients had maximum tumour dimension of 2 to 4 cm and 13.3% patients had maximum tumour dimension of >4 cm. 46.6% patients were N0 (having lymph nodes which were not suggestive of being malignant, size <1 cm, no loss of fatty hilum, oval). 36.6% patients were N1 (suggestive of a malignant node, size >1 cm, hypoechoic, round, loss of fatty hilum) and 16.6% patients were having N2b status. Level 2 node was enlarged in 26.6%, level 3 in 10% patients, level 1, 2, 3 in 10% patients and level 2, 3, 4 and 1, 2, 3, 4 were enlarged in 3.3% patients each. 40% patients had tumour thickness of 3-5 mm. 30% patients had tumour thickness of 6 to 8 mm while as 16.6% patients had tumour thickness of 9-11 mm.

Largest nodal size was 4-6 mm in 46.6% patients, 7-9 mm in 30% patients and >10 mm in 23.3% patients. Largest node was seen at level 1b in 40% cases, level 2 in 56.6% cases and level 3 in 3.3% cases.

36.6% patients were stage 1, 3.3% were stage 2, 43.3% were stage 3 and 16.6% were stage 4a. 36.6% patients were T1N0, 3.3% were T2N0, 6.6% were T3N0, 20% were T1N1, 16.6% were T2N1, 6.6% were T1N2b, 3.3% T2N2b and 6.6% were T3N2b.

**MRI tumour characteristics**

60.0% patients had maximum tumour dimension of <2 cm, 30.0% patients had maximum tumour dimension of 2-4 cm and 10.0% patients had maximum tumour

dimension of >4 cm. 56.6% patients were N0. 26.6% patients were N1 and 16.6% patients were having N2b status. Level 2 node was enlarged in 20.0%, level 3 in 6.6% patients, level 1, 2, 3 in 6.6% patients and level 2, 3, 4 and 1, 2, 3, 4 and 2, 3 were enlarged in 3.3% patients each. 33.3% patients had tumour thickness of 3-5 mm. 43.3% patients had tumour thickness of 6-8 mm while as 10.0% patients had tumour thickness of 9-11 mm. 14.4% had tumour thickness of >11 mm.

Largest nodal size was 4 to 6 mm in 56.6% patients, 7-9 mm in 10% patients and 10 to 12 mm in 23.3% patients and >13 mm in 10.0% patients. Largest node was seen at level 1b in 20% cases, level 2 in 76.6% and level 3 in 3.3% cases.

36.6% patients were stage 1, 16.6% were stage 2, 30% were stage 3 and 16.6% were stage 4a. 36.6% patients were T1N0, 16.6% were T2N0, 6.6% were T3N0, 16.6% were T1N1, 6.6% were T2N1, 6.6% were T1N2b, 6.6% were T2N2b and 3.3% were T3N2b.

**Pathological tumour characteristics**

26.6% patients had maximum tumour dimension of <2 cm, 70.0% patients had maximum tumour dimension of 2 to 4 cm and 3.3% patients had maximum tumour dimension of >4 cm. 80% patients were N0. 6.6% patients were N1 and 13.3% patients were having N2b status. Level 2 node was involved in 6.6%, level 1, 2, 3 and level 1, 2, 3, 4 in 3.3% patients each, level 2, 3 in 6.6% patients.

6.6% patients had tumour thickness of <3 mm. 20% cases had tumour thickness of 3 to 5 mm. 46.6% patients had tumour thickness of 6 to 8 mm while as 26.6% patients had tumour thickness of 9 to 11 mm.

Largest nodal size was 4 to 6 mm in 60.0% patients, 7-9 mm in 6.6% patients and 10 to 12 mm in 16.6% patients and >13 mm in 16.6% patients. Largest node was seen at level 1b in 20% cases, level 2 in 80% cases.

**Table 2: Age and gender distribution of the studied subjects.**

Age (in years)	Male		Female		Total	
	N	%	N	%	N	%
31-40	1	3.3	0	0	1	3.3
41-50	3	10.0	5	16.6	8	26.6
51-60	7	23.3	6	20.0	13	43.3
>60	6	20.0	2	6.6	8	26.6
<b>Total</b>	17	56.6	13	43.3	30	100.0
<b>Mean±SD (Range)</b>	53.2±7.6 (42, 67)		58.6±8.2 (43, 72)		56.4±8.3 (42, 72)	

26.6% patients were stage 1, 53.3% were stage 2, 6.6% were stage 3 and 13.3% were stage 4a. 26.6% patients were T1N0, 53.3% were T2N0, 6.6% were T2N1, 10.0% were T2N2b and 3.3% were T3N2b. Well differentiated tumours comprised 3.33% cases, moderately

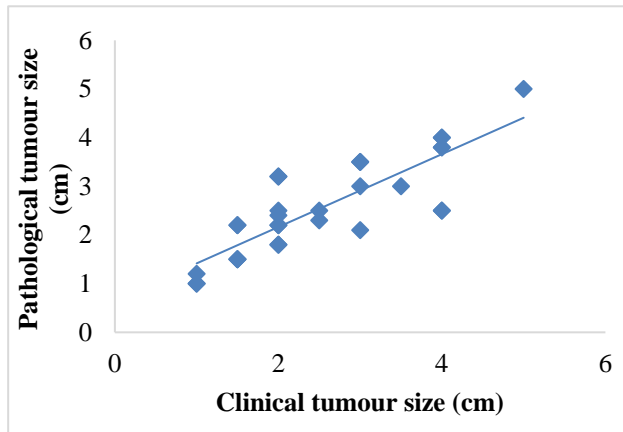
differentiated tumours comprised of 60% cases while as 6.6% patients were having poorly differentiated histology. Angioinvasion was seen in 9 patients (30%). Perineural invasion was seen in 11 (36.3%) and extracapsular extension was seen in 4 (13.3%) cases. No patient had involvement of submandibular gland. 8

patients had tumour thickness of less than 5 mm while as 22 patients had tumour thickness of more than 5 mm. No patient with thickness <5 mm had node positive disease and 6 patients with tumour thickness >5 mm was node positive.

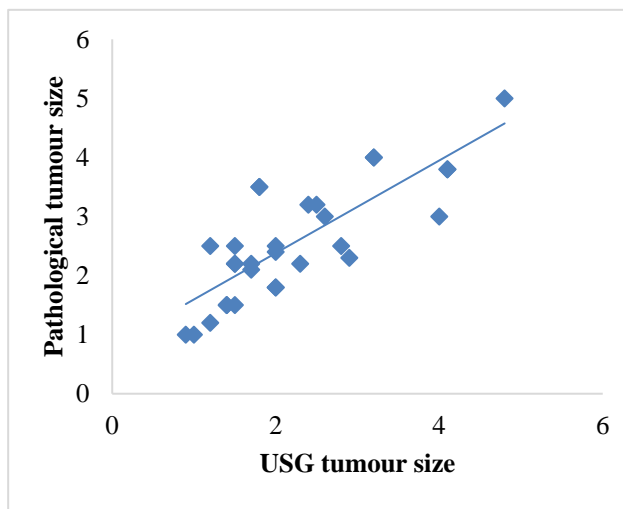
**Statistical analysis**

**Maximum tumour dimension**

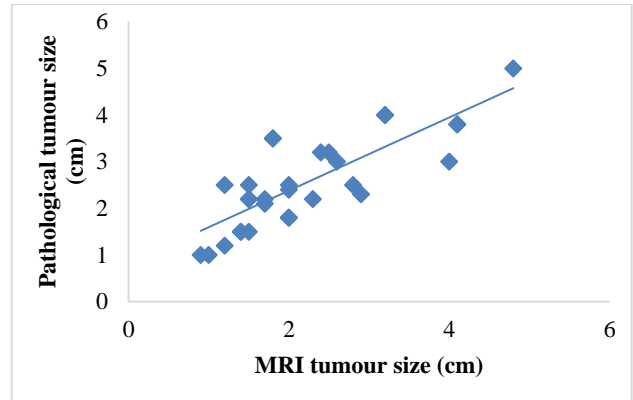
The Pearson correlation coefficient for the correlation between clinical and pathological maximum tumour dimension was 0.839 with p value of 0.000. (CI=-0.24658 to -0.186581), (Figure 1). The Pearson correlation coefficient for the correlation between USG and pathological maximum tumour dimension was 0.723 with p value of 0.000 (CI=-0.63051 to -0.11616), (Figure 2). The Pearson correlation coefficient for the correlation between MRI and pathological maximum tumour dimension was 0.804 with p value of 0.000 (CI=-0.554 to -0.106), (Figure 3).



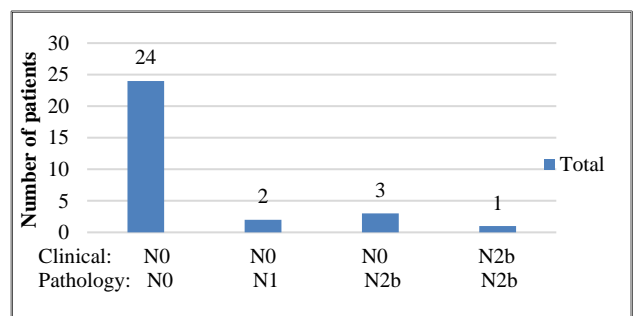
**Figure 1: Correlation of clinical and pathological maximum tumour dimension B (cm).**



**Figure 2: Correlation of USG and pathological maximum tumour dimension (cm).**



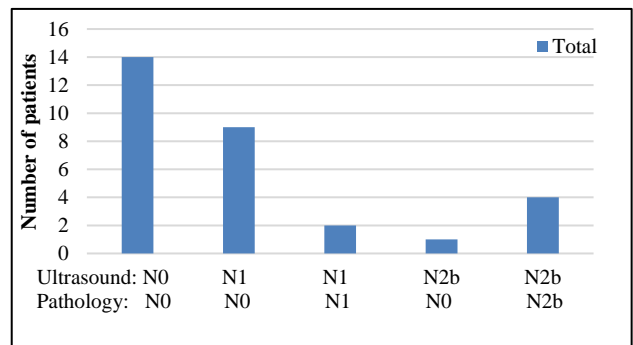
**Figure 3: Correlation of MRI and pathological maximum tumour dimension (cm).**



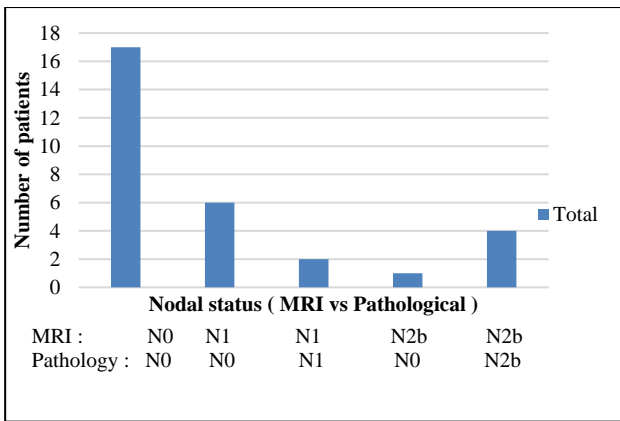
**Figure 4: Correlation of clinical vs pathological node status.**

**Node status**

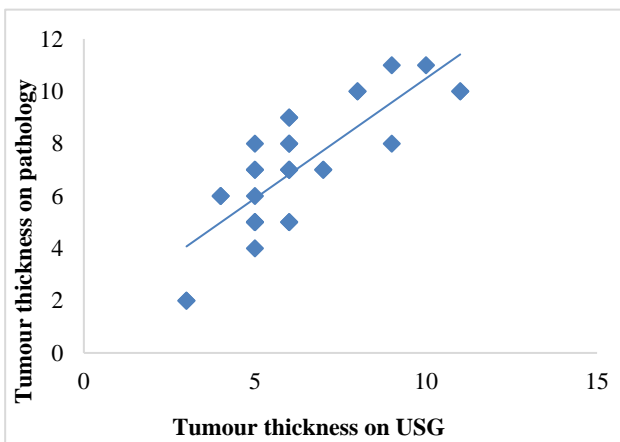
For correlation of clinical vs pathological node status p value calculated by Pearson Chi square test was 0.035. Kappa calculated to see the agreement between the two was 0.25 (p=0.015), (Figure 4). For correlation of ultrasound and pathological node status, p value calculated by Pearson Chi-square test was 0.000. Kappa calculated to see the agreement between the two was 0.425 (p=0.000), (Figure 5). For correlation of MRI vs pathological node status, p-value calculated by Pearson Chi-square test was 0.000. Kappa, calculated to see the agreement between the two was 0.539 (p=0.000) (Figure 6).



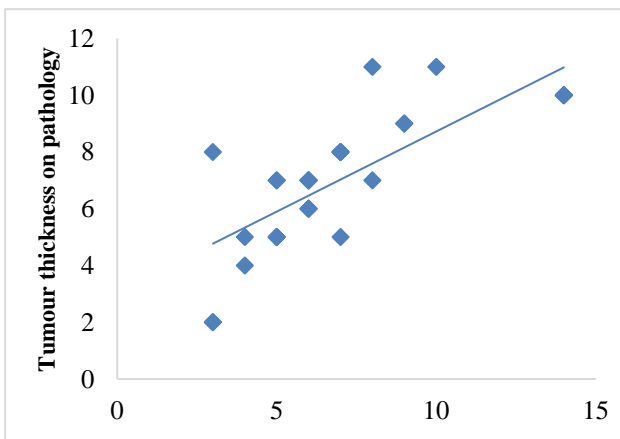
**Figure 5: Correlation of ultrasound and pathological nodal status.**



**Figure 6: Correlation of MRI vs pathological node status.**



**Figure 7: Correlation of tumour thickness (mm), USG vs pathological.**



**Figure 8: Correlation of tumour thickness (mm), MRI vs pathology.**

**Tumour thickness**

For correlation of tumour thickness on USG vs pathology, p value calculated by Pearson Chi-square test was 0.000. The Pearson correlation coefficient was 0.809 (Figure 7). For MRI vs pathology findings, p value

calculated by Pearson Chi-square test was 0.000. The Pearson correlation coefficient was 0.779 (Figure 8).

**DISCUSSION**

The presence of lymph node metastasis in carcinoma tongue is considered a bad prognostic indicator and is the most important prognostic marker for survival.<sup>12-14</sup> There is an unequivocal evidence that thicker the tumour, the higher would be the risk of locoregional recurrence, subclinical metastasis and poor prognosis.<sup>15-17</sup>

At present, neck dissection with histological examination is the most reliable staging procedure, providing important prognostic information. There is a need for a non-invasive procedure that provides high quality prognostic information that approaches this gold standard. Imaging techniques like CT and MRI are useful for staging of the disease, but they are not adequate to assess the details of tumour, the structures involved and its morphological features. Recently high-resolution USG for accurate pre-operative evaluation of the thickness of primary tongue cancer has become available.<sup>23,28-31</sup> There is a good correlation between tumour thickness determined by USG and histologically proven thickness and is a useful technique for pre-treatment staging and preoperative evaluation of patients with oral tongue cancer.

In our study, MRI with a correlation coefficient of 0.804 correlated better with histopathology than ultrasound (correlation coefficient=0.723) for maximum tumour dimension criteria. In our study, for the nodal assessment, the MRI showed better agreement (kappa=0.539) than clinical (kappa=0.25) and ultrasound examination (kappa=0.425). Ultrasound with a Pearson correlation coefficient of 0.809 correlated better than MRI (Pearson correlation coefficient of 0.779) for the tumour thickness.

In our study, 8 patients had tumour thickness of less than 5 mm. 22 patients had tumour thickness of more than 5 mm. No patient with tumour thickness of less than 5 mm had node positive disease whereas 6 patients (27.2%) with tumour thickness more than 5 mm had node positive disease.

Shintani et al was among the first to demonstrate the correlation in tongue carcinoma by comparing preoperative ultrasound estimation of tumour thickness with measurements obtained from histological sections.<sup>27</sup> They concluded that intraoral USG is an excellent method to delineate tumour extent and measure tumour thickness in tongue carcinomas and found that the incidence of cervical metastasis increased markedly when the depth of invasion was over 5 mm. There was a significant correlation (p<0.001) between measurements by USG and histological sections. Since then many authors have published similar results with other subsites like FOM cancers also showing direct correlation

between ultrasound tumour thickness and neck metastasis.

In a study done by Mark et al, there was a significant correlation between the preoperative ultrasound and histopathological measures of tumour depth (correlation coefficient 0/981,  $p=0.001$ ).<sup>32</sup> Tumour depth and T stage were significant predictors of cervical lymph node metastasis ( $p=0.0351$  and  $0.0300$  respectively). In their study with tumour thickness  $<5$  mm in depth, the neck metastasis rate was 0% as compared to 65% in the group with tumour thickness of 5 mm or more. Lodder et al showed that tumour thickness measured by ultrasound correlated well with histopathology (correlation coefficient=0.87).<sup>9</sup> MRI tumour thickness had a correlation coefficient of 0.54 with histopathology. Tumour thickness of less than 7 mm carried a risk of lymph node metastasis of 12% whereas in tumours with thickness of  $>7$  mm, the risk increased to 57%. In the study conducted by Kaneoya et al, they observed that in their study tumour thickness on ultrasound ranged from 1.0 mm to 12.2 mm.<sup>33</sup> The histological section results yielded thickness of 0.4 mm to 15.9 mm and there was significant correlation between histological section and ultrasound image with a Pearson correlation coefficient of 0.89.

Preda et al showed a significant direct correlation between the measured histological and measured MRI tumour thickness (correlation coefficient=0.80,  $p<0.0001$ ).<sup>10</sup> Park et al performed a retrospective analysis to evaluate the accuracy of MRI in measuring the invasion depth of different oral cavity cancers. The authors calculated Pearson correlation coefficient for histological and imaging invasion depths in oral tongue, tongue base and tonsillar cancer of 0.949, 0.941 and 0.578 respectively.<sup>34</sup> This study showed direct correlation between radiologic invasion depth and node metastasis in oral tongue and tongue base cancers and calculated the invasion depth cut-off value of 9.5 mm and 14.5 mm respectively.

In the study conducted by Yesuratnam et al, pre-operative tumour thickness as determined by ultrasound demonstrated high correlation and MRI moderate correlation with histological tumour thickness.<sup>35</sup> They concluded that USG be used as the initial modality of choice for preoperative assessment of tumour thickness.

In the literature, discussion remains as to which cut-off is optimal and in the more recent studies, cut-off values range from 3-8 mm. It remains difficult to choose a reliable cut-off point for elective neck treatment. The elective neck treatment is mainly based on the expected risk of occult metastasis. With respect to this risk assessment, Spiro et al concluded that for clinically N0 oral cancer, elective neck dissection was indicated in patients with depth of invasion of more than 2 mm because in these tumours the risk of metastasis reached 40%.<sup>8</sup> Veness et al conducted a study and concluded that

elective treatment to the ipsilateral neck is not indicated in all patients with anterior tongue cancer.<sup>36</sup> However for patients with tumour thickness of more than 5 mm, it is recommended that they undergo treatment to the ipsilateral neck in the form of supra omohyoid neck dissection.

From this and other studies it is clear that the high frequency USG has a high correlation with histopathological thickness. Ultrasound thus seems to be the optimal technique in evaluating the preoperative tumour thickness and is more reliable than MRI for the measurement of tumour thickness.

## CONCLUSION

The results of this study indicate that preoperative USG in the squamous cell carcinoma of the oral tongue is a feasible and a reliable imaging technique in early stage, node negative tongue cancer for evaluation of tumour thickness and prediction of nodal metastasis. All currently available literature shows depth of invasion or tumour thickness measurements of the primary tumour, most often only in small groups. The identification of a cut-off with adequate utility for clinical decision making requires large studies and independent validation.

## ACKNOWLEDGEMENTS

I would like to thank all my teachers and colleagues who helped me during this research.

*Funding: No funding sources*

*Conflict of interest: None declared*

*Ethical approval: The study was approved by the Institutional Ethics Committee*

## REFERENCES

1. Lodi G, Scully C, Carrozzo M, Griffiths M, Sugerman PB, Thongprasom K, et al. Current controversies in oral lichen planus: report of an international consensus meeting. Part 2. Clinical management and malignant transformation. *Oral Surg Oral Med Oral Pathol Oral Radiol Endod.* 2005;100(2):164-78.
2. Alter BP. Cancer in Fanconi Anemia 1927-2001. *Cancer.* 2003;97:425-40.
3. Demarosi F, Soligo D, Lodi G, Moneghini L, Sardella A, Carrassi A. Squamous cell carcinoma of the oral cavity associated with graft versus host disease: report of a case and review of the literature. *Oral Surg Oral Med Oral Pathol Oral Radiol Endod.* 2005;100(1):63-9.
4. Koch WM, Lango M, Sewell D, Zahurak M, Sidransky D. Head and neck cancer in nonsmokers: a distinct clinical and molecular entity. *Laryngoscope.* 1999;109:1544-51.
5. Gillison ML, Koch WM, Capone RB, Spafford M, Westra WH, Wu L, et al. Evidence for a causal

- association between human papillomavirus and a subset of head and neck cancers. *J Natl Cancer Inst.* 2000;92:709-20.
6. Mohit-Tabatabai MA, Sobel HJ, Rush BF, Mashberg A. Relation of thickness of floor of mouth stage I and II cancers to regional metastasis. *Am J Surg.* 1986;152(4):351-3.
  7. Wallwork BD, Anderson SR, Coman WB. Squamous cell carcinoma of the floor of the mouth: tumour thickness and the rate of cervical metastasis. *ANZ J Surg.* 2007;77(9):761-4.
  8. Spiro RH, Huvos AG, Wong GY, Spiro JD, Gnecco CA, Strong EW. Predictive value of tumor thickness in squamous carcinoma confined to the tongue and floor of the mouth. *Am J Surg.* 1986;152(4):345-50.
  9. Lodder WL, Teertstra HJ, Tan IB, Pameijer FA, Smeele LE, van Velthuysen MF, et al. Tumour thickness in oral cancer using an intra-oral ultrasound probe. *Eur Radiol.* 2011;21(1):98-106.
  10. Franceschi D, Gupta R, Spiro RH, Shah JP. Improved survival in the treatment of squamous carcinomas of the oral tongue. *Am J Surg.* 1993;166:360-5.
  11. Byers RM, El-Naggar AK, Lee YY, Rao B, Fornage B, Terry NH, et al. Can we detect or predict the presence of occult nodal metastasis in patients with squamous carcinoma of the oral tongue? *Head Neck.* 1998;20:138-44.
  12. Shah JP, Medina JE, Shaha AR, Schantz SP, Marti JR. Cervical lymph node metastasis. *Curr Probl Surg.* 1993;30:277-335.
  13. Taniguchi Y, Okura M. Prognostic significance of perioperative blood transfusion in oral cavity squamous cell carcinoma. *Head Neck.* 2003;25:931-6.
  14. Okura M. Lymph node metastasis. In: Pandali SG, ed. *Recent research developments in cancer.* Trivandrum, India: Transworld research Network; 2002: 331-337.
  15. Rasgon B, Cruz R, Hilsinger R, Sawicki JE. Relation of lymph node metastasis to histopathological appearance in oral cavity and oropharyngeal carcinoma. A case series and literature review. *Laryngoscope.* 1989;99(11):1103-10.
  16. Shintani S, Matsura H, Hasegawa Y, Nakayama B, Fujimoto Y. The relationship of shape of tumour invasion to depth of invasion and cervical node metastasis in squamous cell carcinoma of the tongue. *Oncology.* 1997;54:463.
  17. Shah JP, Patel SG. *Head and Neck surgery and oncology.* 3rd ed. London: Mosby; 1990.
  18. Amarai TMP, Carvalho DFA, Pinto CA, Kowalski LP. Predictive factors of occult metastasis and prognosis of clinical stages I and II squamous cell carcinoma of the tongue and floor of the mouth. *Oral Oncol.* 2004;40:780.
  19. Byers RM, Bland KI, Borlase B, Luna M. The prognostic and therapeutic value of frozen section determination in the surgical treatment of squamous cell carcinoma of the head and neck. *Am J Surg.* 1978;136:525.
  20. Oral RA, Aisner S. Accuracy of frozen section in assessing margins in oral cancer resection. *J Oral Maxillofac Surg.* 1997;55:669.
  21. Scholl P, Byers RM, Batsakis JG, Wolf P, Santini H. Microscopic cut through of cancer in the surgical treatment of squamous carcinoma of the tongue: Prognostic and therapeutic implications. *Am J Surg.* 1986;152:354.
  22. Shintani S, Yoshihama Y, Ueyama Y, Terakado N, Kamei S, Fijimoto Y, et al. The usefulness of intraoral ultrasonography in the evaluation of oral cancer. *Int J Oral Maxillofac Surg.* 2001;30:139-43.
  23. Lam P, Au-Yeung KM, Cheng PW, Wei WI, Yuen AP, Trendell-Smith N, et al. Correlation MRI and histologic tumour thickness in the assessment of oral tongue cancer. *AJR Am J Roentgenol.* 2004;182:803-8.
  24. Iwai H, Kyomoto R, Ha Kawa SK, Lee S, Yamashita T. Magnetic resonance determination of tumour thickness as predictive factor of cervical metastasis in oral tongue carcinoma. *Laryngoscope.* 2002;112:457-61.
  25. Preda L, Chiesa F, Calabrese L, Latronico A, Bruschini R, Leon ME, et al. Relationship between histologic thickness of tongue carcinoma and tumour estimated from preoperative MRI. *Eur Radiol.* 2006;16:2242-48.
  26. Ng SH, Yen TC, Liao CT, Chang JT, Chan SC, Ko SF, et al. F-FDG PET and CT/MRI in oral cavity squamous cell carcinoma. A prospective study of 124 patients with histologic correlation. *J Nucl Med.* 2005;46(7):1136-43.
  27. Shintani S, Nakayama B, Matsura H, Hasegawa Y. Intraoral ultrasonography is useful to evaluate tumour thickness in tongue carcinoma. *Am J Surg.* 1997;173:345.
  28. Yuen APW, Ng RW, Lam PF, Ho A. Preoperative measurement of tumour thickness of oral tongue carcinoma with intraoral ultrasonography. *Head Neck.* 2008;30:230.
  29. Songra AK, Ng SY, Farthing P, Hutchison IL, Bradley PF. Observation of tumour thickness and resection margin at superior excision of primary oral squamous cell carcinoma: assessment by ultrasound. *Int J Oral Maxillofac Surg.* 2006;35:324.
  30. Yamane M, Ishii J, Izumo T, Nagawawa T, Amagasa T. Non-invasive quantitative assessment of oral tongue cancer by intraoral ultrasonography. *Head Neck.* 2007;29:307.
  31. Mettler FA, Schultz K, Kelsey CA, Khan K, Sala J, Kligerman M. Grey scale ultrasonography in the evaluation of neoplastic invasion of base of tongue. *Radiology.* 1979;133(3):781-4.
  32. Taylor SM, Drover C, Maceachern R, Bullock M, Hart R, Psooy B, et al. Is preoperative ultrasound accurate in measuring tumour thickness and predicting the incidence of cervical metastasis in oral cancer. *Oral Oncology.* 2010;46(1):38-41.



33. Kaneoya A, Hasegawa S, Tanaka Y, Omura K. Quantitative analysis of invasive front in tongue cancer using ultrasonography. *J Oral Maxillofac Surg.* 2009;67:40-6.
34. Park JO, Jung SL, JOO YH, Jung CK, Cho KJ, Kim MS. Diagnostic accuracy of MRI in the assessment of tumour invasion depth in oral /oropharyngeal cancer. *Oral Oncology.* 2011;47(5):381-6.
35. Yesuratnam A, Wiesenfeld D, Tsui A, Iseli TA, Hoorn SV, Ang MT, et al. Preoperative evaluation of oral tongue squamous cell carcinoma with intraoral ultrasound and magnetic resonance imaging-comparison with tumour thickness and accuracy in guiding patient management. *Int J Oral Maxillofac Surg.* 2014;43(7):787-94.
36. Veness MJ, Morgan GJ, Sathiyaseelan Y, Gebiski Y. Anterior tongue cancer and the incidence of cervical lymph node metastasis with increasing tumour thickness: should elective treatment to the neck be standard practice in all patients. *ANZ J Surg.* 2005;75:101-5.

**Cite this article as:** Mir JA, Masoodi SM, Rashid T, Masoodi SM. Comparison of magnetic resonance imaging and high frequency ultrasonography in carcinoma of tongue and its clinicopathological correlation: a prospective study. *Int Surg J* 2020;7:239-47.