

Original Research Article

Clinical peculiarities of preauricular sinus abscess: a tertiary health centre experience

Daniel J. Aliyu*, Abdullahi Mohammed

Department of Otorhinolaryngology, Usmanu Danfodiyo University Teaching Hospital, Sokoto, Nigeria

Received: 10 March 2019

Revised: 17 May 2019

Accepted: 20 May 2019

*Correspondence:

Dr. Daniel J. Aliyu,

E-mail: danoaliyu@yahoo.com

Copyright: © the author(s), publisher and licensee Medip Academy. This is an open-access article distributed under the terms of the Creative Commons Attribution Non-Commercial License, which permits unrestricted non-commercial use, distribution, and reproduction in any medium, provided the original work is properly cited.

ABSTRACT

Background: Preauricular sinus abscess is a sequellae of an infected squamous epithelial lined preauricular sinus tract, commonly seen in pediatric population. This study aim to determine the clinical profile of preauricular sinus abscess in Sokoto, Nigeria.

Methods: This was a retrospective study carried out between June 2011 to May 2014 of all patients with preauricular sinus abscess that presented to the department of ear, nose and throat. Data extracted from clinical records were bio-data, duration of symptoms, and history of recurrence and associated congenital anomalies, sides of involvements, sensitivity results, treatments options and outcome. Data obtained were analyzed using simple statistical tables.

Results: Seventeen patients were seen during the study period with preauricular abscess (PA). There were 5 (29.4%) males and 12 (70.6%) females with a ratio M:F of 1:2.4. The age range was from 5-34 years. Prevalence of PA is high in the 1-10 years age group. Six patients (35.3%) had ruptured abscess. Unilateral PA involving the left side in 12 (70.6%) patients was most common. Two patients had previous incision and drainage prior to presentation. *Staphylococcus aureus* was the most common isolated organism. Twelve patients (70.6%) were lost to follow up after surgical drainage and 5 (29.4%) patients had wide local excision of the sinus tract to remove all vestiges of squamous epithelium as opposed to simple sinectomy. One patient had recurrence.

Conclusions: We emphasize the need for proper health education of definitive surgery after surgical drainage of preauricular sinus abscess.

Keywords: Preauricular abscess, Preauricular sinus, Sinectomy, Surgical excision

INTRODUCTION

Preauricular sinus is a benign congenital disorder first described by Van Heusinger in 1864.^{1,2} One of the most common abnormalities of the head and neck region. They are mostly unilateral but occasionally bilateral. Usually occurs at the anterior margin of the ascending limb of the helix of the external ear.² The generally accepted theory attributes the development of a preauricular sinus to incomplete or defective fusion of the six auditory hillocks of His. Genetically, preauricular sinus is inherited in an incomplete autosomal dominant pattern, with reduced

penetrance pattern and variable power of expression commonly seen in bilateral cases.^{2,3}

This and other congenital ear malformation are sometimes associated with renal anomalies.³

Preauricular sinus is rare in caucasians while in Africans; its incidence is 4-10%.³ Patients rarely sought for medical care, as preauricular sinus is usually asymptomatic unless infected.^{2,3} Although can present as an infected and discharging sinus associated with abscess formation and can easily be misdiagnosed as a sebaceous cyst or a furunculus.^{4,6} Preauricular sinus are prone to recurrent

infection mainly by *Staphylococcus aureus* organism and usually presents with an intense irritation, pain, swelling/oedema, ear discharge, fever, headache and when the sinus punctum is blocked pus accumulates leading to abscess formation. Surgical intervention becomes an absolute option once the sinus gets infected and this will reduce recurrence, the incidence been reported to be 19-40%.⁴ Surgical drainage is necessary in the acute phase where abscess is present with institution of appropriate sensitive antibiotics.^{2, 5-7}

There is dearth of medical literature on preauricular sinus abscess in our region as obtained in other parts of the world. This study was carried out to determine the clinical profile of preauricular sinus abscess among Nigerians in Sokoto, Northwest Nigeria.

METHODS

In our study of 17 cases, which includes adults and children that presented or were referred to the department of ear nose and throat, Usmanu Danfodiyo University Teaching Hospital, Sokoto, Nigeria with complaint of painful discharging swelling of the ear as their major symptom over a three-year period June 2012 to May 2015. From health information records of these patients the demographic data, duration of symptoms, history of recurrence and associated congenital anomalies, sides of involvements, sensitivity results, abdominopelvic ultrasound reports, results of hearing assessments, treatments options and follow up visits were retrieved. Surgical drainage was carried out in all the patients and five out of 17 patients had wide local excision of the sinus four to six weeks after the abscess drainage.

Included in this study are preauricular abscess patients with complete clinical records. While excluded are those whose clinical records has incomplete data and asymptomatic patient with preauricular sinus. Data obtained were analyzed using simple descriptive epidemiology statistical table and figures (Figure 1).

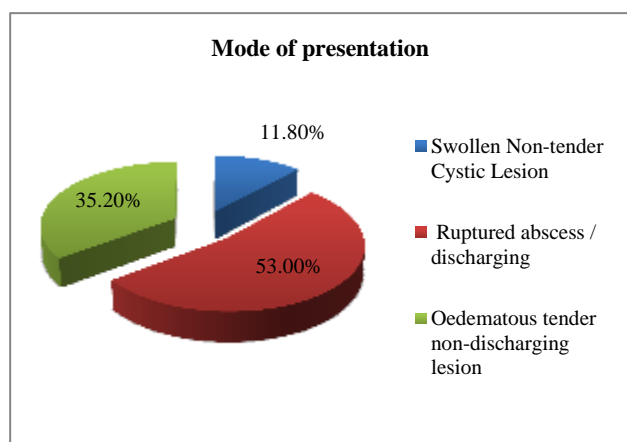


Figure 1: Mode of presentation of preauricular sinus abscess.

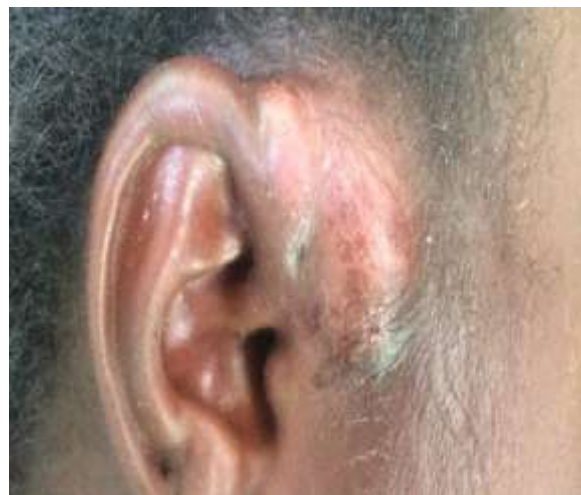

Figure 2: Discharging preauricular sinus abscess.

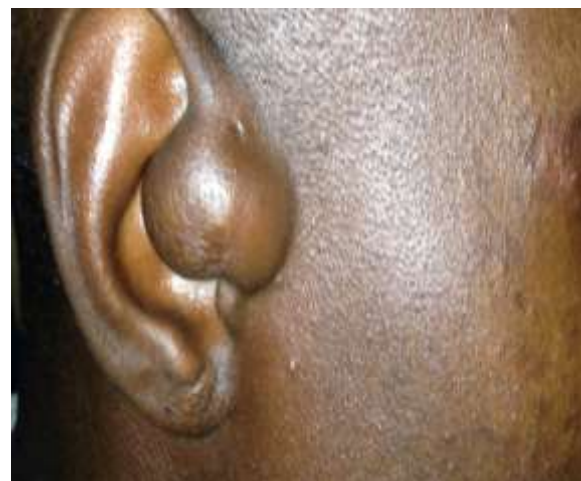

Figure 3: Preauricular sinus cyst.

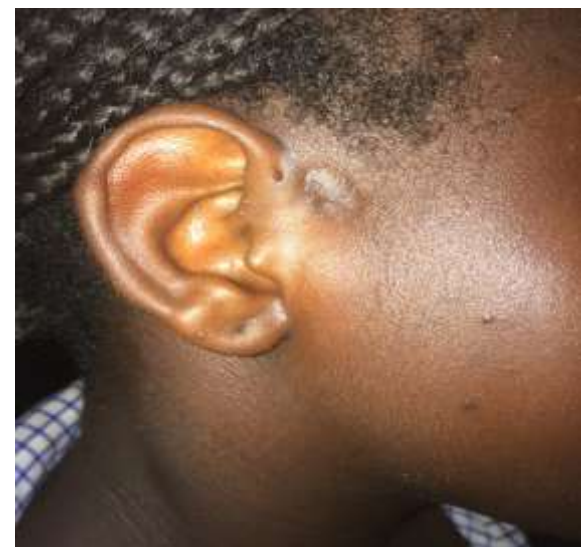

Figure 4: Healed scar of a ruptured preauricular sinus abscess.

RESULTS

Seventeen patients with preauricular abscess (PA) were analyzed. Twelve (70.6%) were Female and 5 patients (29.4%) were male with M:F ratio of 1:2.4. The age range was from 5-34 years. Prevalence of PA is high in the 1-10 years age group. Ruptured abscess was noticed in 6 (35.3%) of patients. Unilateral involvement of PA was observed in all the patients. Twelve patients presented with PA on the left side out of which 75% were female. Two patients had previous incision and drainage. *Staphylococcus aureus* was the commonest isolated organism. None of the patients had associated congenital anomalies. Twelve patients (70.6%) were lost to follow up after surgical drainage and 5 (29.4%) patients had surgical excision of the sinus. One patient had recurrence.

Table 1: Age and sex distribution of preauricular sinus abscess.

Age group (years)	Male	Female	Total	Percentage (%)
1-10	3	8	11	64.7
11-20	1	2	3	17.6
21-30	1	1	2	11.8
31-40	-	1	1	5.9
Total	5	12	17	100

Table 2. Side of involvement of preauricular sinus abscess.

Side involved	Male	Female	Total
	N (%)	N (%)	N (%)
Right	2 (11.8)	3 (17.6)	5 (29.4)
Left	3 (17.6)	9 (53.0)	12 (70.6)

DISCUSSION

Preauricular sinus is a congenital anomaly that occurs usually at the anterior margin of the ascending limb of the helix of the external ear.² Patients with preauricular sinus seek for medical attention only when the aural pit is infected, abscess formation or forms a cystic swelling near the sinus (Figure 2 and 3). The prevalence of infection/abscess formation is high in the age group 1-10 years (Table 1).

These may be attributed to lack of adequate medical knowledge and caregiver's inattention to preauricular sinus opening. It is also considered to be minor problems amongst the very few and not seeking medical advice, as most patients with these sinuses are asymptomatic. Gradual accumulation of debris in the branching tracts of the sinus predispose it to be infected and can subsequently leads to abscess formation. Gender predisposition in the development of preauricular sinus has been inconsistency in different reported studies.⁶⁻⁷ In present study, Preauricular sinus abscess affects both

sexes with high female preponderance 75%, which is similar to findings reported in other part of the world. Factors for these variations are still unclear. Some studies suggested that this may either be due to varieties of cosmetics in facial make-ups amongst females, the high rate of self-medication engaged by the male patients rather than presenting in the hospital for proper medical treatment and racial difference since reports shows some genetic association.⁷⁻⁹ Jimoh et al reported a high prevalence in males, which is at variance with other studies in which it affect both sexes equally.¹⁰

Although side of involvement is been reported as equal, in our series the left side is commonly involved with 12 (70.6%) cases than right with 6 (35.2%) cases and could be due to the small sample size in our study or a chance occurrence (Table 2). Usually the symptomatic sinus presents as recurrent painful preauricular swelling, discharging sinus and can easily be misdiagnosed as a sebaceous cyst (Figure 3).

Ruptured PA/discharging sinus 53% is the commonest presentation in this study followed by edematous tender non-discharging lesion. These may be due to repeated infection and inadequate proper medical treatment especially in the acute phase of infection and ultimately results in higher recurrence rate Figure 4. However, studies have shown that repeated sinus infectious process produces fibrotic and edematous changes which may distort the normal tissue structure and sinus tract making definitive surgery more difficult thereby leaving squamous epithelium behind to cause recurrence.¹¹ *Staphylococcus aureus* was the commonest isolated organism in 9 (53%) of the 17 patients in our study while the culture of the discharge in 5 (29.4%) patients yielded no significant growth after 48 hours incubation. This may be attributed to indiscriminate use of antibiotics in self-medication before presenting to a specialist for proper treatment.^{7,11} None of the patients had associated congenital anomalies such as hearing or renal impairments.^{1,2}

Complete wide local surgical excision of the preauricular sinus tract were all squamous epithelium are removed is the gold standard of treatment.^{2,5,12} However, surgical drainage is necessary in the acute phase where abscess is present with institution of appropriate sensitive antibiotics.¹³ which was the case in the present study. With the resolution of the acute infection and adequate counseling, only 5 (29.4%) of the 17 patients consented and had definitive wide local surgical excision of the sinus tract and no facial nerve injury. Factors for declining definitive surgical intervention despite the high recurrence nature of the symptoms is still unclear.

Some studies reported socio-cultural practices especially in Africa, were preauricular sinus is believed to be an endowment for divine powers to be wealthy.^{7,14} Also the resolution of the symptoms following institution of sensitive antibiotics results in patients decline to present

for surgery. In the presence of an abscess prior to definitive surgical treatment, recurrence rate is higher which may depend on the surgical technique and the experience of the surgeon.^{2,15} One patient in the present study had recurrence.

CONCLUSION

In this study, a large proportion of patients were lost to follow up after surgical drainage and institution of sensitive antibiotics. We emphasize the need for increased level of community awareness of the clinical peculiarities of preauricular sinus through health education while advocating for definitive surgery after surgical drainage of preauricular sinus abscess, as this will reduce the recurrence rate.

Funding: No funding sources

Conflict of interest: None declared

Ethical approval: The study was approved by the Institutional Ethics Committee

REFERENCES

1. Ostrower ST, Bent JP. Preauricular cysts, Pits and Fissures, 2018. Available at: <http://www.medicine.medscape.com/article/1118768-overview>. Accessed on April 19, 2018.
2. Bruce I, Nichani J. Microtia external ear abnormalities. In: Watkinson JC, Clarke RW, Kubba H, Aldren CP, Bamiou D, Irving RM (eds). Scott-Brown's Otorhinolaryngology, Head and Neck Surgery. 8th edition. London, UK: Taylor and Francis group; 2018: 165-168.
3. An SY, Choi HG, Lee JS, Kim JH, Yoo SW, Park B. Analysis of incidence and genetic predisposition of preauricular sinus. Int J Pediatr Otorhinolaryngol. 2014;78(12):2255-7.
4. Lee KY, Woo SY, Kim SW, Yang JE, Cho YS. The prevalence of preauricular sinus and associated factors in a nationwide population-based survey of South Korea. Otol Neurotol. 2014;35(10):1835-8.
5. Tan T, Constantinides H, Mitchell TE. The preauricular sinus: A review of its aetiology, clinical presentation and management. Int J Pediatr Otorhinolaryngol. 2005;69(11):1469-74.
6. Scheinfeld NS, Silverberg NB, Weinberg JM, Nozad V. The preauricular sinus: a review of its clinical presentation, treatment and associations. Pediatr Dermatol. 2004;21:191-6.
7. Adegbiyi WA, Alabi BS, Olajuyin OA, Nwawolo CC. Presentation of preauricular sinus and preauricular sinus abscess in Southwest Nigeria. Int J Biomed Sci. 2013;9(4):260-3.
8. Gupta R, Agrawal A, Poorey VK. Preauricular sinus: a clinicopathological study. Int J Res Med Sci. 2015;3:3274-7.
9. Chang PH, Wu CM. An insidious preauricular sinus presenting as an infected postauricular cyst. Int. J. Clin Pract. 2005;59:370-2.
10. Jimoh OR, Alabi BS, Adebayo S. Prevalence of preauricular sinus among Nigerians. Surgery Journal. 2008;3:61-3.
11. Rataiczak H, Lavin J, Levy M, Bedwell J, Preciado D, Reilly BK. Association of recurrence of infected congenital preauricular cysts following incision and drainage vs fine-needle aspiration or antibiotic treatment: a retrospective review of treatment options. JAMA Otolaryngol Head Neck Surg. 2017;143(2):131-4.
12. Baatenburg de Jong RJ. A new surgical technique for treatment of preauricular sinus. Surgery. 2005;137:567-70.
13. Shim HS, Kim DJ, Kim MC, Lim JS, Han KT. Early one-stage surgical treatment of 42 infected preauricular sinus. Eur Arch Otorhinolaryngol. 2013;270:3127-31.
14. Adeyemo A, Ijaluola G. Socio-cultural beliefs in the management of preauricular sinus. The Internet Journal of Head and Neck Surgery. 2006;1(2).
15. Gur E, Yeung A, Al-Azzawi M. The excised preauricular sinus in 14 years of experience: is there a problem? Plast Reconstr Surg. 1998;102:1405-8.

Cite this article as: Aliyu DJ, Mohammed A. Clinical peculiarities of preauricular sinus abscess: a tertiary health centre experience. Int J Otorhinolaryngol Head Neck Surg 2019;5:836-9.