

Original Research Article

Comparative study of conventional versus microdebrider assisted endoscopic sinus surgery in sinonasal polyposis

Bindia Ghera*, Manish Munjal, Hemant Chopra

Department of ENT, Dayanand medical college and hospital, Ludhiana, Punjab, India

Received: 24 June 2016

Revised: 28 June 2016

Accepted: 05 July 2016

*Correspondence:

Dr. Bindia Ghera,

E-mail: bindiaghera@yahoo.com

Copyright: © the author(s), publisher and licensee Medip Academy. This is an open-access article distributed under the terms of the Creative Commons Attribution Non-Commercial License, which permits unrestricted non-commercial use, distribution, and reproduction in any medium, provided the original work is properly cited.

ABSTRACT

Background: Functional endoscopic sinus surgery, conventional or with powered instruments is the standard surgical modality in sinonasal polyposis refractive to medical therapy. The recent modality, microdebrider assisted endoscopic sinus surgery offers better therapeutic approach for patients when compared to endoscopic sinus surgery with the conventional instruments. The objective was to evaluate the utility of microdebrider in endoscopic sinus surgery versus conventional instruments and to compare the intraoperative and postoperative results in both the methods.

Methods: A prospective, randomized, comparative study was conducted on 30 patients with bilateral sinonasal polyposis. The subjects were selected by applying all the inclusion and exclusion criteria and divided into two groups i.e. the right and left side of nose were operated and compared for efficacy of microdebrider and conventional instruments. Each patient served as his or her own control. This study emphasizes the utility of microdebrider. It compares the intraoperative and postoperative results in the conventional and microdebrider assisted endoscopic sinus surgery.

Results: The intraoperative mean blood loss and duration of surgery were significantly higher in the conventional group (p-value <0.001) as compared to microdebrider group. Postoperative symptom and endoscopy scores (discharge, scarring, crusting and polyp recurrence) were significantly higher in the conventional group (p-value <0.001) as compared to the microdebrider group in 6 months follow up.

Conclusions: Microdebriders are more effective as compared to conventional endoscopic sinus surgery due to lesser intraoperative bleeding (relatively bloodless) and duration of surgery, better postoperative endoscopic and symptom scores, combine cutting and suction in a single tool, enabling accurate and precise tissue removal without damaging the surrounding mucosa, less scarring/synechia, fewer complications.

Keywords: Sinonasal polyposis, Conventional instruments, Microdebrider, Endoscopic sinus surgery

INTRODUCTION

Sinonasal polyp refers to edematous projections of nasal mucosa extending through nasal cavity and paranasal sinuses. Prevalence is 4% in general population.¹ Functional endoscopic sinus surgery, conventional or with powered instruments is standard surgical modality in

sinonasal polyposis refractive to medical therapy. Microdebriders are the most commonly used powered instruments in endoscopic sinus surgery and continues to evolve in rhinologic surgery.² The aim of study was to evaluate the utility of microdebrider in endoscopic sinus surgery versus conventional instruments and to compare

intraoperative and postoperative results in both the methods.

METHODS

A prospective randomized controlled study was conducted on 30 patients with bilateral sinonasal polyposis at Dayanand medical college and hospital fulfilling inclusion and exclusion criteria between year 2014 and 2015. Only cases with CT scan showing Lund-Mackay total score of ≥ 8 on each side were included.¹⁰ All patients underwent endoscopic polypectomy with microdebrider on one side (group I) and conventional instruments (group II) on other side. Uncinectomy, middle meatus antrostomy, anterior and posterior ethmoidectomy was done in all cases. All polypoidal tissue resected and sent for histopathological examination. Comparison was made intraoperatively for duration of surgery and blood loss in surgical field in both the groups. Postoperatively, follow up was done after 1 week, at 3 and at 6 months for recurrence of polyps, discharge, scarring, crusting and symptomatic improvement using Lund-Mackay scoring system and visual analog scale in both the groups.^{11,12} Statistical method used was SPSS version-17.

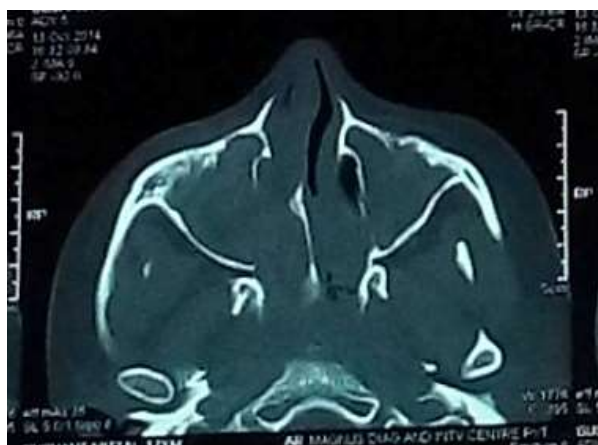

Figure 1: CT nose and PNS (axial view) with Lund-Mackay score of >8 on each side.



Figure 2: Stryker Essex microdebrider handpiece (with power suction and irrigation canula).



Figure 3: Blade tip (straight).

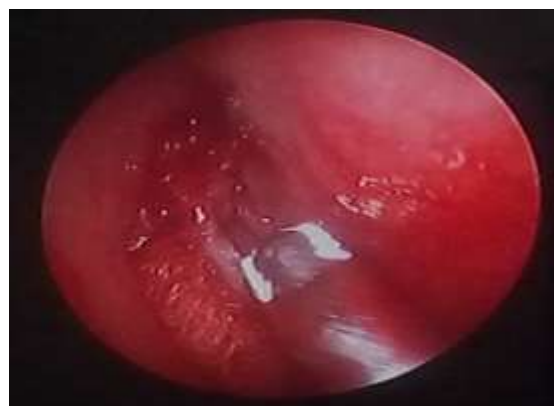

Figure 4: Bloodless field with microdebrider.

RESULTS

All the 30 patients presented with bilateral nasal obstruction and nasal discharge. 80% patients presented with complaint of sneezing.

Table 1: Patient demographics and results (n=30).

Parameters (mean)	Microdebrider group (mean±SD)	Conventional group. (mean±SD)	P-value
Age (years)	34.57±15.34	34.57±15.34	1.00
Gender (M/F)	22/8	22/8	0.668
Pre-op DNE Polyp grade	1.67±0.84	1.73±0.78	0.423
CT- Lund-Mackay Score	8.87±1.31	8.63±1.13	0.243
Intraoperative blood loss (ml)	81.90±7.26	109.93±6.20	<0.001
Duration of surgery (minutes)	56.67±10.33	75.70±3.91	<0.001
Boerzaart grading score	2	3	-
Absolute eosinophil count	0.34±0.24	0.34±0.24.	1.00

90% of the patients complained of persistent symptoms. Age distribution ranged from 14-62 years. Male:female ratio of 2.75. Significant improvement of symptoms (90 %) was seen in 6 months with microdebrider (p-value <0.001).

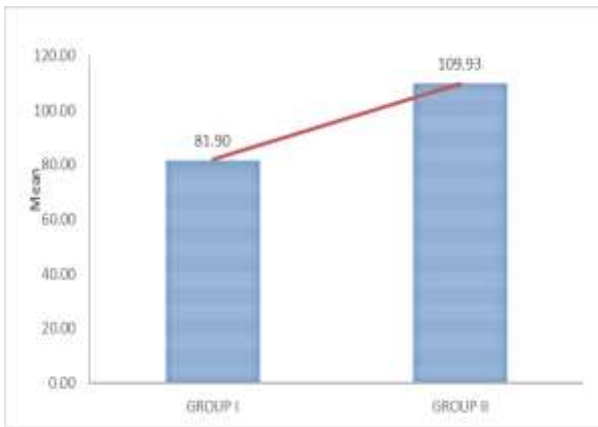


Figure 5: Comparison of intraoperative blood loss (ml) shows decreased mean blood loss in microdebrider group (I).

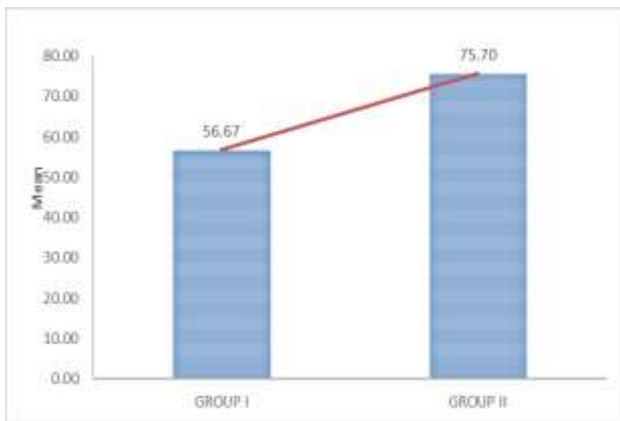


Figure 6: Comparison of duration of surgery (min) shows shorter duration of surgery in microdebrider group (I).

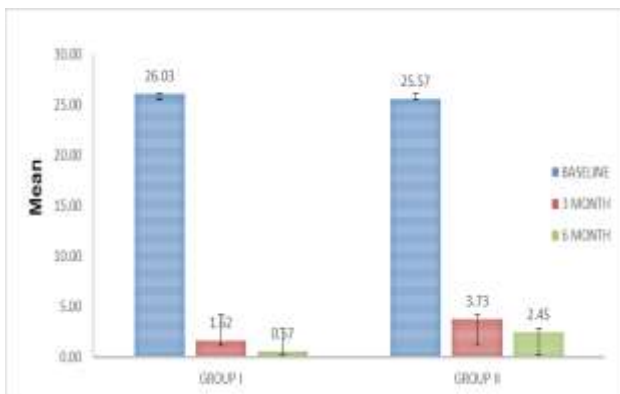


Figure 7: Post-op mean total score on visual analog scale.

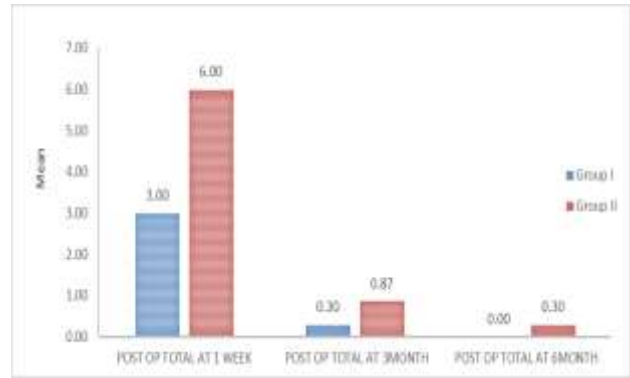


Figure 8: Post-op. mean total score on diagnostic nasal endoscopy.

Table 2: Post-op diagnostic nasal endoscopy and visual analog scale comparison at baseline and at 6 months. (MEAN±SD) (n=30).

Parameters	Baseline (mean±SD)	At 6 months (mean±SD)	P-VALUE
Discharge-I	1.00 ± 0.00	0.00±0.00	< 0.001
Discharge-II	2.00 ± 0.00	0.10±0.31	< 0.001
Crusting-I	1.00 ± 0.00	0.00±0.00	< 0.001
Crusting-II	2.00 ± 0.00	0.00±0.00	< 0.001
Scarring-I	1.00 ± 0.00	0.00±0.00	< 0.001
Scarring-II	2.00 ± 0.00	0.10±0.31	< 0.001
Polyp Recurrence-I	0.00 ± 0.00	0.00±0.00	0.045
Polyp recurrence-II	0.00 ± 0.00	0.10±0.31	0.075
Nasal obstruction-I	6.80 ± 0.55	0.13±0.41	< 0.001
Nasal obstruction-II	6.77 ± 0.77	0.60±0.94	< 0.001
Nasal discharge-I	3.87 ± 0.11	0.13±0.43	< 0.001
Nasal discharge-II	3.87 ± 0.11	0.47±0.81	< 0.001
Sneezing-I	3.17 ± 2.04	0.07±0.37	< 0.001
Sneezing-II	3.17 ± 2.04	0.07±0.37	< 0.001
Facial pain/pressure-I	4.20 ± 0.41	0.10±0.31	< 0.001
Facial pain/pressure-II	4.20 ± 0.41	0.43±0.69	< 0.001
Overall discomfort-I	8.00 ± 0.74	0.13±0.41	< 0.001
Overall discomfort-II	7.57 ± 1.74	0.88±1.16	< 0.001

CT scan grading of the disease done using Lund-Mackay scoring system for radiological grading of sinus system. For all sinus systems 0=No abnormalities, 1=Partial opacification, 2=Total opacification. For osteomeatal complex 0= not occluded, 2=occluded.

Table 3: Comparison of various studies.

Study/ year	Patients	Symptom improvement	Synechia forma	Patency of middle meatal antrostomy	Polyp Recurrence	Saccharin transport time	Nasal volume (Acoustic rhinometry)	Bleeding	Duration of surgery	P value
Sellivanova et al ³	24	Better at 3,6 and 13 months	No difference	No difference	No difference	No difference	No difference	↓	↓	> 0.05
Sauer et al ⁴	50	Better at 3 weeks	No difference	No difference	↓	not reported	not reported	↓	↓	
kursat et al ⁵	(97) 46 microdebrider, 51 standard technique	Better	↓	improved	improved	-	improved	↓	↓	<0.05 ANOVA- no difference
Singh R et al ⁶	(40) 20 conventional ESS, 20 Microdebrider	Better at 6 months	No difference	improved	↓	not reported	not reported	↓ Precise bloodless surgery	↓	0.004
Magdy et al ⁷	200	Better	↓	improved	↓	improved	improved	↓	↓	Not Significant
Cornet et al ⁸	60	no difference at 3 months	↓	improved	↓	improved	improved	No difference	↓	Not Significant
Kakkar V et al ⁹	(40) 20 microdebrider, 20 conventional	Better at 14 days and after 2 months	↓ 5% - microdebrider ,20% conventional	improved	↓	not reported	not reported	not reported	not reported	<0.0001

Scoring on diagnostic nasal endoscopy

0=absence of polyp, 1=polyp in middle meatus, 2=polyp beyond middle meatus

0=no discharge, 1=clear thin discharge, 2=thick purulent discharge.

0=absent, 1=mild, 2=severe (crusting and scarring)

DISCUSSION

Comparison of these various studies showed better results post-operatively with microdebrider at 3 months and 6 months as seen in this study. Blood loss during surgery and duration of surgery is also decreased as in present study. Sinonasal polyposis has a significant effect on quality of life.^{13,14} The high tendency to recurrence and risk of systemic side effects with steroids make surgical management more favourable for recurrent cases.¹⁵ The recent modality, microdebrider assisted endoscopic sinus surgery offers better therapeutic approach for patients when compared to endoscopic sinus surgery with the conventional instruments.^{6,8}

The major advantages in utilizing the microdebrider as the primary instrument in endoscopic sinus surgery is the cost-effectiveness of the tool as multiple functions may be achieved with a single instrument, serving advantageous in a limited working area in narrow nasal cavities having proximity to skull base. The continuous integrated suction provides better visualization of the operative field due to continuous removal of blood, tissue and bone fragments and serves as a significant advantage by eliminating the need to move in and out of the surgical field, increasing the ability to continuously work in that area without loss of time that may occur when switching instruments.¹⁶⁻¹⁸ The conventional instruments used in endoscopic sinus surgery, on the other hand by their punching, tearing and stripping action creates a bloody surgical field, no mucosal preservation, scarring and more risk of complications.¹⁹ So, emphasizing the utility of microdebriders the study was conducted in a prospective randomized controlled manner to investigate the efficacy and safety of microdebriders in endoscopic sinus surgery in sinonasal polyposis as compared to conventional endoscopic sinus surgery.

Age and sex distribution

Maximum number of patients were in the age group of 16-30 years (43.3 %). Mean age was 34.57 years. Standard deviation (SD) was 15.34 with mean age \pm (SD) of 34.57 \pm 15.34 in this study with male:female ratio of 2.75. Bakari et al, reported a peak incidence of 33 years.²⁰ Larsen et al, reported similar results of 252 danish patients. They observed nasal polyposis most commonly in patients who were 40-60 years old. Male: female ratio was 2.9 in the ages 40-50.²¹ Drake et al reported that average age of onset is approximately 42 years.²²⁻²⁴ Mc

Fadden et al reported similar results.²⁵ Settupane et al nasal polyposis are uncommon under the age of 20.²⁶ Larsen et al, estimated incidence of nasal polyposis in patients less than 16 years of age is 0.1 to 0.216%.²¹ Settupane et al, reported equal distribution of males and females, 50.2 vs 49.8%.²⁷

Diagnostic significance of absolute eosinophil count

Absolute eosinophil count can distinguish between eosinophilic and non-eosinophilic chronic rhinosinusitis with nasal polyposis has been reported in literature. Absolute eosinophil counts in this study ranged from 0.0-0.8. The mean absolute eosinophil count in this study was 0.34 and standard deviation (SD) was 0.24 with mean \pm SD was 0.34 \pm 0.24. Minimum count was 0.00 and maximum count was 0.70. Maximum number of patients (40%) was in the range 0.00-0.2. Hu Y et al, reported that peripheral eosinophil absolute count and percentage were independently and significantly associated with eosinophilic chronic rhinosinusitis with nasal polyposis. An absolute blood eosinophil count $\geq 0.215 \times 10^9$ /L yielded a sensitivity of 74.2% and a specificity of 86.5%.²⁸ Vaidya et al, reported a good correlation of nasal smear eosinophilia with blood absolute eosinophil count in allergic rhinitis and with histological findings in cases of allergic nasal polyps.²⁹

Role of preoperative computerised tomography

A routine preoperative computerized tomography scan was performed for all patients in this study to know the extent of the disease. Total score of 24 (12 on each side is used). The patients in this study had score ≥ 8 . The mean preoperative computerized Lund-Mackay score in this study for group 1 (microdebrider) was 8.87 with standard deviation of 1.31 (8.87 \pm 1.31) and 8.82 with standard deviation of 1.13 (8.82 \pm 1.13) in group 2 (conventional ESS). There was no statistically significant difference between the groups and data was comparable. 90 % of the patients scored from 8 to 10. Preoperative CT provides data for intraoperative stereotactic guidance systems, which are used to manage complex disease, and for revision surgery. Gheriani H et al, found no statistically significant difference in outcome following functional endoscopic sinus surgery between those with minimal changes and those patients with more extensive involvement on C.T. patients benefited from surgery irrespective of pre-operative CT score.³⁰ Sharp et al, found significant correlation between Lund-Mackay pre-operative scores and the outcome of FESS at 24 months, however this correlation did not reach statistical significance when patients were stratified according to the presence of a systemic diagnosis thought to predispose to chronic rhinosinusitis (e.g. asthma, ASA, atopy, bronchiectasis etc.).³¹ Metson et al, stressed on the importance of new studies on modifications and improvements on present systems and production of new staging systems having wide field of usage.^{32,33}

Preoperative visual analog scale scores and diagnostic nasal endoscopy scores

No statistically significant difference was seen in the preoperative visual analog scale and diagnostic nasal endoscopy polyp grades in both the groups in this study and data was comparable. ($1.67\pm 0.84/1.73\pm 0.78$). Overall discomfort preoperatively was higher in the group 1 as compared to group 2 ($8.00\pm 0.74/7.57\pm 1.74$). An assessment of the severity and impact of symptoms should be made by asking the patient to mark on a visual analogue scale of 0-10. In this study a maximum score was seen for nasal obstruction in both group 1 (6.80) and group 2 (6.77), followed by nasal discharge, sneezing, facial pain of 3.87, 3.17 and 4.20 respectively. Similar results have been reported by Dufour X et al, Poetkar DM et al also reported similar results.^{34,35} Magdy et al and Kakkar V et al, also reported results in a similar manner with a little difference in their scores.^{7,9}

Postoperative visual analog scale and diagnostic nasal endoscopy scores

In this study post-operative follow up was done at 1 week, at 3 months and at 6 months. Visual analog symptom score was compared at 3 months and at 6 months. Statistically significant improvement was seen in microdebrider group as compared to conventional group ($p < 0.001$). Mean of total points on VAS postoperatively at 3 months was 1.62 ± 3.30 and 0.57 ± 1.76 at 6 months ($p < 0.001$) in group 1 and in group 2, mean total points at 3 months was 3.37 ± 5.10 and 2.45 ± 3.58 at 6 months ($p < 0.001$). The results of symptomatic improvement of nasal obstruction, nasal discharge, sneezing, facial pain/pressure and overall discomfort were better in group 1 as compared to group 2 at 3 months and 6 months postoperatively. Similar results have been reported in other studies by Magdy et al, Kakkar V et al.^{7,9} On postoperative diagnostic nasal endoscopy, Lund Mackay scoring was better in microdebrider group as compared to conventional group. In group 1, polyp recurrence, clear thin discharge and mild scarring was seen in 10% of the cases with average score of 1 at 3 months follow-up. No recurrence was seen at 6 months. In group 2, polyp recurrence was seen in 16.66% of the patients at 3 months and in 10% of the patients at 6 months follow up. 23.33% had clear thin discharge at 3 months follow-up and 10% at 6 months follow-up. Mild scarring was present in 16.66% of the patients at 3 months and 10% of the patients at 6 months follow up. This proves that microdebrider offered better results at 6 months as compared to conventional instruments. Meloni et al, estimated that the recurrence rate of sinonasal polyposis varied from 15% to 25% postoperatively. The polyp recurrence of only 10% in present proves microdebriders are more effective than conventional endoscopic sinus surgery.³⁶ Scarring/synechia was lower in present study with microdebriders due to mucosal preservation and minimal tissue trauma. Kakkar V et al, Singh R et al Magdy et al, Kursat et al, Sauer et al, Selivanova et al

Bernstein et al, Krouse et al, all compared microdebrider assisted endoscopic sinus surgery with conventional endoscopic sinus surgery.^{3-8,37,38} They all reported better postoperative scores with microdebriders.

Intraoperative blood loss

This study showed statistically significant mean intraoperative blood loss in group 1 of 81.90 ml and standard deviation was 7.26 with $\text{mean}\pm\text{SD}=81.90\pm 7.26$ and in group 2 of 109.93 ml and standard deviation was 6.20 with $\text{mean}\pm\text{SD}=109.93\pm 6.20$ ($p\text{-value} < 0.001$). Cornet ME et al, for estimated blood loss during surgery they found no differences in both the groups.⁸ Magdy et al, reported that dryness of the operative field was better with powered instruments (microdebrider) as compared to conventional instruments with Boerzaart grading scale.⁷ Krouse et al, reported an average of 19.5 ml of blood in powered instruments and 44.5 ml of blood in traditional cases.³⁸ Lesser bleeding was attributed in present study to hemostasis due to continuous integrated suction and less adjacent mucosal damage. Lesser traumatic surgery due to better visualization of operative field also contributes to lesser bleeding. Bernstein et al, reported that conventional endoscopic surgery with Blakesley forceps was more traumatic.³⁷

Intraoperative duration of surgery

The average duration of surgery was 55 minutes in microdebrider group, compared with 64 minutes in the standard group as reported by Singh R et al.⁶ In present study mean duration of surgery was 56.67 minutes in the microdebrider group and 75.70 minutes in the conventional group. The result is statistically evident with a $p\text{-value} < 0.001$. Magdy et al, reported a statistically significant result ($p < 0.05$) for a shorter operative time in the powered endoscopy group (microdebrider 83 ± 15 minutes) when compared to conventional instrument group (94 ± 18 minutes).⁷ Cornet ME et al, found a 37% longer operating time when operating without a microdebrider.⁸ Duration of surgery with microdebriders was shorter as compared to the conventional endoscopic sinus surgery as shorter time was needed for hemostasis due to continuous integrated suction and frequent change of instruments was not required. The same observation has been reported by Magdy et al.⁷

Postoperative complications

In this study, no major complications were seen in both the groups. No synechia, no cerebrospinal fluid leak and no orbital complications were seen in both groups. This could be due to careful imaging evaluation and surgical expertise. The minor complications, in this study includes minor intraoperative bleeding, nasal discharge, crusting and mild scarring in microdebrider group. In conventional group the minor complications included sensation of nasal obstruction at 3 months due to damage

to olfactory receptors with conventional surgery, till they regenerate, intraoperative blood loss, scarring and crusting. Both the groups had polyp recurrence, however no polyp recurrence was noted in microdebrider group at 6 months. Ephraim et al, reported 1.37% minor and 0.31% major complications in adults with Microdebrider™ (XOMED 2000, Medtronic, USA). They reported no complications in the paediatric age group.³⁹ In present study with 4.0 mm blade there were no mishaps. Bony dehiscence of anatomical structures is an exception to the safety of ocular and intracranial structures with the microdebriders. This tool should be reserved for highly experienced endoscopic skull base surgeons with great familiarity with this device and its numerous settings in order to prevent potential deleterious complications. In this study lower rate of orbital complications with microdebriders lies in that they are a safer alternative for lamina papyracea and skull base than punching and tearing conventional endoscopic sinus instruments because it only cut tissue which is capable of being aspirated unless much force is applied which cause entry into ocular structures or the intracranial cavity by direct penetration of bone.

Medicolegal aspects

In this study no major complications were reported and there were no medicolegal litigations with microdebrider.

Cost factors

The major advantages in utilizing the microdebrider as the primary instrument in endoscopic sinus surgery is the cost-effectiveness of the tool as multiple functions may be achieved with a single instrument. Bruggers et al, microdebriders carry the higher cost than conventional instruments including initial expenditure on system and ongoing expense of disposable blades.⁶ Dr. Pletcher, university of California concluded that cost issue is probably negligible, as he has encountered no difficulties with insurance coverage of the microdebrider as an instrument in association with other procedure costs. He says that the cost of the device itself is made up and possibly saved in time.⁴⁰ Utility of the microdebrider promotes improved precision and controlled, expeditious tissue removal thereby decreasing intraoperative time. In addition, it allows for shorter postoperative healing times and faster reepithelialization of the denuded surfaces because of increased mucosal preservation and a relative decrease in mucosal trauma when compared to conventional instrumentation.

CONCLUSIONS

Microdebriders are more effective as compared to conventional endoscopic sinus surgery due to lesser intraoperative bleeding (relatively bloodless) and duration of surgery, better postoperative endoscopic and symptom scores, combine cutting and suction in a single tool, enabling accurate and precise tissue removal

without damaging the surrounding mucosa, less scarring/synechiae, fewer complications.

Funding: No funding sources

Conflict of interest: None declared

Ethical approval: The study was approved by the Institutional Ethics Committee

REFERENCES

1. Hedman J, Kaprio J, Poussa T, Mieminem MM. Prevalence of asthma, aspirin intolerance, nasal polyposis and chronic obstructive pulmonary disease in a population-based study. *Int J Epidemiol.* 1999;28:717-22.
2. Sindwani R, Manz R. Technological innovations in tissue removal during rhinologic surgery. *Am J Rhino Allergy.* 2012;26(1):65-9.
3. Selivanova O, Kuehnemund M, Mann WJ, Amedee RG. Comparison of conventional instruments and mechanical debriders for surgery of patients with chronic sinusitis. *Am J Rhinol.* 2003;17(4):197-202.
4. Sauer M, Lemmens W, Vauterin T. Comparing the microdebrider and standard instruments in endoscopic sinus surgery: a double-blind randomized study. *B-ENT.* 2007;3:1-7.
5. Kursat C, Unal B, Zeynep K. Impact of microdebrider in surgical treatment of nasal polyposis in terms of health related quality of life and objective findings: a comparative randomized single blinded clinical study. *KKB Forum.* 2007;6(2):60-5.
6. Singh R, Hazarika P, Dipak R. A comparison of microdebrider assisted endoscopic sinus surgery and conventional endoscopic sinus surgery for nasal polypi. *Indian J Otolaryngol Head Neck Surg.* 2013;65(3):193-6.
7. Magdy ES, Sameh MR, Osama A, Albirmawy HS. Powered versus conventional endoscopic sinus surgery instruments in management of sinonasal polyposis. *European Arch Otorhinolaryngo.* 2013;270(1):149-55.
8. Cornet ME, Reinartz SM, Georgalas C, Spronsen E, Fokkens WJ. The microdebrider, a step forward or an expensive gadget? *Rhinology.* 2012;50(2):191-8.
9. Kakkar V, Sharma C, Singla P, Gulati A, Singh S, Malik P. To compare the results of endoscopic sinus surgery with and without microdebrider in patients of nasal polyposis. *Clin Rhinol An Int J.* 2014;7(2):61-3.
10. Lund V, Mackay I. Staging of rhinosinusitis. *Rhinology.* 1993;31:183-4.
11. Lund VJ, Kennedy DW. Quantification for staging sinusitis. International conference on sinus disease: terminology, staging, therapy. *Ann Otol Rhinol Laryngol.* 1995;104:17-21.
12. Lund VJ, Mackay IS. Staging in rhinosinusitis. *Rhinology.* 1993;107:183-4.
13. Banerji A, Piccirillo JF, Thawley SE. Chronic rhinosinusitis patients with polyp or polypoidal

- mucosa have a greater burden of illness. *Am J Rhinology.* 2007;21:19-26.
14. Fokkens WJ, Lund VJ, Mullol J. European position paper on rhinosinusitis and nasal polyps. *Rhinol Suppl.* 2012;(23):1-299.
 15. Badia L, Lund V. Topical corticosteroids in nasal polyposis. *Drugs.* 2001;61:573-8.
 16. Bruggers S, Sindwani R. Innovations in microdebrider technology and design. *Otolaryngol Clin N Am.* 2009;42:781-7.
 17. Kennedy DW. Technical innovations and the evolution of endoscopic sinus surgery. *Ann Otol Rhinol Laryngol Suppl.* 2006;196:3-12.
 18. Gunkel AR, Freysinger W, Martin A. Three-dimensional image-guided endonasal surgery with a microdebrider. *Laryngoscope.* 1997;107:834-8.
 19. Stammberger H. Functional endoscopic sinus surgery the messerklinger technique. *Eur Archives Oto Rhino Laryngology.* 1990;247(2):63-76.
 20. Bakari A, Afolabi OA, Adoga AA, Aliya M kodiya, Babagana M Ahamed. Clinicopathological profile of sinonasal masses: an experience in national ear care center Kaduna, Nigeria. *BMC Research Notes.* 2010;3:186-96.
 21. Larsen K, Tos M. The estimated incidence of symptomatic nasal polyps. *Acta Otolaryngol.* 2002;122(2):179-82.
 22. Drake LB, Lowe D, Swanston A, Grace A. Clinical profile and recurrence of nasal polyps. *J Laryngol Otol.* 1984;98(8):783-93.
 23. Moloney JR. Nasal polyps, nasal polypectomy, asthma, and aspirin sensitivity. Their association in 445 cases of nasal polyps. *J Laryngol Otol* 1977;91(10):837-46.
 24. Larsen K, Tos M. Clinical course of patients with primary nasal polyps. *Acta Otolaryngol.* 1994;114(5):556-9.
 25. Settupane G. Epidemiology of nasal polyps. In: Settupane G, Lund VJ, Bernstein JM, Tos M. *Nasal, eds. polyps: epidemiology, pathogenesis and treatment.* Rhode Island: Oceanside Publications; 1997: 17-24.
 26. Settupane GA, Chafee FH. Nasal polyps in asthma and rhinitis. A review of 6037 patients. *J Allergy Clin Immunol.* 1977;59:17-21.
 27. McFadden EA, Kany RJ, Fink JN, Toohill RJ. Surgery for sinusitis and aspirin triad. *Laryngoscope.* 1990;100:1043-6.
 28. Hu Y, Cao PP, Liang GT, Cui YH, Liu Z. Diagnostic significance of blood eosinophil count in eosinophilic chronic rhinosinusitis with nasal polyps in Chinese adults. *Laryngoscope.* 2012;122(3):498-503.
 29. Kuladeepa AV, Pai S, Nagaraj TS, Sukesh. Study on utility of nasal smear examination in diagnosing allergic rhinitis and its histopathological correlation in allergic nasal polyps. *Int J Basic App Med Sci.* 2015;5(1):2103-227.
 30. H Gheriani, A Curran, Conrad Timon. Endoscopic sinus surgery outcome in patients with symptomatic chronic rhinosinusitis and minimal changes on computerised tomography. *Ir Med J.* 2006;99(1):15-6.
 31. Sharp HR, Rowe JJM, Mackay IS. The outcome of endoscopic sinus surgery: correlation with computerised tomography score and systemic disease. *Clinical Otolaryngology.* 1999;24:39-42.
 32. Metson RB, Glicklich RE. Clinical outcomes in patients with chronic sinusitis. *Laryngoscope.* 2000;110(94):24-8.
 33. Rice DH. Endoscopic sinus surgery: results at 2 year follow-up. *Otolaryngol Head Neck Surg.* 1989;101:476-9.
 34. Dufour X, Bedier A, Ferrie JC, Gohler C, Klossek JM. Diffuse nasal polyposis and endonasal endoscopic surgery: long-term results, a 65-case study. *Laryngoscope.* 2004;114(11):1982-7.
 35. Poetker DM, Mendolia LS, Smith TL. Outcomes of endoscopic sinus surgery for chronic rhinosinusitis associated with sinonasal polyposis. *Am J Rhinol.* 2007;21(1):84-8.
 36. Meloni F, Stomeo F, Teatini GP. Post-operative recurrence of naso-sinus polyposis. *Acta Otorhinolaryngol Ital.* 1990;10:173-9.
 37. Bernstein JM, Lebowitz RA, Jacobs JB. Initial report on post operative healing after endoscopic sinus surgery with the microdebrider. *Otolaryngol Head Neck Surg.* 1998;118(6):800-3.
 38. Krouse JH, Christmas DA Jr. Powered nasal polypectomy in the office setting. *Ear Nose Throat J.* 1996;75(9):608-10.
 39. Ephraim E, Koby P, Haim G, Daniel K. Complications following powered endoscopic sinus surgery: an 11 year study of 1190 patients in a single institute in Israel. *Isr Med Assoc J.* 2014;16(6):338-40.
 40. Microdebriders offer new surgical options. Available at <http://www.enttoday.org/article/microdebriders-offer-new-surgical-options/>. Accessed at 20 March 2016.

Cite this article as: Ghera B, Chopra H, Munjal M. Comparative study of conventional versus microdebrider assisted endoscopic sinus surgery in sinonasal polyposis. *Int J Otorhinolaryngol Head Neck Surg* 2016;2:197-204.