

Original Research Article

DOI: <http://dx.doi.org/10.18203/issn.2454-5929.ijohns20190986>

Comprehensive study of salivary gland neoplasms: single department study in a tertiary care centre

S. Muthuchitra*, V. Saravanaselvan, R. Malarvizhi

Department of Otorhinolaryngology and Head and Neck Surgery, Govt. Stanley Medical College, Chennai, Tamil Nadu, India

Received: 12 February 2019

Revised: 28 February 2019

Accepted: 01 March 2019

***Correspondence:**

Dr. S. Muthuchitra,
E-mail: muthudr@live.in

Copyright: © the author(s), publisher and licensee Medip Academy. This is an open-access article distributed under the terms of the Creative Commons Attribution Non-Commercial License, which permits unrestricted non-commercial use, distribution, and reproduction in any medium, provided the original work is properly cited.

ABSTRACT

Background: Pathologies of salivary glands are common in the general population. Of them few are neoplasms-benign or malignant. The presentation of salivary gland pathologies are both to general surgeons and otorhinolaryngologists of the same hospital. The presentation to concerned treating surgeon is based on the symptoms during presentation. This study aims at the various types of salivary gland pathologies requiring surgical intervention and the rate of recurrence following surgery in a single department.

Methods: Retrospective study was conducted. Study period was from May 2017 to February 2019. All salivary gland neoplasms were studied for presentation and recurrence following surgery.

Results: Intraoperative difficulties and post-operative complications more common in malignant tumors. Female gender is more commonly affected by benign neoplasms. There is no gender predilection in malignant neoplasms. Facial nerve is most common nerve to get affected in pre-operative and during surgery as well.

Conclusions: Neoplasms of salivary glands are common in females though it has equal incidence in malignancy. Facial nerve is most commonly affected as complication in malignant neoplasms.

Keywords: Parotid, Submandibular gland, Malignant salivary, Benign salivary gland

INTRODUCTION

Salivary glands of primary concern are the parotid and submandibular glands due to their commonly affected nature and earlier presentation. The symptoms that they present with are swelling, pain and nerve palsies in the vicinity or over the gland.¹ Our tertiary care centre with both general surgeons and otolaryngologist has seen cases of salivary gland neoplasms over years with surgical intervention being done by both. We aim to study the demographic data and nature of the neoplasms that present to our otorhinolaryngology department over the recent past.

Anatomy

Major salivary glands are 3 pairs and minor salivary glands are about 600-1000. All of which originate from the diverticula originating from buccal epithelium-mesenchyme.

The parotid is largest of them, 1 on each side, situated anterior and inferior to ear. They are bilobed. Capsule of parotid is from the investing layer of deep cervical fascia. Its secretions are predominantly serous and drain via stenson's duct which opens just opposite to upper 2nd molar tooth. The gland has a forward extension between zygomatic arch and parotid duct—the accessory parotid. The facial nerve and facial artery lie between two

divisions of parotid—superficial and deep parts of the gland, along with the venous network of maxillary vein and superficial temporal veins to form retromandibular vein. Innervation is parasympathetic by glossopharyngeal nerve that synapses on the otic ganglion. Post ganglionic nerve fibres are secretomotor by the greater auricular and auriculo-temporal nerves; sympathetic innervation by superior cervical ganglion from external carotid artery.²

The submandibular gland one on each side is horizontally oriented with superficial and deep lobes separated by mylohyoid muscle. The gland occupies the submandibular space and secretions are viscous. Branches from the facial artery supply the gland with venous drainage as with parotid glands. Draining duct-Wharton's duct opens on either side of frenulum in the floor of mouth. Preganglionic secretomotor fibres from trigeminal nerve and post ganglionic fibres from auriculo-temporal branch of mandibular nerve. Sympathetic plexus from external carotid artery.

Sublingual salivary glands lie between mandible and genioglossus and drain along with submandibular gland.

Facial nerve is the most important structure encountered in pathologies of salivary glands because of its propensity to get affected in due to compression as in benign tumors or infiltrated as in malignant tumors. Some of the landmarks for facial nerve in relation to salivary glands are;

- Segment of facial nerve between stylomastoid foramen and parotid-to be searched for near the tympanomastoid sulcus.
- Mandibular branch of facial nerve emerges immediately anterior to retromandibular vein.
- Tragal pointer.
- Just inferior to posterior belly of digastric muscle which forms the posterior boundary of submandibular space.

Disorders of salivary glands

Salivary gland disorders commonly seen can be grouped into inflammatory, traumatic, neoplasms-benign and malignant. Congenital conditions such as aplasia, hypoplasia and fistulas are very rare and hence not included in this discussion.

Of the benign conditions sialadenitis—simple inflammation of gland is very commonly encountered. It involves simple inflammation of the salivary gland, very commonly the parotids, as a result of viral infections such as mumps and adenoviral infection. They resolve with supportive care. Other than cosmetic complaints no specific clinical findings could be elicited.

Sialolithiasis the next common benign pathology commonly affects the submandibular salivary glands due to the nature of their secretions and draining duct being

more in anti-gravity direction. They involve the proximal distension of duct and gland en masse due to inadequate or absent drainage of secretions which on chronicity lead to atrophy of gland. In initial period, clinical features include pain on bolus formation and swelling of the gland. Attacks of pain subside with completion of meals. Treatment includes removal of calculi and if gland is affected excision of gland as well.^{3,4}

In benign tumors of salivary glands most common is pleomorphic adenoma followed by adenolymphoma, lymphangioma, hemangioma, benign cyst, lipoma and neurofibroma. Clinical features are enlargement of gland. Facial nerve is rarely affected. In adenoid cystic carcinoma, nerve infiltration is very common due to neurotropic nature of tumor. Cosmetic complaints and very rarely pain warrant surgical intervention.

In malignant tumors of salivary glands mucoepidermoid carcinoma, adenoid cystic lymphoma, adenocarcinoma, malignant mixed tumor, squamous cell carcinoma, and lymphoma are encountered pathologies. Most tumors present with enlargement of gland with chronic pain and facial nerve palsies. Surgical intervention is as per gland involved and the staging of tumor.^{5,6}

METHODS

Design: Retrospective.

Study place: Department of Otorhinolaryngology and Head and Neck Surgery, Govt. Stanley Medical College.

Study period: May 2017 to February 2019.

Inclusion criteria

(1) Above 18 years and below 90 years of age; (2) both gender; (3) no evidence of autoimmune disorder; (4) no history of previous pathologies suggestive of neoplasm in the past; (5) no history of focal sepsis; (6) no history prior treatment of malignancy to head and neck.

Exclusion criteria

(1) Below 18 years and above 90 years of age; (2) autoimmune disorder; (3) history prior surgeries in salivary gland.

Methodology

Superficial parotidectomy, total parotidectomy and excision of submandibular salivary gland were the surgical procedures done on the patients. A retrospective medical review was done in academic tertiary care centre of patients presenting with salivary gland tumors who underwent surgical intervention between May 2017 to February 2019. Demographic data, presenting complaints, cytological studies, radiological findings, surgical procedures and outcomes were studied. Patients

were reviewed for recurrence during follow up. The first post-operative visit was at 2nd week and subsequently reviewed monthly for 3 months followed by annual review.

Superficial parotidectomy

Under general anaesthesia, supine with mild head end elevation to diminish passive congestion, head turned to opposite side. Modified Blair's incision is made and flaps raised 'fat up' and 'fat down'. Dissection is carried with preservation of greater auricular nerve and distal branches of facial nerve, with anterior flap consisting of skin, subcutaneous tissue and possibly platysma inferiorly. Sulcus seen between parotid and sternomastoid is deepened to expose posterior belly of digastric to trace the facial nerve to avoid damaging it. Main trunk of facial nerve is identified and external auditory meatus with its sulcus is traced. The latter serves as a landmark in identification of facial nerve. The superficial lobe is freed from its upper border by separating it from the soft tissues overlying the zygomatic arch. The buccal branches are traced and pedicle of parotid gland is severed. Haemostasis is achieved and drain is kept and wound closed in layers. Care to be taken at the s junction of the incision during approximation where an acute angle and tightened sutures can cause necrosis at the T junction.⁷

Total parotidectomy

After superficial lobe is excised as described above, the deep lobe is separated with scissors from posterior border of mandibular ramus-ascending portion and from the temporomandibular joint. The deep lobe is separated long with dividing of dense fibrous tissue around the styloid process. The retromandibular vein may be divided at its upper and lower ends. The artery is divided at the lower part of the gland. Closure is as with the superficial parotidectomy. Facial nerve is preserved as much as possible by dissection above and below the Patey's plane.

Gustatory sweating is a rare complication of the above mentioned surgery wherein sweating occurs in the preauricular region during meals due to interruption of parasympathetic fibres which regenerate in a misdirected fashion to innervate the sweat glands in the skin overlying the nerve. This condition is also called as Frey's syndrome and auriculotemporal syndrome. Other complications are facial nerve weakness, hematoma, salivary fistula and facial contour deficit.

Submandibular gland excision

Under general anaesthesia, with supine, head turned to opposite side, mildly extended and head end slightly elevated, horizontal skin crease incision is made 4 cm below mandibular margin. Platysma is exposed along the length of incision and flaps elevated superiorly and inferiorly.

The exposure inferiorly is up to the posterior belly of digastric from posterior-anterior direction. Care to be taken to preserve the marginal mandibular nerve at this point. Three ways of which are (1) identify the tail of parotid where it lies anterior to retromandibular vein and trace it forwards; (2) making sure to dissect in a plane deeper to the nerve, which can be done by dissecting the gland at the hyoid level and keeping dissection as close to the fascia of gland; (3) dividing the facial vessels below mandible and lifting the upper ligated stumps so as to retract the main trunk away from dissection plan.⁸

Lower border of gland is grasped by forceps and lifted up to reveal the digastric and hyoglossus muscle. Further traction of gland done anteriorly to view facial artery which is divided proximal to gland to free gland posteriorly. The gland is then freed of superior attachments. Blunt dissection carried deep to posterior free border of mylohyoid muscle and retracted to expose deep part of gland. Care to be taken to avoid injury to lingual nerve. Traction done downwards and duct distally ligated and gland removed. Haemostasis achieved and drain kept. Wound closed in layers.

Complications are marginal mandibular nerve palsy, hypoglossal nerve injury, hematoma and damage to lingual nerve.

Invariably drains are removed in 48 hours. Adequate antibiotic coverage in post-operative period is essential.

Statistical method

The collected data were analysed with IBM. SPSS statistics software 23.0 Version. To describe about the data descriptive statistics frequency analysis, percentage analysis were used for categorical variables and the mean and S.D were used for continuous variables. To find the significant difference between the bivariate samples in paired groups the paired sample t-test was used. In the above statistical tool the probability value 0.05 is considered as significant level.

RESULTS

In the present study 11 patients were studied. Of them 54% were in the age group 30-40 years and 18% were in the age group 41-50 years. 9% were there in each of the 51-60, 61-70 and 71-80 years age groups.

Table1: Age distribution.

Age (in years)	No. of patients	Percentage
30-40	6	54
41-50	2	18
51-60	1	9
61-70	1	9
71-80	1	9

The female gender was most commonly found to be affected with 63% among study affected. Among the affected 63% only 14 were malignant.

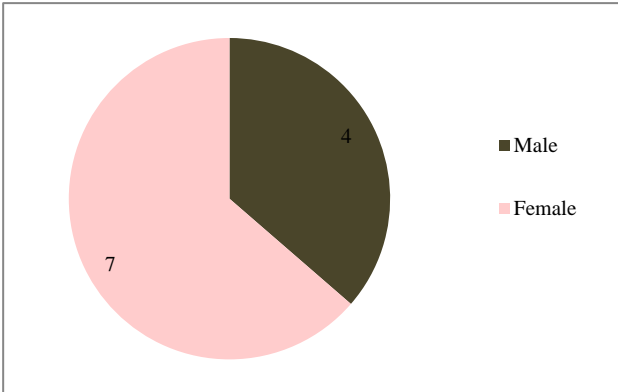


Figure 1: Sex predilection.

Benign tumors were found to be more in female. Malignant tumors were equally found in both genders.

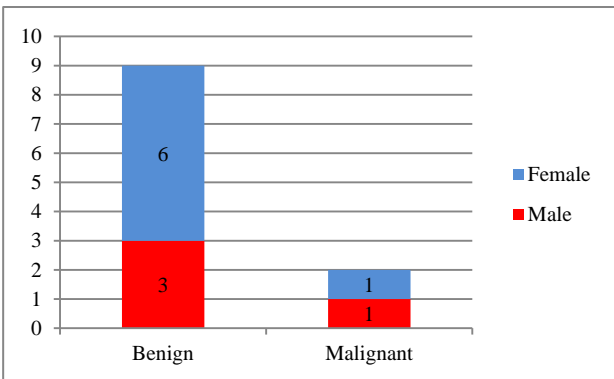


Figure 2: Sex predilection-nature of tumour.

In this study 33% of benign tumours were found to be in male with predominance of 67% in female. In malignant tumours the study showed equal incidence.

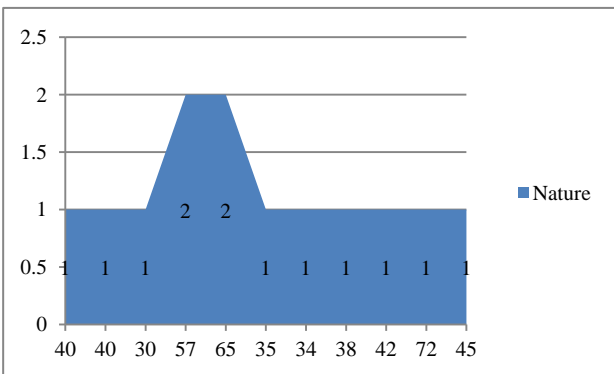


Figure 3: Nature of tumour.

X-axis-age of patient in years; Y-axis 1-benign and 2-Malignant.

Presenting symptoms were very commonly swelling which was present in all study subjects (100%) followed by pain in 18% and facial nerve palsy in 9%.

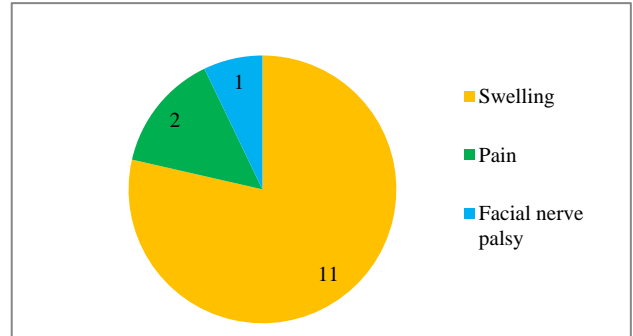


Figure 4: Presenting symptoms.

In 72% parotid was the affected gland whereas only 28% affected the submandibular gland.

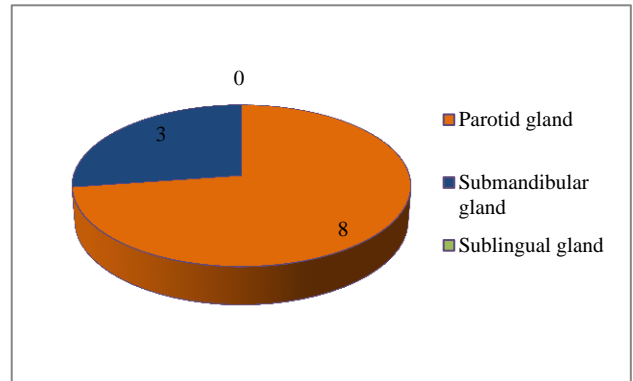


Figure 5: Gland affected.

All 4 of the submandibular gland neoplasms were benign. Only 33% of parotid affected were malignant.

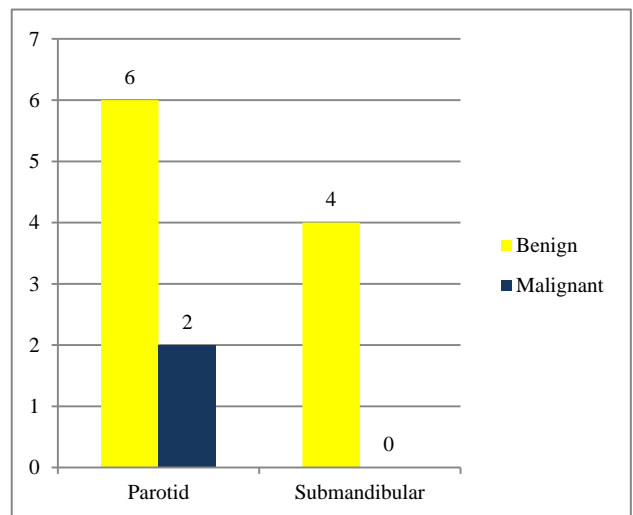


Figure 6: Type of tumor in gland affected.

Facial nerve was affected in preoperative period in only 9% of cases.

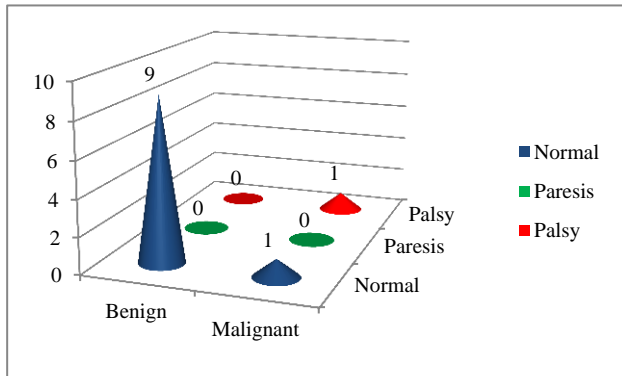


Figure 7: Pre-operative facial nerve status.

11% of benign tumors had paresis of nerve in post-operative period. But both the malignant cases had facial palsy in post-operative period.

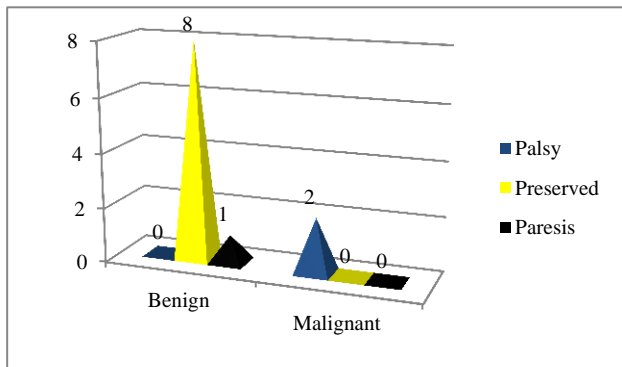


Figure 8: Nerve affected in post-operative period in relation to nature of tumour.

63% underwent superficial parotidectomy, 27% submandibular excision and 9% total parotidectomy.

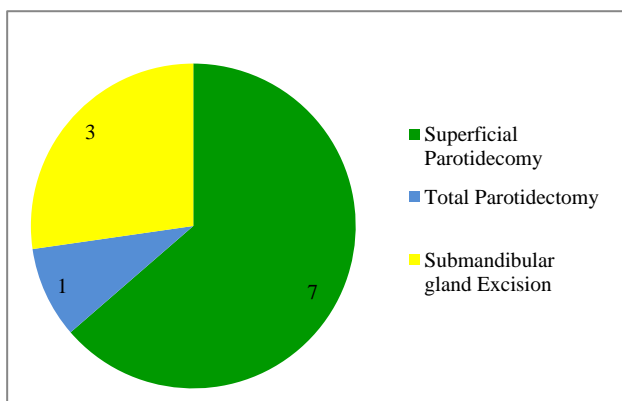


Figure 9: Type of surgery done.

Recurrence over the study period was for benign tumours is nil. In cases of malignancy the adequate follow period is still under study and hence lacks valuable data.

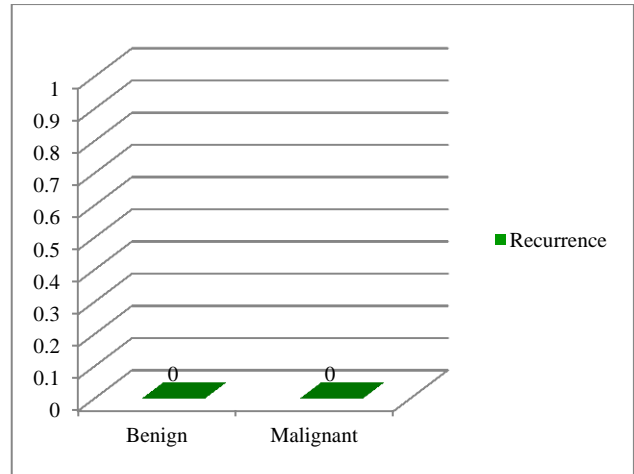


Figure 10: Recurrence (needs further follow up for malignant tumours).

DISCUSSION

In the study 11 patients were identified with age ranged from 30 years to 65 years. Of them 4 were male and 7 were female. Common presenting feature was swelling in the region of salivary glands in all patients. Only 2 patients had pain associated with swelling especially with rate of increase in swelling. All patients underwent preoperative Ultra sonogram and Computer tomogram for radiological investigations and Fine needle cytology aspiration study for histopathological work up.

Shrestha et al, retrospective study of 176 cases has shown a mean of presentation at 44.76 years of age; with a male female ratio of 1.7:1. They have shown that common gland to be affected is parotid with 70% of their study population and 19.3% in submandibular gland. They have shown a result of pleomorphic adenoma being the most common salivary gland pathology.⁹

In the current study surgical approach was superficial parotidectomy for the 7 parotid cases and total parotidectomy for 1 case. Submandibular gland excision was done for the 3 cases. In the post-operative period 2 parotid cases which had difficulty in dissection of plane, had facial nerve palsy-one in immediate post-operative period and the other had progression 1 month later. One submandibular gland case had immediate post-operative marginal mandibular palsy which recovered over the follow period at 6th month.

In the preoperative period 1 of the FNAC among 11 was inconclusive which turned out to be malignant. Of the remaining 10, 9 were benign and 1 was malignant.

The mean age of presentation of tumor was 45.27 years with standard deviation of 12.8 years and range of 30 to 72 years. The tumor was more common in the 4th and 5th decade. Benign tumors are more common being 81%. Salivary gland tumors are more common in the female-

63.6% being affected in females. Malignant tumors are more common in 6th decade. Pleomorphic adenoma is the most common histopathology among benign tumors accounting for 72.7% of benign neoplasms and mucoepidermoid carcinoma among malignant tumors. Most common salivary gland affected in both benign and malignant cases was parotid gland. Benign cases were more common in female. In malignancy cases there was no sex predilection observed.

The common presentation irrespective of gland affected is swelling in the region of the gland involved which was seen in all 11 subjects. Pain was seen in 2 cases, both of which turned to be malignant. Facial nerve palsy was seen as symptom in one malignant case but only the upper zygomatic branches were involved. The case in further study during post-operative period was non-progressive facial palsy for 1 month post-operatively and later on in follow up had progressive palsy, last seen with grade of House-Brackmann grade 4/5.

In a study conducted by Potdar et al, 403 cases over 27 years in a referral centre shows a pleomorphic adenoma to be more common about 46%. They have also shown that parotid is most commonly affected with 53% incidence. Their study has shown that aggressive treatment of benign tumors over last few years has brought down the recurrence rates.¹⁰

In current study recurrence rate for the benign tumours over 2 year study period was nil. Malignant tumours lack the adequate prescribed follow up period to declare nil recurrence; hence limitations on that category exist to study further.

CONCLUSION

FNAC of salivary gland tumors are not conclusive. Excision biopsy is the definitive mode of pathological investigation. Ultra sonograms and computer tomogram studies aid in study of the extent and surgical planning of tumor. Salivary gland disorders though common, neoplasms are restricted to older age group with increasing incidence as age increases. Limitations of the study are single department study with limited sample size to define sex predilection among benign and malignant tumors.^{11,12}

Funding: No funding sources

Conflict of interest: None declared

Ethical approval: The study was approved by the Institutional Ethics Committee

REFERENCES

1. Holsinger FC, Bui DT. Anatomy, Function and Evaluation of salivary glands. Salivary Gland Disorders. 2007;13.
2. To VSH, Chan JYW, Tsang RKY, Wei WI. Review of salivary gland neoplasms. ISRN Otolaryngol. 2012;2012.
3. Homer J, Robson A. Benign salivary gland tumours. Scott-Brown's Otorhinolaryngology Head and Neck Surgery. Vol 3. 8th edition. In: Watkinson JC, editor. 2018: 115-130.
4. Saade RE. Benign Neoplasms of the salivary glands. Cummings Otolaryngology- Head and Surgery. 6th edition. In: Flint PW, editor. 2015: 1238-1257.
5. Poorten VV, Bradley PJ. Malignant tumours of the salivary glands. Scott-Brown's Otorhinolaryngology Head and Neck Surgery. Vol 3. Edi 8. In: Watkinson JC, editor. 2018: 131-156.
6. Sunwoo JB. Malignant Neoplasms of the salivary glands. Cummings Otolaryngology- Head and Surgery. 6th edition. In: Flint PW, editor. 2015: 1258-1280.
7. Shaheen OH. Partial and complete parotidectomy. Rob and Smith's Operative Surgery. 4th edition. In: Ballantyne JC, editor. 1992: 409-419.
8. Shaheen OH. Removal of submandibular salivary gland. Rob & Smith's Operative Surgery. 4th edition. In: Ballantyne JC, editor. 1992: 425-431.
9. Shrestha S, Pandey G, Pun CB, Bhatta R, Shahi R. Histopathological pattern of salivary gland tumors. J Pathol Nepal. 2014;4:520-4.
10. Potdar GG, Paymaster JC. Tumors of the salivary glands. Am J Surg. 1996;118(3):440-7.
11. Hoffman H. Evaluation and surgical treatment of tumors of salivary glands. Comprehensive management of head and neck tumors. Volume 2, 2nd edition. In: Stanley E, Thawley, editors. 1996: 1147-1181.
12. Sood S, McGurk M, Vaz F. Management of salivary gland tumors: United Kingdom National Multidisciplinary Guidelines. J Laryngol Otol. 2016;130(2):142-9.

Cite this article as: Muthuchitra S, Saravanaselvan V, Malarvizhi R. Comprehensive study of salivary gland neoplasms: single department study in a tertiary care centre. Int J Otorhinolaryngol Head Neck Surg 2019;5:581-6.