

Case Report

Transnasal endoscopic removal of intra-orbital metallic foreign body

Neeraj Ratnakar Shetty*, Megha Mukund Panjiyar

Department of Otorhinolaryngology, HBT medical College and R. N. Cooper hospital, Mumbai, India

Received: 27 January 2019

Revised: 11 February 2019

Accepted: 12 February 2019

*Correspondence:

Dr. Neeraj Ratnakar Shetty,

E-mail: drneeraj1988@gmail.com

Copyright: © the author(s), publisher and licensee Medip Academy. This is an open-access article distributed under the terms of the Creative Commons Attribution Non-Commercial License, which permits unrestricted non-commercial use, distribution, and reproduction in any medium, provided the original work is properly cited.

ABSTRACT

Nasal endoscopic surgeries are a highly rewarding subgroup of otorhinolaryngological procedures. Endoscopic sinus surgeries are commonly performed and endoscopic orbital and optic nerve decompressions are performed routinely in specialized centres. We would like to present a case of endoscopic transnasal removal of intra orbital foreign body which was in situ for 2 months with the aid of a C-arm for on table imaging.

Keywords: Transnasal endoscopy, Metallic foreign body removal, intra orbital, Intra conal and extra conal

INTRODUCTION

Intraorbital foreign bodies are usually a result of high velocity injuries, and efforts to retrieve them are technically challenging due to their deep location within the orbit.¹ Intraconal foreign bodies are especially difficult to remove considering the confined space within the muscle cone and the close proximity to the optic nerve that increases the risk of intraoperative optic nerve injury.² Minimally invasive endoscopic surgery has the advantage of gaining access transnasally into the medial intraconal space with minimal surrounding tissue damage and with no unsightly external scars.²

CASE REPORT

19 year old male patient with complaints of diplopia on looking to the right was referred to ENT department after a CT scan by the ophthalmology department in view of a foreign body in the orbit in the medial part behind the globe. History revealed trauma two months back near the eye inferior to the medial canthus due to a nail gun with a splinter of the metal entering the tissue but the splinter was not found on immediate exploration and wound was sutured and it healed with minimum scarring. On examination vision in both eyes was 6/6 and fundoscopy

was normal with only restriction of the left eye on moving eyes to the right. CT scan revealed a 1.5×0.5 cm metal splinter in the middle one third of the orbit with both intra conal and extra conal components and embedded in the medial rectus muscle.

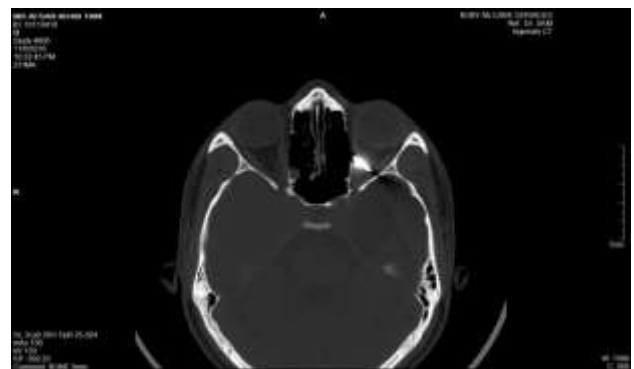


Figure 1: Axial cut showing intra orbital foreign body.

Management

Intra nasal endoscopic approach was employed and after exposure of the lamina papyracea, the bone was removed and orbit was entered. Medial rectus was exposed,

delineated and the foreign body was palpated with a ball point probe. The metallic foreign body was definitely located under c-arm guidance and the medial rectus muscle was gently dissected and the foreign body visualized. It was then gently grasped with straight Blakesley forceps and delivered out. The prolapsed orbital fat was kept to a minimum and further supported with gel foam and the nasal cavity was packed. Post op vision was checked and was normal as the pre-op condition.

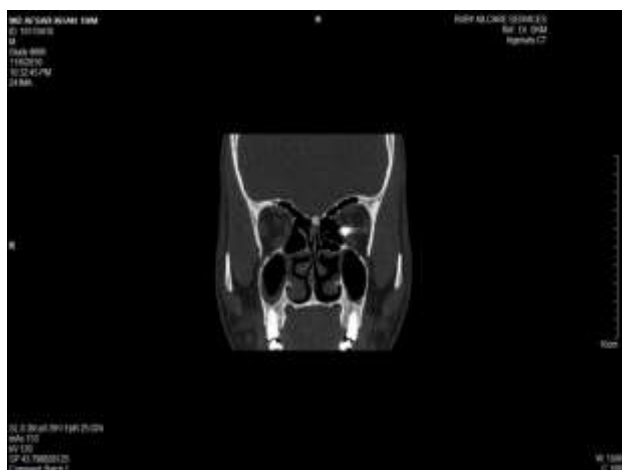

Figure 2: Coronal cut showing the intra orbital foreign body.

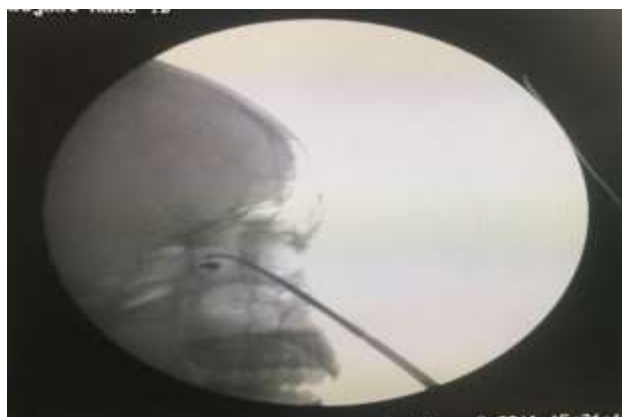

Figure 3: C-arm image–ball point pointing towards foreign body.

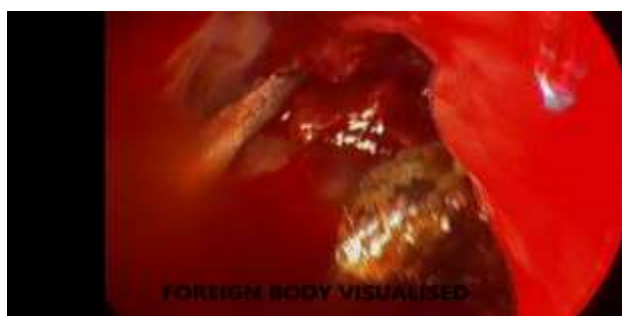

Figure 4: Intra-operative foreign body exposure.

DISCUSSION

Foreign bodies in the intraconal space pose an even more difficult challenge when they are small, making localization extremely difficult. Lesions in the intraconal space are associated with the highest rate of surgical complications in orbital surgeries.³ Approaches that have been described to gain surgical access to the medial intraconal space include transcranial, transconjunctival, transmaxillary and eyelid approaches.⁴⁻¹² Due to the invasiveness of these approaches, transnasal endoscopic surgery is becoming increasingly popular as a safe surgical technique to access the medial intraconal space.^{13,14} Successful removal of orbital foreign bodies using endoscopic surgery has been reported by several authors.¹⁵⁻¹⁷ Although endoscopic transnasal surgery provides a minimally invasive approach to remove foreign bodies in the intraconal space, the risk of inadvertent optic nerve injury still exists.

CONCLUSION

Small intraconal foreign bodies are especially difficult to visualize through the endoscope. Use of pre-operative CT scan and intra operative use of the C-arm or navigation technology for localization and retrieval of intra conal metallic foreign bodies is a superior procedure for medially lodged foreign bodies. This provides quick and effective visualization of foreign bodies and also helps in removal of foreign body with reduced risk of inadvertent injury to optic nerve.

Funding: No funding sources

Conflict of interest: None declared

Ethical approval: Not required

REFERENCES

1. Al-Mujaini A, Al-Senawi R, Ganesh A, Al-Zuhaibi S, Al-Dhuhli H. Intraorbital Foreign Body: Clinical Presentation, Radiological Appearance and Management. *Sultan Qaboos Univ Med J.* 2008;8(1):69-74.
2. Teh D, Mohamad NF, Lim E, Zulkiflee AB, Narayanan P, Kamalden TA. Endoscopic transnasal removal of an intraconal foreign body using an image-guided surgical system. *Computer Assisted Surg.* 2016;21(1):25-8.
3. Purgason PA, Hornblass A. Complications of surgery for orbital tumors. *Ophthal Plast Reconstr Surg.* 1992;8:88-93.
4. Abuzayed B, Kucukyuruk B, Tanriover N, Sanus GZ, Canbaz B, Akar Z, et al. Transcranial superior orbitotomy for the treatment of intraorbital intraconal tumors: surgical technique and long-term results in single institute. *Neurosurg Rev.* 2012;35:573-82.
5. Iwata A, Matsumoto T, Mase M, Yamada K. Chronic, traumatic intraconal hematic cyst of the

- orbit removed through the fronto-orbital approach—case report. *Neurol Med Chir.* 2000;40:106–9.
6. Maus M, Goldman HW. Removal of orbital apex hemangioma using new transorbital craniotomy through suprabrow approach. *Ophthal Plast Reconstr Surg.* 1999;15:166–70.
 7. Pillai P, Lubow M, Ortega A, Ammirati M. Endoscopic transconjunctival surgical approach to the optic nerve and medial intraconal space: a cadaver study. *Neurosurgery.* 2008;63:204–8.
 8. Kiratli H, Bulur B, Bilgic S. Transconjunctival approach for retrobulbar intraconal orbital cavernous hemangiomas. *Orbital surgeon's perspective. Surg Neurol.* 2005;64:71–4.
 9. Schultheiß S, Petridis AK, Harbony RE. The transmaxillary endoscopic approach to the orbit. *Acta Neurochir (Wien).* 2013;155:87–97.
 10. Lyson T, Sieskiewicz A, Rogowski M, Mariak Z. The transmaxillary endoscopic approach to the inferior part of the orbit: how I do it. *Acta Neurochir (Wien).* 2015;157:625–8.
 11. Pelton RW. The anterior eyelid crease approach to the orbit. *Curr Opin Ophthalmol.* 2009;20:401–5.
 12. Pelton RW, Patel BC. Superomedial lid crease approach to the medial intraconal space: a new technique for access to the optic nerve and central space. *Ophthal Plast Reconstr Surg.* 2001;17:241–53.
 13. McKinney KA, Snyderman CH, Carrau RL, Germanwala AV, Prevedello DM, Stefko ST, et al. Seeing the light: endoscopic endonasal intraconal orbital tumor surgery. *Otolaryngol Head Neck Surg.* 2010;143:699–701.
 14. Tomazic PV, Stammberger H, Habermann W. Intraoperative medialization of medial rectus muscle as a new endoscopic technique for approaching intraconal lesions. *Am J Rhinol Allergy.* 2011;25:363–7.
 15. Feichtinger M, Zemmann W, Karcher H. Removal of a pellet from the left orbital cavity by image-guided endoscopic navigation. *Int J Oral Maxillofac Surg.* 2007;36:358–61.
 16. Khan-Lim D, Ellis J, Saleh H, Ram B. Endoscopic transnasal removal of orbital foreign body. *Eye.* 1999;13(5):667–8.
 17. Ng NKFK, Jaberoo MC, Pulido M. Image guidance removal of a foreign body in the orbital apex. *Orbit.* 2009;28:404–7.

Cite this article as: Shetty NR, Panjiyar MM. Transnasal endoscopic removal of intra-orbital metallic foreign body. *Int J Otorhinolaryngol Head Neck Surg* 2019;5:490-2.