

Case Report

A rare case report of pyogenic granuloma of nasopharynx

Kholood S. Assiri*, Mohammad S. Al-Ahmari

Department of ORL-HNS, Khamis Mushayt General Hospital, Khamis Mushayt, Kingdom of Saudi Arabia

Received: 03 February 2019

Revised: 18 March 2019

Accepted: 04 April 2019

***Correspondence:**

Dr. Kholood S. Assiri,

E-mail: dr.kholood1@hotmail.com

Copyright: © the author(s), publisher and licensee Medip Academy. This is an open-access article distributed under the terms of the Creative Commons Attribution Non-Commercial License, which permits unrestricted non-commercial use, distribution, and reproduction in any medium, provided the original work is properly cited.

ABSTRACT

The etiology of pyogenic granuloma (PG) is unclear; it is a reactive tumor-like lesion arising by various stimuli. This study aims to report a rare case of PG of the nasopharynx in a 47 years old Saudi female patient. On October 15th, 2018, a 47-years old Saudi female presented with nasal obstruction for one month. The patient's complaint was associated with on/off epistaxis, headache and allergic symptoms. On examination, she had pedunculated nasopharyngeal lesion. Radiological studies revealed a right nasal cavity mass, a lesion in the nasopharynx without extension to the adjacent structures. Removal of the lesion by nasoscope and cauterization of the base were done. Histopathology revealed vascularized granulation tissue with ulcerated epithelium and fibrinous exudates. Nasopharyngeal pyogenic granuloma is rare. It is one of the differential diagnosis of nasal bleeding.

Keywords: Pyogenic granuloma, Epistaxis, Nasopharynx

INTRODUCTION

The first case of pyogenic granuloma (PG) occurring in human was described and called as "Botryomycosis hominis".¹ PG was since then called in a number of names such as granuloma pediculatum benignum, benign vascular tumor, pregnancy tumor, vascular epulis and Crocker and Hartzell's disease. In 1904, Hartzell prescribes the term "pyogenic granuloma".^{1,2}

PG presents as a solitary, red or purple smooth, glistening papule that grows rapidly within days or weeks, and occurs frequently on the lips, gingiva, and fingers.³ Bleeding and ulceration are common complications.

The etiology of PG is unclear; it is considered a reactive tumor-like lesion arising by various stimuli, such as chronic low-grade irritation, traumatic injury, hormone effect, or drug-induced reaction.^{4,5}

Pyogenic granuloma (PG) may occur in all age groups, it is more happen in young females in the second decade of

life that due to the hormonal changes during period.⁶ Because increasing levels of estrogen and progesterone, the lesions increased during pregnancy.⁷

This article reports the case of a 47 years old female patient with pyogenic granuloma, which was surgically managed. However, to our knowledge, there is no report of a PG arising from nasopharynx to date.

CASE REPORT

On October 15th, 2018, a 47-year old female, a known case bronchial asthma and hypothyroidism, controlled on medication presented to the Otolaryngology-Head and Neck Surgery (ORL-HNS) Clinic of Khamis Mushait General Hospital, complaining of nasal obstruction for one month.

Khamis Mushait General Hospital is a tertiary care hospital in Khamis Mushait City, Aseer Region, Southwestern area of the Kingdom of Saudi Arabia.

The patient's complaint was associated with an “on/off” nasal bleeding, headache, and allergic symptoms. Symptoms were progressive with no aggravating or relieving factors. She had no history of visual loss, or diplopia.

Six months ago, the patient underwent removal of nasopharyngeal cystic lesion with histopathological findings that showed pseudo-stratified with a normal looking epithelial layer with a subepithelial stroma with lymphoid infiltrate.

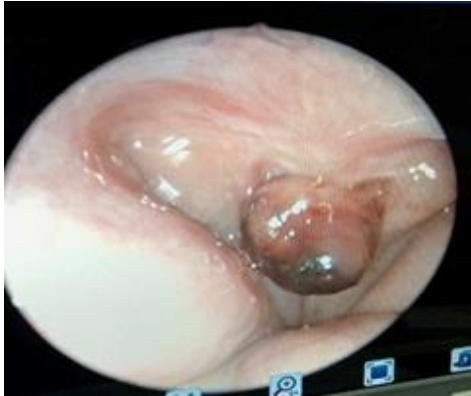

Figure 1: Pedunculated nasopharyngeal lesion 0.5x0.5 cm, smooth, ulcerated.

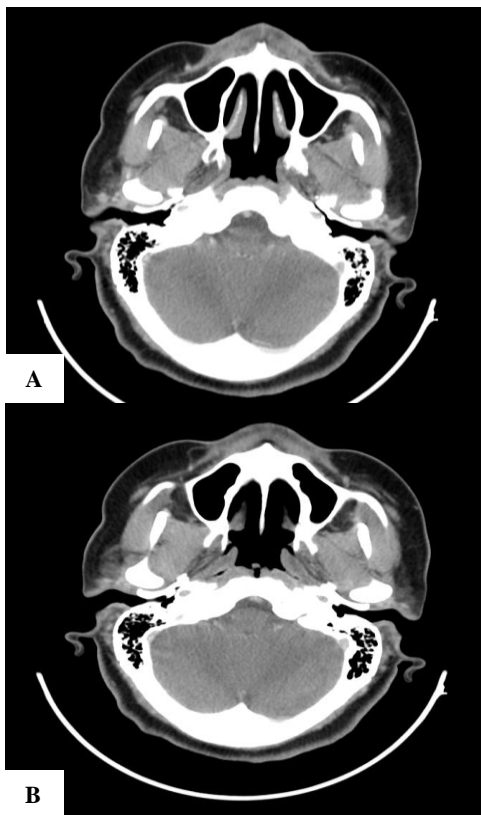


Figure 2 (A and B): Nasopharyngeal mass, a heterogenic lesion without extension to adjacent structures.

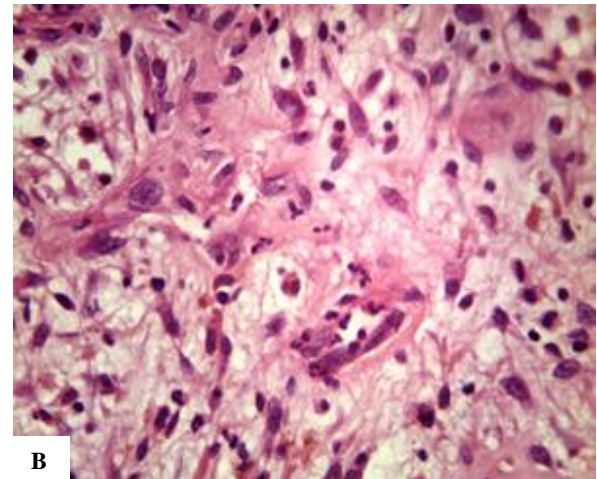
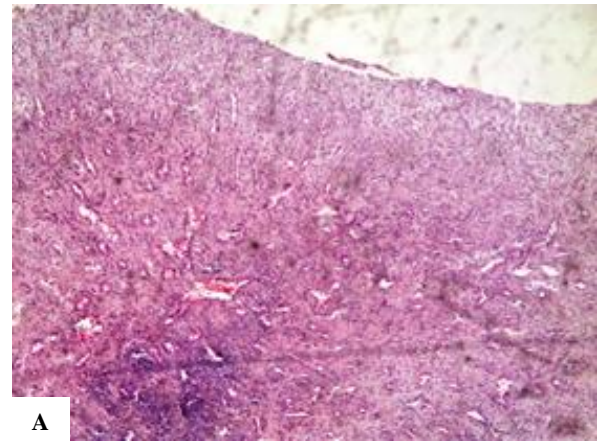


Figure 3 (A and B): Vascularized granulation tissue with ulcerated epithelium and fibrinous exudates. The granulation tissue shows numerous endothelium-lined vascular spaces, proliferation of fibroblasts and mixed inflammatory infiltrate rich in neutrophils and lymphocytes.

On examination, the patient was generally stable, but she had a pedunculated nasopharyngeal lesion 0.5x0.5 cm, smooth, ulcerated (Figure 1). No external affection, normal vision, and normal extraocular movement.

Findings of basic laboratory investigations were normal. CT-scan revealed nasopharyngeal mass, a heterogenic lesion without extension to the orbit or to the brain, and a deformity with bony erosions in the roof of the left orbit and base of skull (Figure 2).

The decision was made to treat the patient operatively. Excision of the lesion was done under general anesthesia by 0 degree nasoscope and cauterization was done for the base.

The lesion was sent for histopathology which revealed polypoidal vascularized granulation tissue with ulcerated epithelium and fibrinous exudates. The granulation tissue showed numerous endothelium-lined vascular spaces, proliferation of fibroblasts and mixed inflammatory infiltrate rich in neutrophils and lymphocytes (Figure 3).

DISCUSSION

Pyogenic granuloma, also known as lobular capillary hemangioma, is a benign proliferative vascular tumor which most commonly affects the skin or mucosa of children.⁸

Cawson et al in dermatologic literature have described PG as “granuloma telangiectaticum” due to the presence of numerous blood vessels seen in histological sections. They described two forms of pyogenic granulomas, the lobular capillary hemangioma (LCH) and the non-lobular capillary hemangioma (non-LCH).⁹

Vinson et al stated that, clinically it is a small, deep red to purple lesion which can be sessile or pedunculated. Pyogenic granuloma surface presents as a smooth, lobulated, ulcerated and easy to bleed in the presence of minor trauma or not. Sizes of PG are small, less than 3 cm and can grow suddenly over weeks or months.¹⁰

The radiological and histopathological investigations can help to diagnose this disease and providing appropriate management. Diagnosis of pyogenic granuloma only can be confirmed by histopathological examination through tissue biopsy. Most of the diseases appear as angiomatous tissue mass with scattered collagen, infiltrated by neutrophils, plasma cells and lymphocytes.¹¹

In our patient, PG was found to be an exophytic mass, which is pedunculated, friable and whitish in color arising from the nasopharynx. PGs are usually soft, painless, vascular and friable with deep red to reddish-purple in color. In concordance with the clinical findings, histologically the lesion showed an inflamed tissue and extensive acute ulceration with focal area of matured squamous epithelium. The stroma of PG in our patient showed lobules of capillary proliferations and neutrophils infiltration with area of necrosis. PG has a lobular growth pattern and rich in vascular proliferation. Ulceration of squamous epithelium overlying the PG can be focal to complete with varying degree of neutrophil infiltration involving the mucosa.¹²

Amirchaghmaghi et al reported that the differential diagnosis for pyogenic granuloma includes Kaposi sarcoma, angiosarcoma, non-Hodgkin's lymphoma, metastatic tumor, post-extraction granuloma, pregnancy tumor, peripheral giant cell granuloma, peripheral ossifying fibroma, hemangioma, peripheral fibroma, leiomyoma, hemangi endothelioma, hemangiopericytoma, bacillary angiomatosis.¹³

Histopathologically, PG can be classified as an LCH and non-LCH.¹⁴ LCH has proliferating blood vessels in lobular aggregates, no specific changes such as edema and capillary dilatation. The non-LCH type consists of vascular core resembling granulation tissue with foci of fibrous tissue. The lobular area of LCH type has a greater number of blood vessels. Oral PGs are mainly LCH

type.¹⁵ The natural course of the lesion can be in three phases of development as cellular phase, vascular phase and phase of involution.¹⁶

Management of pyogenic granuloma by remove all causative agent which can appear due to spontaneous resolution. Good excision of the lesion is the best way treatment.¹⁷ Svirsky noted that there is a relatively high rate of recurrence (about 15%) after simple excision.¹⁸ Recurrences after surgery of extra-gingival pyogenic granuloma is however uncommon.¹⁹

CONCLUSION

This article seeks to report a large PG in the nasopharynx with a detailed review on the etiology, clinical features, histological presentations, differential diagnoses, treatment modalities, and recurrence rate. The clinical features of pyogenic granulomas that are very characteristic, help in making a differential diagnosis but are inadequate for a definitive diagnosis. Histopathological diagnosis is necessary to differentiate PGs from true tumors.

Funding: No funding sources

Conflict of interest: None declared

Ethical approval: Not required

REFERENCES

1. Kamal R, Puri A, Dahiya P. Oral pyogenic granuloma: various concepts of etiopathogenesis J Oral Maxillofac Pathol. 2012;16(1):79-82.
2. Limmonthol S, Sayungkul C, Klanrit P. Oral pyogenic granuloma presenting as an atypically large soft tissue mass: a case report. J Oral Maxillofac Surg Med Pathol. 2014;26(2):258-61.
3. Fortna RR, Junkins-Hopkins JM. A case of lobular capillary hemangioma (pyogenic granuloma), localized to the subcutaneous tissue, and a review of the literature. Am J Dermatopathol. 2007;29:408-11.
4. Abaalkhail F, Castonguay M, Driman DK, Parfitt J, Marotta P. Lobular capillary hemangioma of the liver. Hepatobiliary Pancreat Dis Int. 2009;8:323-5.
5. Abe M, Misago N, Tanaka S, Masuoka J, Tabuchi K. Capillary hemangioma of the central nervous system: a comparative study with lobular capillary hemangioma of the skin. Acta Neuropathol. 2005;109:151-8.
6. Shivaswamy S, Siddiqui N, Jain SA, Koshy A, Tambwekar S, Shankar A. A rare case of generalized pyogenic granuloma: a case report. Quintessence Int. 2011;42:493-9.
7. Ramirez K, Bruce G, Carpenter W. Pyogenic granuloma: case report in a 9-year-old girl. General Dentistry. 2002;50(3):280-1.
8. Patrice SJ, Wiss K, Mulliken JB. Pyogenic granuloma (lobular capillary hemangioma): a

- clinicopathologic study of 178 cases. *Pediatr Dermatol.* 1991;8:267-76.
9. Cawson RA, Binnie WH, Speight PM, Barrett AW, Wright JM. *Lucas Pathology of Tumors of oral Tissues.* 5th edition. Missouri: Mosby; 1998: 252-254.
 10. Fernandes VLG, Pinto NMD, Sanzgiri VB, Khandolkar P, Sukhthankar IR. A rare case report of pyogenic granuloma of tongue. *Int J Otolaryngol Head Neck Surg.* 2018;7:75-9.
 11. Bhaskar SN, Jacoway JR. Pyogenic granuloma—clinical features, incidence, histology and result of treatment. Report of 142 cases. *J Oral Surg.* 1996;24:391-8.
 12. Xu Q, Yin X, Sutedjo J, Sun J, Jiang L, Lu L. Lobular capillary hemangioma of the trachea. *Arch Iran Med.* 2015;18(2):127-9.
 13. Amirchaghmaghi M, Farnaz F, Nooshin M, Mozafari PM. Extralingival pyogenic granuloma: a case report. *Cases J.* 2008;1:371.
 14. Neville BW, Damm DD, Allen CM, Bouquot JE. *Oral and Maxillofacial Pathology.* 2nd edition. Philadelphia: Saunders; 2002: 437-495.
 15. Gomes SR, Shakir QJ, Thaker PV, Tavadia JK. Pyogenic granuloma of the gingiva: a misnomer? - a case report and review of literature. *J Indian Soc Periodontol.* 2013;17:514-9.
 16. Sternberg SS, Antonioli DA, Carter D, Mills SE, Oberman H. *Diagnostic Surgical Pathology.* 3rd edition. Philadelphia: Lippincot Williams and Wilkins; 1999: 169-174.
 17. Lawoyin JO, Arotiba JT, Dosumu OO. Oral pyogenic granuloma. A review of 38 cases from Ibadan, Nigeria. *Brit J Oral Max Surg.* 1997;35:185-9.
 18. Svirsky J. Oral pyogenic granuloma. *J Indiana Dent Assoc.* 2007;86(1):12-4.
 19. Patil K, Mahima VG, Lahari K. Extralingival pyogenic granuloma. *Indian J Dent Res.* 2006;17:199-202.

Cite this article as: Assiri KS, Al-Ahmari MS. A rare case report of pyogenic granuloma of nasopharynx. *Int J Otorhinolaryngol Head Neck Surg* 2019;5:1091-4.