

## Original Research Article

# Posteriorly based dorsal tongue flap in buccal carcinoma: an institutional experience

Pankaj Kumar Sahu<sup>1</sup>, Kamal Deep Joshi<sup>2\*</sup>, Manmohan Singh Brar<sup>3</sup>

<sup>1</sup>Department of ENT and Head & Neck Surgery, Command Hospital Lucknow, Uttar Pradesh, India

<sup>2</sup>Department of ENT, Military Hospital, Roorkee, Uttarakhand, India

<sup>3</sup>Department of Preventive and Social Medicine, Military Hospital, Meerut, Uttarakhand, India

**Received:** 19 January 2019

**Revised:** 12 March 2019

**Accepted:** 14 March 2019

### \*Correspondence:

Dr. Kamal Deep Joshi,

E-mail: [kdeepjoshi@rediff.com](mailto:kdeepjoshi@rediff.com)

**Copyright:** © the author(s), publisher and licensee Medip Academy. This is an open-access article distributed under the terms of the Creative Commons Attribution Non-Commercial License, which permits unrestricted non-commercial use, distribution, and reproduction in any medium, provided the original work is properly cited.

## ABSTRACT

**Background:** Defect following surgical management of Squamous cell carcinoma of buccal mucosa often requires reconstruction for restoration of form and function of oral cavity. Posteriorly based dorsal tongue flap is well known, but less utilised technique for such reconstruction. The aim of this article is to present institutional experience of posteriorly based dorsal tongue flap as a reconstructive option in selected cases of carcinoma of buccal mucosa after wide local excision with marginal mandibulectomy and its impact on rehabilitation.

**Methods:** In this cohort study, twelve selected cases of early carcinoma buccal mucosa, who underwent surgical excision with marginal mandibulectomy with reconstruction with posteriorly based dorsal tongue flap were included and followed up for at least one year. Objective evaluation of swallowing and subjective evaluation of speech was done. The total duration of the study was three years. Statistical analysis was done using Friedman test and Wilcoxon Sign-Rank test using SPSS 2.0.

**Results:** The result of the study showed that there is significant reduction in swallowing function in post-operative period as determined by MDADI score. However there is significant improvement at Six weeks compared to 10th post-operative day. The speech also remains intelligible. No flap related complication was observed.

**Conclusions:** Posteriorly based dorsal tongue flap is a simple, reliable and versatile flap for reconstruction of surgical defects following wide local excision and marginal mandibulectomy for early carcinoma of buccal mucosa, without substantial morbidity and with satisfactory swallowing and speech.

**Keywords:** Tongue flap, Oral carcinoma, Buccal carcinoma, Swallowing, Flap reconstruction

## INTRODUCTION

Squamous cell carcinoma (SCC) of the oral cavity constitutes most common malignancy in south-east Asia and has high incidence in developing and underdeveloped countries. Buccal mucosa is the commonest subsite in oral cavity affected by SCC.<sup>1,2</sup> Incidence of carcinoma buccal mucosa has regional and demographical variance and the reported incidence can be as high as 57.8% of all carcinomas of oral cavity.<sup>3</sup> Surgery is the main modality of management of cancer of buccal mucosa. Surgery and

if required, post-operative adjuvant therapy in the form of radiotherapy or chemoradiotherapy is the main modality of management.<sup>4</sup> Surgical resection with adequate margins is dictum for oncological clearance. Multimodality treatment has added advantage in management and 05 years survival has improved drastically, especially for early stages of buccal mucosa carcinoma.<sup>5</sup>

The surgical management for cancer buccal mucosa, especially the reconstructive aspect, is how ever

challenging. Reconstruction is important for functional and rehabilitative purposes, as surgery is often associated with loss of form and function of the affected site. It is also important in improving quality of life of the patient. There are multiple reconstructive options in cases of carcinoma buccal mucosa which include local flap, regional flap and free flap. Free fibula osseo-cutaneous flap, free radial forearm flap, free antero-lateral thigh flap are few main flaps used in reconstruction of head neck malignancies. But these flaps require adequate expertise and long duration of surgery and cost of surgery for free flaps is also a major drawback. Failure of free flaps compromises in starting adjuvant therapy. Regional or local flaps are also helpful in many other situations for reconstruction after resection without compromising quality of life. One such versatile local flap is posteriorly based dorsal tongue flap. It is easy to harvest and give good quality reconstruction for selected cases of cancer of buccal mucosa. In this article, institutional experience of using posteriorly based dorsal tongue flap in selected group of patients of carcinoma buccal mucosa is being discussed.

The aim of this paper is to present institutional experience of posteriorly based dorsal tongue flap as a reconstructive option in selected cases of carcinoma of buccal mucosa after wide local excision with marginal mandibulectomy and its impact on swallowing and speech rehabilitation.

## METHODS

The present study is a prospective observational study carried out over a period of three years (March-2015 to November-2018) in a tertiary care centre in Lucknow. In this study, 12 cases of operated carcinoma buccal mucosa

with marginal mandibulectomy were included. Cases were oncologically evaluated in detail with imaging and biopsy. All cases were histologically confirmed cases of squamous cell carcinoma of buccal mucosa. The inclusion criteria were all cases of carcinoma buccal mucosa (T1 & T2), close or juxtaposed to lower alveolus which were managed by surgery in the form of wide local excision with marginal mandibulectomy with neck dissection. Exclusion criteria were advanced carcinoma of buccal mucosa involving mandible, gross paramandibular disease, disease reaching upto upper alveolus and skin involvement. All patients were followed up for atleast one year after definite therapy for control of disease. Flap viability and functional status of speech and swallowing were assessed and analysed statistically using SPSS 2.0 software.

## RESULTS

The present study included 12 cases of carcinoma buccal mucosa, which included eight males and four female, with the mean age of 58.58 years (range 47 years to 72 years). There were two cases in stage I, four cases in stage II and six cases in stage III (Table 1). The mean size of post-operative defect was 03.67 cm with range from 02 cm to 5.5 cm.

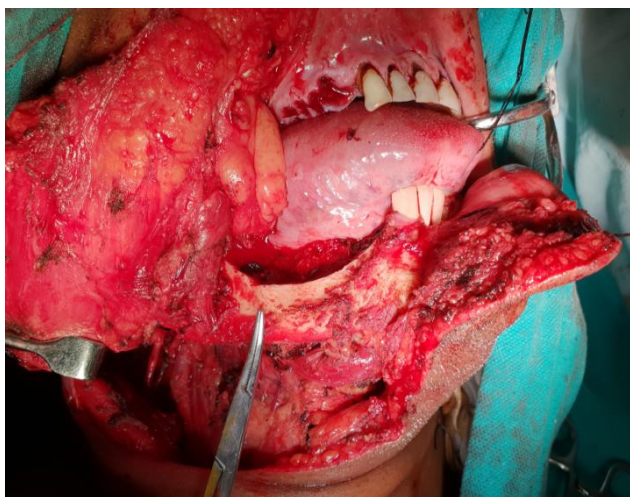
When non-parametric statistical Friedman test was applied to MDADI score of three groups, it was found that there was a statistically significant difference in the MDADI scores depending on whether they were measured pre-operatively, at 10 days or at 06 weeks (Chi Square statistic=20.67, p=0.000).

**Table 1: Management and MDADI results of subjects.**

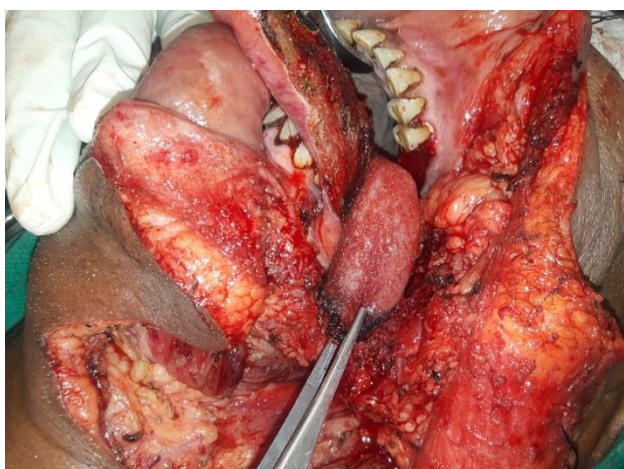S No	T Classification	N Classification	Stage	Size of defect (cm)	Neck dissection	Pre-operative MDADI score	MDADI score at post-operative day 10	MDADI score at Post-operative week 6
1	1	0	I	3	Selective	100	82	94
2	2	1	III	4.5	Comprehensive	96	72	87
3	2	1	III	3.5	Comprehensive	97	69	92
4	2	0	II	3	Selective	100	76	88
5	1	0	I	4	Selective	90	70	94
6	1	1	III	2	Comprehensive	98	78	90
7	2	0	II	4	Selective	96	71	83
8	2	0	II	4.5	Selective	89	65	86
9	2	1	III	5	Comprehensive	92	68	84
10	1	1	III	2.5	Comprehensive	98	74	82
11	2	2	III	5.5	Comprehensive	86	53	80
12	2	0	II	2.5	Selective	88	74	92
						Mean=94.17	Mean= 71	Mean= 87.67
						Standard deviation=4.914	Standard deviation=7.311	Standard deviation= 4.793

Wilcoxon Sign-Rank test was used to study the difference between the pre-operative MDADI score and MDADI score at post-operative day-10, pre-operative MDADI score and MDADI score at post-operative 6th week and finally MDADI score at post-operative day 10 and MDADI score at post-operative 6th week (Table 1). Preoperative MDADI score and MDADI score at postoperative day-10 showed a statistically significant decrease in the score after the surgery ( $Z=-2.536$ ,  $p=0.011$ ). The preoperative MDADI score and MDADI score at 06 week post surgery showed a statistically significant decrease in the score after the surgery. ( $Z=-2.670$ ,  $p=0.008$ ). Comparison of MDADI score at Post-operative day 10 and 06 weeks showed statistically significant improvement in score ( $Z=-3.071$ ,  $p=0.002$ ).

The test results show that there is significant reduction in swallowing function following surgery. At 06 weeks, there is significant recovery in the swallowing as compared to 10th post-operative day, as suggested by improving MDADI scores.



**Figure 1: Surgical defect after excision of carcinoma buccal mucosa and marginal mandibulectomy.**



**Figure 2: Posteriorly based dorsal tongue flap covering the surgical defect.**

## DISCUSSION

The treatment of carcinoma oral cavity is primarily surgery with three dimensional disease clearance for clear margin. This often results in defects oral cavity, leading to overall deterioration in quality of life of the patient. The swallowing and speech are main functions of the oral cavity and its loss is often debilitating. Swallowing is important, specially in convalescence period, where it affect overall nutrition of the patient apart from affecting quality of life. There are multiple options for reconstruction of oral cavity defect and restoration of functions. Smallest of the defect can heal with secondary intention or primary closure can be attempted. Larger defects require some reconstruction with flap. A variety of free and pedicled flaps, both local and distant are available. Free flaps have proven to be most versatile technique, however require microvascular reconstruction. The technique of microvascular anastomosis requires availability of expertise, is often time consuming and can be considered only if general condition of the patient and anatomical and physiological condition of local host and donor area are conducive. Distant pedicled flaps like PMMC, are also being utilised in reconstruction of reconstruction of defect resulting from surgery of oral and oropharyngeal carcinoma. However distant pedicled flaps are often bulky, requires extensive procedures and results in significant donor site morbidity. Many local flaps like tongue flap, naso-labial flap etc have been described in literature for reconstruction. In this study, selected group of patients of SCC buccal mucosa was treated with surgical (wide local) resection and reconstruction was done using posteriorly based dorsal tongue flap. The tongue as a donor tissue, is highly vascular and available adjacent to the defect. This result in excellent healing and least morbidity. Although, a variety of tongue flaps have been described, a posteriorly based dorsal tongue flap (ipsilateral to the defect) was utilised in defect reconstruction for this study. The dorsal longitudinal tongue flap is based on the branches of the dorsal lingual artery, which forms an extensive anastomotic network with branches from the contralateral side at the tip and base. The advantage of this flap is that it readily and easily available locally, does not change texture of oral cavity and heals rapidly due to abundant vascularity, without any significant morbidity to host or donor area. However this flap cannot be utilised for larger defect, usually more than 5 cm.

Although the tongue flap can be utilised for vast number of intra-oral lesions, the present study was conducted only on selected group of patients with early carcinoma buccal mucosa, who underwent reconstruction using tongue flap following excision with marginal mandibulectomy. Speech was evaluated subjectively and swallowing was assesses objectively with MD Anderson dysphagia inventory (MDADI). MDADI is a self administered questionnaire of 20 questions to assess effect of dysphagia on quality of life of the patients with head and neck cancer. It evaluates 03 domains

(emotional, functional and physical) and 01 global assessment question, with each sub scale with 5 possible responses scored on scale of 1 to 5. The total score range from 0 to 100 (extremely low function to higher function) and a higher score representing better day to day functioning and quality of life. This score was selected for this study, as it has universal applicability to head and neck cancer patient with minimal training required.<sup>6</sup> The test results of present study show that there is significant reduction in swallowing function following surgery. At 06 weeks, there is significant recovery in the swallowing, as MDADI scores improves. The observation of the present study also showed that tongue flap for reconstruction buccal mucosa defect with marginal mandibulectomy require a modest time. The time required for the procedure ranged from 40 to 55 minutes with graft harvesting requiring only 15 to 20 minutes. There was no graft related complication or graft failure detected while the patients were observed for a period of minimum 01 year. The quality of voice of patients was assessed subjectively by questioning the close relatives and care-takers about intelligibility of the speech pre and post-surgery. The speech was intelligible for all patient without hampering communication. As floor of the mouth is not included in the dorsal tongue flap, hence mobility of the tongue and speech remain normal. Kim et al have described the use of tongue flap for intraoral reconstruction in 16 patient with only one total necrosis and successful flap in remaining cases.<sup>7</sup> Other studies have also found that speech has a good functional outcome with dorsal tongue flap.<sup>8</sup>

The swallowing is the most important function in patients of carcinoma, determining fulfilment of nutritional requirement in immediate post-operative period. The present study has focused on effect of reconstruction of buccal mucosa defect with tongue flap on swallowing and MDADI score has been instrumental in conduction of the study.

The results of study are clearly indicative of the fact that early SCC buccal mucosa has minimal effect on swallowing, as indicated by MDADI score. In immediate post-operative period the mean MDADI score decline, which is suggestive that swallowing is difficult during this period. However at 3 weeks, the MDADI score recovers to significantly better levels, as compared with score at post-operative day 10. The tongue flap does not adversely effect swallowing for prolonged periods and swallowing recovery is excellent. In a recent study by Deshmukh et al, the authors have described the use of tongue flap in 27 patients and found that patients have good swallowing following application of dorsal tongue flaps for local reconstruction.<sup>8</sup> Pawar et al in their institutional study have included 21 patients of oral carcinoma who underwent tongue flap reconstruction following resection of oral carcinoma. A total of 16 cases were carcinoma buccal mucosa and all patient had

satisfactory mouth opening, mobility of tongue and speech and swallowing function.<sup>9</sup>

Single- staged posteriorly based dorsal tongue flap is a simple, reliable and versatile flap for reconstruction of various defects oral cavity and oropharynx. It provides good functional results without much morbidity and with satisfactory swallowing and speech. The present study was carried out on the patients, selected with restricted inclusion criteria and hence enrolled sample size was small. However, the result of this study shows that reconstructive outcome with posteriorly based dorsal tongue flap are good in maintaining desired swallowing and speech outcomes in selected group of patients.

*Funding: No funding sources*

*Conflict of interest: None declared*

*Ethical approval: The study was approved by the Institutional Ethics Committee*

## REFERENCES

1. Padma R, Thilagavathi R, Sudaresan S. Survival outcome of buccal mucosa carcinoma with multimodal therapy: An institutional study. *Int. J. Nutr. Pharmacol. Neurol. Disease* 2016;6:76-80
2. Varshita A. Prevalence of oral cancer in India. *J Pharm Sci R.* 2015;7(10):845-8.
3. Ramachandra NB. The hierarchy of oral cancers in India. *Int J H&N Surg.* 2012;3(3):143-8.
4. Montero PH, Patel SG. Cancer of the oral cavity. *Surg Oncol Clin N Am.* 2015;24(3):491-508.
5. Geum DH, Roh YC, Yoon SY, Kim HG, Lee JH, Song JM, et al. The impact factors on 5-year survival rate in patients operated with oral cancer. *J. Korean Assoc. Oral Maxillofac Surg.* 2013;39(5):207-16.
6. Chen AY, Frankowski R, Bishop LJ, Herbert T, Leyk S, Lewin J, et al. The Development and Validation of a Dysphagia-Specific Quality-of-Life Questionnaire for Patients With Head and Neck Cancer The M. D. Anderson Dysphagia Inventory. *Arch Otolaryngol Head Neck Surg.* 2001;127(7):870-6.
7. Kim YK, Yeo HH, Kim SG. Use of the tongue flap for intraoral reconstruction: a report of 16 cases. *J. Oral Maxillofac Surg.* 1998;56(6):716-21.
8. Deshmukh A, Kannan S, Thakkar P, Chaukar D, Yadav P, D'Cruz A. Tongue flap revisited. *J Can Res Ther.* 2013;9:215-8.
9. Pawar SS, Lata KA. Tongue flap reconstruction for defects after resection of oral cancer: a versatile flap. *Eur J Can.* 2017;72:112.

**Cite this article as:** Sahu PK, Joshi KD, Brar MS. Posteriorly based dorsal tongue flap in buccal carcinoma: an institutional experience. *Int J Otorhinolaryngol Head Neck Surg* 2019;5:714-7.