

Original Research Article

DOI: <http://dx.doi.org/10.18203/issn.2454-5929.ijohns20190046>

A cross sectional study to assess the role of preoperative HRCT temporal bone in CSOM: a comparison between middle ear surgeries with and without pre-op HRCT

Madhuri S. More¹, Rahul B. Patel^{2*}, Jaymin A. Contractor², Alpa A. Pipaliya³,
Esha J. Desai², Bhavik M. Patel²

¹Department of ENT, Government Medical College, Miraj, Maharashtra, India

²Department of ENT and Head & Neck Surgery, Govt Medical College & New Civil Hospital, Surat, Gujarat, India

³Class I ENT Surgeon, Community Health Center, Bharuch, Gujarat, India

Received: 05 December 2018

Revised: 06 January 2019

Accepted: 07 January 2019

*Correspondence:

Dr. Rahul B. Patel,

E-mail: dr_rahulpatel26@yahoo.co.in

Copyright: © the author(s), publisher and licensee Medip Academy. This is an open-access article distributed under the terms of the Creative Commons Attribution Non-Commercial License, which permits unrestricted non-commercial use, distribution, and reproduction in any medium, provided the original work is properly cited.

ABSTRACT

Background: Importance of HRCT before middle ear surgery is proved by many published articles but most of the studies were done without evaluating the accuracy of clinical judgment at the same time.

Methods: All the patients of CSOM in whom the middle ear surgery was planned were included in the study. Total number of sample size was 80 patients. Group A: 20 patients in which HRCT temporal bone was indicated as a routine evaluation before middle ear surgeries. Group B: 60 patients in which HRCT temporal bone was not indicated.

Results: Maximum 43.75% (35) patients belong to 21 to 30 years. F:M is 1.5:1. Unilateral ear disease is more common (62.5%). 41.8% had mucosal type while 16.25% had squamosal type of COM. 77.5% ears found to have hearing loss. Conductive hearing loss was the most common (43.13%). HRCT in comparison with Intra-op had Kapa value of 1 (aditus blockage and tegmen erosion), 0.6 (sinus plate erosions), 0.5 (malleus, Incus, stapes erosions), 0.48 (ossicular chain status), 0.46 (scutum erosion), 0.4 (LSC fistula) and 0.3 (fallopian canal erosions). Clinical judgment in comparison with intra-op had kapa value of 1 (stapes erosion), 0.96 (aditus blockage), 0.79 (incus erosion), 0.78 (malleus erosion) and 0.76 (ossicular chain status).

Conclusions: Clinical judgment is as good as or even better than CT in presuming/detecting at least individual ossicular erosions, ossicular chain status, aditus blockage and HRCT temporal bone should be reserved for high risk and complicated cases.

Keywords: CSOM, Middle ear surgery, HRCT temporal bone

INTRODUCTION

Chronic suppurative otitis media (CSOM) is an inflammation of middle ear of greater than two weeks that results in ear discharge.¹ Earlier, in majority of the cases, a diagnosis was made by clinical examination alone. With the advent of HRCT, the ability to evaluate hard-to-reach and complex anatomical areas like Ear and

the extent of disease without invasive techniques (such as surgery) has vastly increased.² Multi-slice helical CT scans are widely used in temporal bone disease for its diagnostic ability as well as surgical planning and postoperative follow-up. However, CT imaging's role in certain ear diseases such as uncomplicated COM remains under question.² There are concerns that CT cannot reliably distinguish cholesteatoma from mucosal disease

and that it lacks guaranteed sensitivity for erosive complication³

Before planning any middle ear surgery, clinical examination i.e. otoscopy/otoendoscopy and/or otomicroscopy, Valsalva manoeuvre, Fistula test etc. give important information regarding existing middle ear status and disease. Similarly pure tone audiometry (PTA) also gives very important information regarding the ossicular chain status especially in conductive and mixed hearing loss. If this information used along with the knowledge gained from history than we can make fairly accurate clinical judgement regarding the ear disease and findings which we are likely to encounter during the most middle ear surgeries. Even today CT is a costlier investigation and beyond the reach of many patients especially in many rural areas of India. Also, unlike plain x-rays, it is still not as easily available at all centres. Considering all these aspects, the trend to insist CT temporal bone in evaluation of all cases of CSOM and before all middle ear surgeries needs to be evaluated and justified.

On reviewing the literature we found that many has done the same by analyzing sensitivity and specificity of HRCT temporal bone with intra-op correlation. But we found not a single one which has analyzed efficacy of clinical judgment without HRCT which further decides indirectly the role of HRCT.

Hence, we decided to design this study to compare the efficacy of the clinical judgement vs. efficacy of CT temporal bone in detecting the middle ear status and different pathological findings.

Aims and objectives

- To compare preoperative expected findings (clinical judgment) using “oto-endoscopy and/or microscopy and audiometry” with intra-operative findings.
- To compare preoperative findings of HRCT temporal bone with intra-operative findings.
- To detect accuracy of clinical judgement and CT temporal bone in detecting pathological findings in all cases undergoing middle ear surgeries.

METHODS

This was a cross sectional study done in Department of ENT, New Civil Hospital, Surat. Study was done from October 2014 to October 2016. All the patients of CSOM in whom the middle ear surgery was planned were included in the study. Total number of sample size was 80 patients.

Inclusion criteria

Inclusion criteria were patients of CSOM who required middle ear surgery; patients who gave written consent for inclusion in the study.

Exclusion criteria

Exclusion criteria were patients who did not give consent; revision middle ear surgeries.

The patients were divided in following two groups:

Group A: Those in whom the CT Temporal Bone was done as a routine pre-operative evaluation & includes 20 patients.

Indications of CT temporal bone as routine protocol in our department are:

- Signs/symptoms of any complications of CSOM
- Middle ear surgeries done in children
- Revision ear surgeries

Group B: Those who do not require CT temporal bone as a routine investigation before middle ear surgery and includes 60 patients.

Criteria of expected findings of clinical judgement based on clinical examination and Pure Tone Audiometry (PTA) were pre-defined and were as follows:

(A) When in otoscopy/otoendoscopy/microscopy ossicular bones cannot be evaluated.

- Attic cholesteatoma- Malleus and Incus expected to be eroded
- PSQ cholesteatoma- Incus and Stapes expected to be eroded
- In Attic and PSQ cholesteatoma all three ossicles expected to be eroded
- PTA with 3 frequency average AB gap of more than 55 dB expected to have disrupted ossicular chain continuity
- PTA in tubo-tympanic COM cases with 3 frequency average AB gap less than 55 db expected to have ossicular continuity maintained.
- In Attico-Antral CSOM, irrespective of AB gap ossicular chain continuity expected to be disrupted.

(B) When in otoscopy/otoendoscopy/microscopy ossicular bones can be evaluated:

If any ossicle found to be absent (completely or partly) then that ossicle expected to be eroded. E.g. In large central perforation long process of Incus not seen and only Head of stapes seen then incus expected to be eroded.

(C) In inactive stage of benign COM Aditus was expected to be patent.

(D) In all attico-antral cases aditus was expected to be blocked.

Even a partial erosion of individual bone found intra-op was considered as eroded bone for purpose of comparison with expected findings clinically and with CT findings.

Statistical analysis

Following statistical parameters used to express study results:

- Proportions
- Sensitivity
- Specificity

Cohen's Kapa

Kapa value establish "levels of agreement (none: 0-0.20, minimal: 0.21-0.39, weak: 0.40-0.59, moderate: 0.60-0.79, strong: 0.80-0.90, almost perfect: 0.91-1)" between two tests, one of the test may be gold standard. Value is 0 to 1, with 0 means minimal and 1 means the perfect agreement between two tests regarding different findings. Values less than 0.6 mean weak agreement between two tests and if one of the tests is gold standard then it interprets that other test is poor in detecting the particular clinical finding as compared to gold standard.

RESULTS

Observations in total study population (n=80)

In our study there are patients ranging from 3 to 50 years. Maximum 43.75% (35) patients belong to 21 to 30 years. We found that females affected more than males i.e. 61.25% (49) females and 38.75% (31) males thus F: M is 1.5:1 and it was further observed that higher female: male ratio is maintained in individual age groups also. Unilateral ear disease is more common (62.5%) as compared to bilateral (37.5%). Amongst unilateral disease, left is more commonly involved (35%) as compared to right (27.5%).

Observations based on clinical examinations (Otoscopy, Otoendoscopy &/or oto-microscopy):

Type of CSOM (n=80*2=160): 58.13% (93) ears found to have CSOM out of which 67 (41.8%) had mucosal type while 26 (16.25%) had squamosal type.

Clinical findings (n=160): Amongst mucosal type of CSOM the most common finding was large central perforation i.e. 32(20%). This was followed by moderate sized and small central perforation in 27 (16.9%) and 8 (5%) respectively.

Amongst squamosal type, the most common finding was PSQ cholesteatoma i.e. 9 (5.62%). This was followed by attic cholesteatoma 7 (4.37%), polyp 7 (4.37%) and PSQ with attic cholesteatoma 3 (1.87%).

Observations based on PTA

Type of hearing loss (n=160)

124 (77.5%) ears found to have hearing loss. Conductive hearing loss was the most common i.e. 69 (43.13%) ears. This is followed by mixed and sensory neural in 40(25%) and 15 (9.37%) ears respectively.

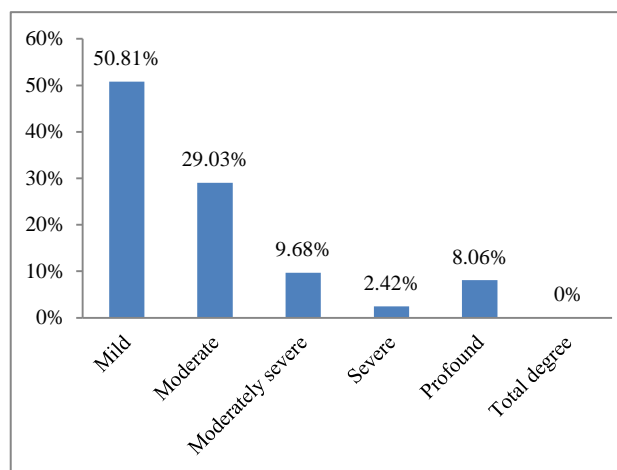


Figure 1: Degree of hearing loss (n=124).

Out of 124 ears found to have hearing loss, mild degree was most common found in 63 (50.81%) ears. This is followed by moderate in 36 (29.03%), moderately severe in 12 (9.68%), profound in 10 (8.06%) and severe in 03 (2.42%) ears. 59 (47.58%) ears were right and 65 (52.42%) were left.

As shown in Figure 2, incus was the most common ossicle found eroded in CT (65%) as well as intra-op (85%). This was followed in order by stapes (55% and 60%) and malleus (50% and 45%) respectively. CT slightly underestimated the Incus and stapes erosion while slightly overestimated the malleus erosion. For other than ossicles, CT overestimated most of the bony erosions. CT appears to be best in detecting the tegmen erosion and aditus blockage while poorest in detecting the incus & fallopian canal erosion.

Table 1 shows that for aditus blockage, tegmen erosion and Sinus plate erosion sensitivity and specificity are more than 90% and kapa value is more than 0.6 which means, CT is in moderate to perfect agreement with the gold standard intra-op in detecting these clinical findings and it is statistically significant (p value less than 0.05).

For all other findings kapa value is less than 0.59 so CT has only weak/minimal agreement with gold standard for those findings and it is also statistically significant (p value less than 0.05). CT is weakest in detection of LSC fistula followed by fallopian canal erosion.

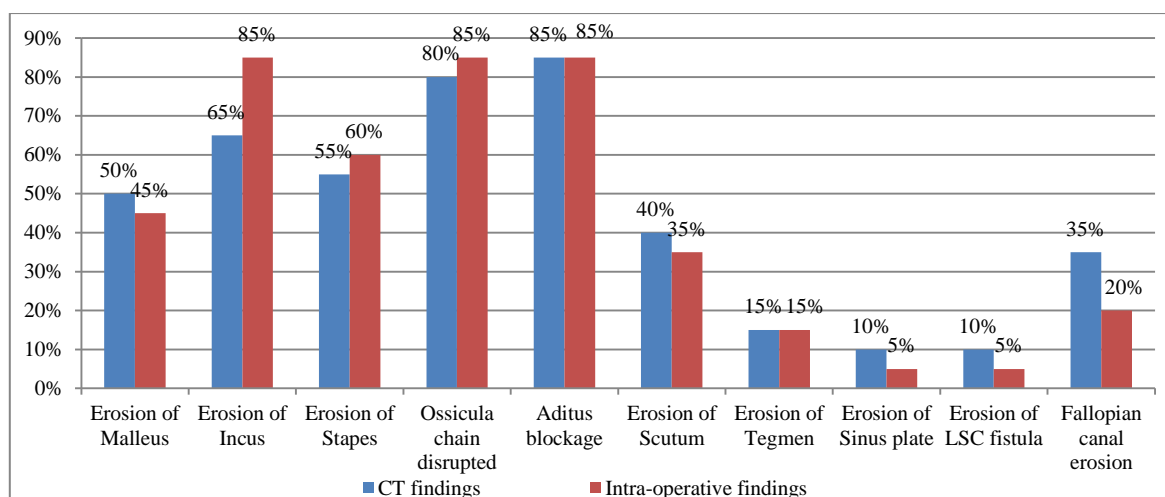


Figure 2: Prevalence of different clinical findings in CT and intra-op (Group A, n=20).

Table 1: Statistical analysis of correlation between CT findings with intra-operative findings (Group A).

Si no.	Variables	CT	Intra-op (No)		Sensitivity (%)	Specificity (%)	Kapa value	P value
			Erosion /block	Intact/ patent				
1	Malleus	Erosion	7	3	77.8	72.7	0.5	0.02
		Intact	2	8				
2	Incus	Erosion	13	0	76.5	100	0.49	0.01
		Intact	4	3				
3	Stapes	Erosion	9	2	75	75	0.5	0.02
		Intact	3	6				
4	Ossicular chain	Erosion	15	1	88.2	66.7	0.48	0.028
		Intact	2	2				
5	Aditus	Block	17	0	100	100	1	0.000
		Patent	0	3				
6	Scutum	Erosion	5	3	71.4	76.9	0.46	0.03
		Intact	2	10				
7	Tegmen	Erosion	3	0	100	100	1	0.000
		Intact	0	17				
8	Sinus plate	Erosion	1	1	100	94	0.6	0.002
		Intact	0	18				
9	LSC*	Erosion	1	1	100	25	0.3	0.04
		Intact	0	18				
10	FC* erosion	Erosion	3	4	75	75	0.4	0.06
		Intact	1	12				

*LSC- lateral semi-circular canal, FC-fallopian canal.

As shown in Figure 3, incus was the most common ossicle predicted to be eroded by clinical judgment (25%) as well as intra-op (30%). This was followed in order by stapes (8.3% and 8.3%) and malleus (8.3% and 8.3%) respectively. It is seen that clinical judgment is perfect in detecting malleus and stapes erosion while it slightly underestimated the incus erosion. Ossicular chain continuity is also slightly underestimated by clinical judgment, though prevalence of aditus blockage is almost same as in clinical judgment and intra-op.

Though other bony erosions like tegmen, fallopian canal, sinus plate, LSC fistula etc. cannot be judged or seen in any way by clinical judgment.

Table 2 shows that for all individual ossicular erosion, ossicular chain continuity and aditus blockage kapa value for clinical judgment is more than 0.7 which suggest moderate, near strong and near perfect agreement with intra-op findings and it is statistically significant.

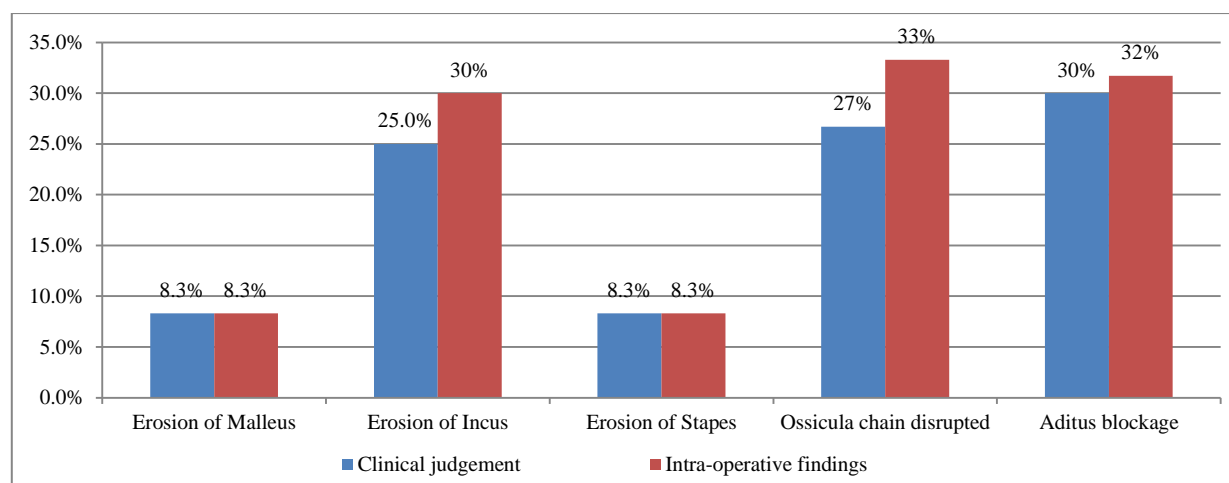


Figure 3: Prevalence of different clinical findings as predicted by clinical judgment and seen intra-op (Group B, n=60).

Table 2: Statistical analysis of correlation between clinical judgment with intra-operative findings (n=60).

Sr no.	Variables	Clinical judgement	Intra-op (No)		Sensitivity (%)	Specificity (%)	Kapa value	P value
			Erosion	Intact				
1	Malleus	Erosion	4	1	80	98.2	0.78	0.00
		Intact	1	54				
2	Incus	Erosion	14	1	77.8	97.6	0.79	0.00
		Intact	4	41				
3	Stapes	Erosion	5	0	100	100	1	0.00
		Intact	0	55				
4	OC*	Disrupted	15	1	75	97.5	0.76	0.00
		Continuous	5	39				
5	Aditus	Block	18	0	94.7	100	0.96	0.00
		Patent	1	41				

*OC-ossicular chain.

DISCUSSION

Present study includes 80 patients. In our study there were patients ranging from 3 to 50 yrs. 21 to 30 years age group (43.75%) and 11 to 20 years (22.5%) are the most common age groups in whom CSOM is detected. Together they constitute 64.25% of the study population. These results were similar to the study done by Deviana et al, Chunilal et al and Sandeep et al.⁴⁻⁶ All of them found that majority of patients of CSOM were among the age group 21-30 years. Rohit et al reported 41-50 yrs age group is the commonest age group while Sharmila et al reported 11-20 years as the commonest age group.^{7,8}

In our study we found that F:M is 1.5:1. This higher F:M ratio is maintained even in individual age groups also. These results of our study are similar to the study done by Mohammed et al and Deviana et al who also found higher proportion of females in their study (1.2:1 reported by both).^{4,9} Rohit et al and Sharmila et al reported higher proportion of males.^{7,8}

In our study unilateral ear disease was more common (62.5%) as compared to bilateral (37.5%). In unilateral disease left ear is more commonly involved (35%) than right (27.5%). These results are similar to the study done by Chunilal et al which show that 76% had unilateral involvement.⁵ Deviana et al also found that unilateral ear disease is more common and found in 67.2% as while bilateral ear disease in 32.8%.⁴

Amongst 160 ears (of 80 patients) 58.13% cases had CSOM out of which 41.8% had mucosal type while 16.25% had squamosal. Amongst mucosal type of COM, the most common finding was large central perforation 20% followed by moderate and small central perforation in 16.9% and 5% respectively. These results were similar to the study performed by Deviana et al which shows that mucosal type of COM is more common (76.11%) than squamosal type of COM (23.89%).⁴

This study had found 77.5% ears having hearing loss. Conductive type was the most common (43.13% ears). This is followed by mixed and sensory neural type in

25% and 19.37% respectively. Mild and moderate degree of hearing loss was most common, found in 50.81% and 29.03% ears respectively. 8.06% cases had profound hearing loss. These results of our study are similar to the study done by Mohammed et al, Deviana et al according to which conductive hearing loss was 60.71% and 59% cases respectively.^{4,9} According to Deviana et al after conductive hearing loss mixed (27%) is more common than sensorineural (8%).⁴

In group A (n=20), incus was the most common ossicle found eroded in CT (65%) as well as intra-op (85%) in present study. This was followed in order by stapes erosion (55% and 60%) and malleus erosion (50% and 45%) respectively. Rohit et al also reported incus, malleus and stapes erosion found in that order in 48%, 30% and 30% cases respectively.⁷ Study done by Sharmila et al also found Incus being the commonest ossicle found eroded (93%); though according to them malleus is more commonly eroded than stapes.⁸ According to our study, amongst other than ossicles; Scutum was the most common bone found eroded (40% in CT and 35% intra-op). Mohammed et al also concluded that scutum is the most common bone found eroded.⁹ Study done by Chunilal et al found scutum erosion in 42% cases.⁵

On correlation with intra-op findings we found that HRCT slightly underestimated incus and stapes erosion, while slightly overestimated malleus erosion. We also correlated prevalence of other individual bony erosions (i.e. scutum, tegmen, fallopian canal, LSC etc.) in HRCT vs. intra-op and found that CT overestimated most of them. HRCT appears to be best in detecting the tegmen erosion and aditus blockage while poorest in detecting the incus and fallopian canal erosion.

For aditus blockage, tegmen erosion and sinus plate erosion HRCT had sensitivity and specificity of more than 90% and kapa value of more than 0.6 which means that CT is in moderate to perfect agreement with the gold standard of intra-op confirmation. These values are statistically significant (p value less than 0.05). For all other findings kapa value is less than 0.59 so CT is in weak to minimal agreement with gold standard intra-op findings. These values are also statistically significant (p value less than 0.05). CT is weakest in detection of LSC fistula followed by fallopian canal erosion.

Ghada et al reported that CT is poor in detection of fallopian canal erosion (kapa value 0.39 i.e. minimal agreement) which is also seen in our study.¹⁰ For all other findings Ghada et al reported CT with kapa value of more than 0.6 for most findings (moderate to strong agreement). It has reported kapa value of 0.96 (near perfect agreement) for malleus and stapes erosion. They have also not found CT to be in perfect agreement in most of the findings as compared to Intra-op.

In group B (n=60) we found that Incus was the most common ossicular erosion presumed by clinical judgment (25%) as well as intra-op (30%). This was followed in order by stapes erosion (8.3% and 8.3% respectively) and malleus erosion (8.3% and 8.3% respectively). It is seen that clinical judgment is perfect in detecting malleus and stapes erosion while it slightly underestimated the Incus erosion. Ossicular chain continuity is also slightly underestimated by clinical judgment. Though prevalence of aditus blockage is almost same as in clinical judgment and intra-op.

While correlating between clinical judgment and intra-op, it was seen that for detecting aditus blockage and stapes erosion clinical judgment have kapa value of 0.96 and 1 (perfect agreement with gold standard). Kapa values were 0.78, 0.79 and 0.76 (moderate agreement with gold standard) for malleus erosion, Incus erosion and ossicular chain status respectively.

Thus clinical judgment proves to be equal or stronger evidence than CT in evaluation of cases of CSOM at least in detecting ossicular status, individual ossicular bone erosion and aditus blockage. These are sufficient findings for most otologists in most of the patients to successfully complete middle ear and/or mastoid surgeries.

In this study we have not evaluated the accuracy of clinical judgment in detection of scutum erosion (may be predicted on oto-otoendoscopy/microscopic findings) and LSC fistula (may be predicted by fistula test). We have also not evaluated the cost-effectiveness of CT in CSOM cases. If it would have been done, than usefulness of Clinical judgment as evidence could have been further strengthened.

Clinical judgment can't predict the erosions of tegmen, fallopian canal and sinus plate by any means but these are rare findings in complicated CSOM cases (with prevalence between 5 to 15% only). An experienced otologist can easily manage them intra-op. obviously extent of the disease & detection of some complications of CSOM can only be judged by CT.

CONCLUSION

In cases of CSOM, HRCT in comparison with intra-op is in perfect agreement only for aditus blockage and tegmen erosion, while it is in moderate agreement for sinus plate erosions, Weak agreement for ossicular erosions, scutum erosions and LSC fistula, and only Minimal agreement for fallopian canal erosion. Thus HRCT may be good but not perfect investigation for evaluation of CSOM cases, so present study does not recommend it in all cases of CSOM as routine. Clinical judgment in comparison with Intra-op is in Perfect agreement for aditus blockage and stapes erosion and Moderate to near strong agreement for erosions of malleus/incus and for ossicular chain continuity. Thus clinical judgment is as good as or even better than CT in presuming/detecting at least individual

ossicular erosions, ossicular chain continuity. Present study recommends that clinical judgment with PTA is sufficient evidence in most cases of CSOM before doing middle ear surgeries. Some findings like erosion of tegmen, sinus plate and fallopian canal cannot be predicted by clinical judgment. These findings and extent of the disease can only be detected by CT scan. Thus present study recommends to reserve the use of CT for complicated CSOM cases and high risk cases (children with cholesteatoma and revision middle ear surgeries).

Limitations of this study

- Sample size of groups A and B are not matching.
- Pre-op clinical judgement regarding expected intra-op findings are given by different surgeons.
- HRCT temporal bone in this study is not done with 1mm real cuts.
- Clinical judgment has not included prediction of erosion of scutum and LSC fistula.

ACKNOWLEDGEMENTS

Dr. Hiteshree R Patel, Tutor in Department of Community Medicine, Govt Medical College, Surat need special mention for her help in statistical analysis.

Funding: No funding sources

Conflict of interest: None declared

Ethical approval: The study was approved by the Institutional Ethics Committee

REFERENCES

1. Happani H, Kalola J, Rathod H, Trivedi A. Role of HRCT temporal bone in patients with chronic suppurative otitis media. International J Contemporary Med Surg Radiol. 2018;3(3):70-2.
2. Zaid J. Efficacy of pre-operative computed tomography scans on clinical management and temporal bone surgery in cases of chronic otitis media (Dissertation on intrnet) Toronto Boston University 2014. Available at: <http://open.bu.edu>
3. Chatterjee P, Khanna S, Talukdar R. Role of high resolution computed tomography of mastoids in planning surgery for chronic suppurative otitis media. Ind J Otolaryngol Head Neck Surg. 2015;67(3):275-80.
4. Deviana, Dyah I. Pattern and Degree of Hearing Loss in Chronic Suppurative Otitis Media. IOSR-JDMS. 2016;15(3):73-80.
5. Thukral C, Singh A, Singh S, Sood A, Singh K. Role of High Resolution Computed Tomography in Evaluation of Pathologies of Temporal Bone J Clin Diagn Res. 2015;9(9):7-10.
6. Sandeep S, Raghavendra K, Prakash B, Shetty T. How Safe is Safe Ear? A Hospital Based Study. IJCC. 2014;2(2):31-4.
7. Vallabhaneni R, Srinivasa B. HRCT Temporal Bone Findings in CSOM: Our Experience in Rural Population of South India. IOSR-JDMS. 2016;15(1):49-53.
8. Dhulipalla S, Choudary S, Madala N. A study to evaluate the role of High Resolution CT temporal bone in preoperative assessment of ossicular chain status in CSOM patients. IOSR J Dental Med Sci. 2018;17(1):33-7.
9. Mohammed A, Abdel R, Abdel K, Abdel G, Ahmed AE, Ahmed AS. Evaluation of Temporal Bone Cholesteatoma and the Correlation between High Resolution Computed Tomography and Surgical Finding. Clin Med Insights Ear, Nose Throat 2013;6:21-8.
10. Ghada A, Rania A, Ahmad A, Atef H. The Role of HRCT in evaluation of acquired middle ear cholesteatoma otitis prior to surgery. ZUMJ. 2015;21(5):449-61.

Cite this article as: More MS, Patel RB, Contractor JA, Pipaliya AA, Desai EJ, Patel BM. A cross sectional study to assess the role of preoperative HRCT temporal bone in CSOM: a comparison between middle ear surgeries with and without pre-op HRCT. Int J Otorhinolaryngol Head Neck Surg 2019;5:273-9.