

## Case Report

# Laryngeal lipoma: a rare cause of hoarseness

Yuvenesvary Sukumaran<sup>1\*</sup>, Noor Azrin<sup>1</sup>, Loong Siow Ping<sup>1</sup>, Elsie Jane<sup>1</sup>, Angeline Madatang<sup>2</sup>

<sup>1</sup>Department of Otorhinolaryngology, <sup>2</sup>Department of Pathology, Queen Elizabeth Hospital, Kota Kinabalu, Sabah, Malaysia

**Received:** 20 September 2018

**Revised:** 15 November 2018

**Accepted:** 16 November 2018

**\*Correspondence:**

Dr. Yuvenesvary Sukumaran,  
E-mail: [yuvenesvary16@gmail.com](mailto:yuvenesvary16@gmail.com)

**Copyright:** © the author(s), publisher and licensee Medip Academy. This is an open-access article distributed under the terms of the Creative Commons Attribution Non-Commercial License, which permits unrestricted non-commercial use, distribution, and reproduction in any medium, provided the original work is properly cited.

### ABSTRACT

The incidence of lipoma in the laryngeal region is rare. Here we report a case of left false cord lipoma in a 78 years old man who presented with hoarseness for 2 years. Clinically, a bulge with a smooth surface was seen at the left false cord. Intraoperatively, the specimen taken from the left false cord appeared yellowish and was floating on normal saline solution giving a suspect to lipoma. Histologically, the tumors composed of mature adipose tissue. Postoperatively, the patient recovered well with no signs of recurrence.

**Keywords:** Lipoma, Larynx, Hoarseness

### INTRODUCTION

Lipoma is the most common benign tumor of mesenchymal origin and it's the most common benign tumor. About 13% of all lipomas occur in the head and neck and most commonly in the posterior neck.<sup>1</sup> Lipomas of the larynx are very rare benign laryngeal tumors (0.6%).<sup>1</sup> We report a case of laryngeal lipoma with hoarseness as the only presenting complaint.

### CASE REPORT

A 78-year-old man with underlying hypertension, hyperthyroidism, and atrial fibrillation on warfarin presented to us with a complaint of hoarseness for 2 years which was progressively worsening for past 2 months associated with intermittent shortness of breath but no noisy breathing. She denies odynophagia, dysphagia and aspiration symptoms.

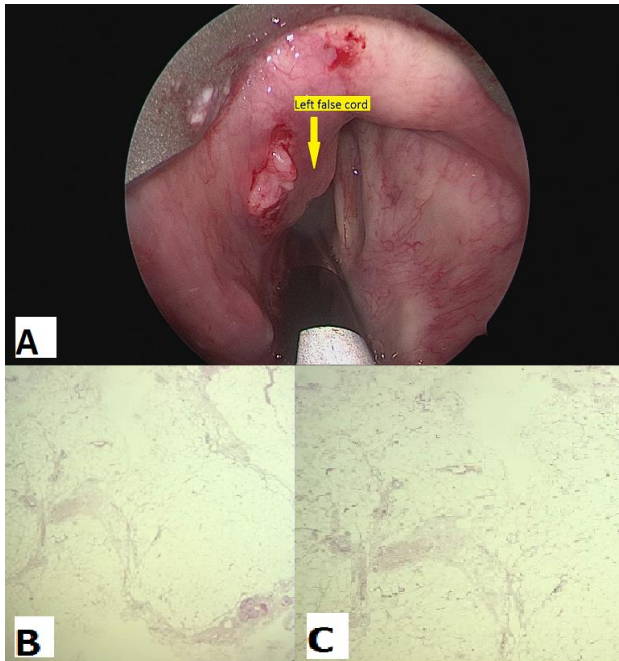
On clinical examination, there was hoarseness but no stridor or respiratory distress. Flexible scope examination revealed left false cord bulge with a smooth surface. The bilateral vocal cord was mobile with no phonation gap.

Other supraglottic structures were normal. Initial impression was to rule out laryngeal carcinoma and he was counseled for endoscopic micro laryngeal surgery and biopsy of left false cord.

The patient underwent an endoscopic examination under anesthesia and biopsy. Intraoperatively, noted fullness superior to the left false cord, smooth surface with normal mucosa. The left ventricle was effaced. Left true cord, right false cord and right ventricle were normal. A vertical incision was made at the left false cord and yellowish soft tissue seen which appear to be fatty tissue. Multiple biopsies were taken and the tissue sample was floating in a normal saline solution. Histopathological examination confirmed the diagnosis of lipoma. Microscopically, the excised lesion composed of mature adipose tissue separated into lobules by fibrovascular septa. Foci of seromucinous glands are also seen. No lipoblast.

No complications occurred during the postoperative period; the patient was allowed home on day 6 postoperatively. On account of the possibility of recurrence of lipomas after long free-intervals, an

appointment for contrast-enhanced CT Neck was given and the patient is still periodically observed with physical ENT examination for long-term follow up.



**Figure 1: Intraoperative and histopathological findings: (A) the presence of left vocal cord fullness (as shown in the arrow); (B and C) the presence of mature adipose tissue separated into lobules by fibrovascular septa.**

## DISCUSSION

Lipoma of the larynx and the hypopharynx are very rare benign lesions. It has been estimated that 15% of lipomas occur in the head and neck region.<sup>2</sup> Till date, only 115 cases of laryngeal lipoma have been reported in the literature.<sup>2</sup>

Lipoma commonly occurs in the areas that have more adipose content. Its occurrence in the larynx is only about 0.6% of all benign lesions of the larynx.<sup>3</sup> In 1965, Zakzewski carried out a review which divides laryngeal lipoma into extrinsic lipoma (posterior surface of arytenoid, lingual surface of the epiglottis and pharyngeal wall) and intrinsic lipomas (false cord, aryepiglottic fold, and epiglottis).<sup>3</sup> This is due to a relatively small amount of adipose deposition in the intrinsic lipomas. Among all intrinsic lipoma, the glottic form is the rarest and was present in our case.<sup>1</sup>

Lipomas can be varied in shapes and sizes. Endoscopic appearance of lipoma is varied ranging from submucosal mass to pedunculated intraluminal projection, so clinical lipoma can be confused with other benign lesions such as retention cyst or laryngoceles.<sup>3</sup> Microscopically they contain mature adipocytes with large central vacuole which often displace nucleus peripherally.<sup>3</sup>

The symptoms depend on the size and location of the lipoma. Small lipomas usually produce no symptom and found incidentally during the laryngeal examination. These tumors are often polypoid and have been reported to grow up to 23 cm in length.<sup>4</sup> The patient may be either asymptomatic or complain of dysphagia, a foreign body sensation, a change in the quality of voice.<sup>4</sup> Lipoma has a potential of prolapse into the esophagus and causes upper airway obstruction.<sup>4</sup>

Imaging modalities such as CT or MRI may give additional information in managing laryngeal lipoma cases. On CT scan, fat tissue shows up as typically homogeneous with a low attenuation value and a density lower than that of water (<0 Hounsfield units).<sup>1</sup> Liposarcoma is a differential diagnosis and MRI gives better tumor delineation as it has superior soft tissue contrast as well as a clear definition of the location and extent of the mass. Thickened or nodular septa (generally >2 mm thick), associated no adipose masses, prominent foci of a high T2 signal and prominent areas of enhancement are suggestive of liposarcoma.<sup>5</sup>

The treatment of choice is total excision using conservative surgical removal when clinical symptoms are present.<sup>1</sup> The extent of the procedure depending on the size and site of a tumor. As there is a possibility of recurrence, lipomatous mass should be excised completely.<sup>1</sup> The small ones can be excised by endoscopic surgery, but external approach such as thyrotomy, transhyoid or lateral pharyngotomy is required for large masses.<sup>3</sup>

*Funding: No funding sources*

*Conflict of interest: None declared*

*Ethical approval: Not required*

## REFERENCES

1. Özmen CA, Nazaroğlu H, Yildirim M, Akay HO, Bayrak AH. A rare cause of dysphonia: laryngeal lipoma: Differential diagnosis. *Turkiye Klinikleri J Med Sci.* 2009;29(6):1789-91.
2. Kanaujia SK, Soni A. A Rare Benign Tumour of vocal cord: Myxofibrolipoma. *Int J Phonosurg Laryngol.* 2014;4(2):67-8
3. Ashtiani MTK, Yazdani N, Saeedi M, Amali A. Large lipoma of larynx. A case report. *Acta Medica Iranica.* 2010;48(5):353-6.
4. Som PM, Scherl MP, Rao VM, Biller HF. Rare presentation of ordinary lipoma of the head and neck: A review. *AJNR.* 1986;7:657-64.
5. Gaskin CM, Helms CA. Lipomas, Lipoma Variants, and Well-Differentiated Liposarcomas (Atypical Lipomas): Results of MRI Evaluations of 126 Consecutive Fatty Masses, *AJR.* 2004;182:733-9.

**Cite this article as:** Sukumaran Y, Azrin N, Ping LS, Jane E, Madatang A. Laryngeal lipoma: a rare cause of hoarseness. *Int J Otorhinolaryngol Head Neck Surg* 2019;5:191-2.