

Original Research Article

Iatrogenic bilateral recurrent laryngeal nerve injury: a retrospective study

P. Thamizharasan*, R. Madanagopal

Department of ENT, Government Royapettah Hospital and Kilpauk Medical College, Chennai, Tamil Nadu, India

Received: 26 July 2018

Revised: 03 October 2018

Accepted: 05 October 2018

***Correspondence:**

Dr. P. Thamizharasan,

E-mail: thamizhent06@gmail.com

Copyright: © the author(s), publisher and licensee Medip Academy. This is an open-access article distributed under the terms of the Creative Commons Attribution Non-Commercial License, which permits unrestricted non-commercial use, distribution, and reproduction in any medium, provided the original work is properly cited.

ABSTRACT

Background: Bilateral recurrent laryngeal nerve injury is mostly iatrogenic following thyroidectomy. Our study aims at defining need for tracheostomy, timing of intervention and best method to achieve permanent treatment in cases of iatrogenic bilateral recurrent laryngeal nerve.

Methods: In past four years we did 34 total thyroidectomy surgeries, all patients were female between 21-65 years of age. Common indications were multi nodular goiter 25 cases, papillary carcinoma thyroid 7 cases and follicular neoplasm 2 cases. 5 patients developed bilateral recurrent laryngeal nerve injury, of which 3 were multi nodular goiter cases and papillary carcinoma thyroid 2 cases.

Results: 5 out of 34 (14.7%) patients developed bilateral recurrent laryngeal nerve injury. 3 patients had complete bilateral abductor paralysis. 1 patient had bilateral abductor paresis and 1 patient had all bilateral recurrent laryngeal nerve and superior laryngeal nerve injury causing combined paralysis of vocal cord. Other 3 patients with bilateral abductor paralysis, 1 patient was not willing for tracheostomy and 2 patients underwent tracheostomy. Of those with tracheostomy, one had partial recovery after one year and tracheostomy was removed. The other patient had coblation arytenoidectomy.

Conclusions: In bilateral recurrent laryngeal nerve injury, Tracheostomy to be done if airway is compromised. Patients with pathological laryngeal electromyographic findings at least two months after the paresis need laryngeal framework surgery. Endoscopic cordotomy is the preferred intervention for long-term management.

Keywords: Thyroidectomy, Recurrent laryngeal nerve injury, Bilateral abductor paralysis, Tracheostomy

INTRODUCTION

Thyroidectomy is an interesting and challenging surgery for surgeons. The complications like bleeding, hypoparathyroidism and Recurrent Laryngeal Nerve injury represent nearly half of all the complications of thyroid surgery.¹ Of all these recurrent laryngeal nerve injury hamper the quality of life. In unilateral recurrent laryngeal nerve injury, patient will have hoarseness of voice. But in bilateral recurrent laryngeal nerve injury,

the patient will have normal voice but will have dyspnoea and sometimes life-threatening stridor.²

Recurrent laryngeal nerve injury is a major concern in thyroidectomy. An almost certain way to ensure the integrity of the RLN is to always identify the nerve during thyroidectomy surgeries.^{3,4} Bilateral recurrent laryngeal nerve injury is mostly iatrogenic following thyroidectomy. This publication aims defining need for tracheostomy, timing of intervention and best method to

achieve permanent treatment in cases of iatrogenic bilateral recurrent laryngeal nerve.

Prevention is better than cure

An almost certain way to ensure the integrity of the RLN is to always identify the nerve during all surgical procedure on thyroid and parathyroid glands. RLN is located anterior to the tracheoesophageal sulcus (41.6%), posterior to the inferior thyroid artery (35.8%), lateral to Berry's ligament (88.1%), below the inferior rim of the inferior constrictor muscle (90.4%), and entering the larynx before its terminal division (54.6%).⁵

Nature alternatives

Even if recurrent laryngeal nerve injured, nature has provided alternatives for itself to reinnervate by the following possible alternatives.

Galen anastomosis

The RLN divides into an anterior and posterior branch. The posterior branch projects superiorly to form the anastomosis of Galen with the internal branch of the SLN—this branch is probably sensory in nature. Within the larynx, the RLN and SLN break up into a plexus-like branching system, with several connections between the RLN and SLN.^{6,7} The exact functions of Galen's anastomosis are not fully known, but it has been demonstrated in animals that the intrinsic laryngeal muscles receive dual innervations from both the RLN and SLN.^{8,9}

Cricothyroid connection branch

The external branch of the SLN continues through the cricothyroid muscle to reach the anterior glottis and the thyroarytenoid muscle. This branch, “the human communicating nerve” or “the cricothyroid connection branch” is an additional motor supply to the intrinsic laryngeal muscles and is important following RLN injury and reinnervation.^{10,11}

Neuroplasticity

The distal axotomy in the intact RLN loses contact with higher cortical centers. Synapses from cortical neurons re-appear on the secondary motor neurons as the neurons manage to regenerate and re-establish contact with the target organ (plasticity).^{12,13}

In advanced world of science, where cost should not be a compromise on patient's safety, intraoperative nerve monitoring has to be done when available.

Intra operative nerve monitoring (IONM)

Originally, RLN monitoring was through needle electrodes inserted into the intrinsic laryngeal muscles.¹⁴ Now-a-days, thyroarytenoid depolarization is recorded

through surface electrodes on the ventilation tube¹⁵. When the signal is lost during surgery, it is not possible to use IONM to diagnose the type of nerve injury (axonotmesis or neuropraxia); it only tells us that there is a discontinuity of the electrical propagation within the nerve.

The important factors for recurrent laryngeal nerve injury are surgeon's experience, histopathology diagnosis, previous thyroid surgery, surgical technique and anatomic variations. Mechanisms of injury to the nerve are complete or partial transection, traction, or handling of the nerve, contusion, crush, burn, clamping, misplaced ligature, compromised blood supply.

Bilateral recurrent laryngeal nerve injury or acute bilateral vocal cord paralysis can result in immediate symptoms requiring urgent airway intervention. In some clinical situations, the airway symptoms can worsen over several weeks as a result of aberrant reinnervation or synkinesis.

Aim was to study the incidence of bilateral recurrent laryngeal nerve injury following surgery and to analyse the immediate and long term management..

METHODS

Study design: Retrospective cohort study.

Study place: Government Royapettah Hospital, Kilpauk Medical College, Chennai.

Duration: 4 years.

Inclusion criteria

Total thyroidectomy surgery for various indications and those with central compartment neck dissection.

Exclusion criteria

Exclusion criteria were hemi thyroidectomy surgeries; total thyroidectomy with modified radical or radical neck dissections; also other complications such as unilateral recurrent laryngeal nerve injury, postoperative hypocalcemia are excluded from study.

Ethical committee approval was taken from Government Kilpauk Medical College Ethical Committee.

All patients were admitted after thorough clinical, thyroid function tests, ultrasonogram and fine needle aspiration cytology were done. Indirect laryngoscopy was done in each patient to assess the status of vocal cords pre-operatively. Patients were prepared for surgery and all necessary routine investigations were carried out.

Attempts were made to identify and preserve recurrent laryngeal nerve in all cases. Vocal cords mobility was

checked by the operating surgeon at the time of extubation. Postoperatively, indirect laryngoscopy was done on the second and fifteenth postoperative day.

Postoperative vocal palsy was defined as the presence of immobile vocal cord or decreased movement of vocal cord during phonation. The patients who developed vocal cord paralysis were planned to be followed up on fortnightly basis in the first three months and then at monthly intervals for at least six months. Clinical evaluation of these patients was done regarding any improvement in voice quality or vocal cord function.

Dysphonia or vocal cord paralysis detected on indirect laryngoscopy was considered as transient paralysis if recovered within 6 months and as permanent paralysis if it continued beyond 6 months.

RESULTS

We did 34 total thyroidectomy surgeries. All patients were female between 21-65 years (mean=45) of age. Common preoperative diagnosis based on fine needle aspiration cytology and ultra-sonogram were, multinodular goiter (N=25; 73.5%), papillary carcinoma thyroid (N=7; 20.5%), and follicular neoplasm (N=2; 5.8%) (Figure 1),

5 patients (14.7%) developed bilateral recurrent laryngeal nerve injury (Table 1), of which 3 were multi nodular goiter cases and papillary carcinoma thyroid 2 cases.

1. Three out of five patients had complete bilateral abductor paralysis (9%).
2. One had delayed onset paresis (Figure 2) (3%).
3. One had combined bilateral abductor and adductor paralysis (Figure 3) (3%).

Table 1: List of cases with bilateral recurrent laryngeal nerve injury (n=5 cases).

| Type of paralysis | S.no. | Symptoms | Immediate management | Long term outcome |
|--|-------|--|---|--|
| Temporary paralysis (n=3 cases) | 1. | Breathy voice | No tracheostomy | Recovered fully |
| | 2. | Stridor | Tracheostomy | One vocal cord improved, Tracheostomy tube removed |
| | 3. | Aspiration and breathy voice | No tracheostomy, initial management with nasogastric tube | Vocal cord adduction improved, Recovered swallowing without aspiration |
| Permanent paralysis (n=2 cases) | 4. | Stridor | Tracheostomy | Coblation arytenoidectomy, Tracheostomy tube removed |
| | 5. | Dyspnoea on exertion and aggravation by infections | Not willing for tracheostomy | Managed with steroids and nebulisation intermittently |

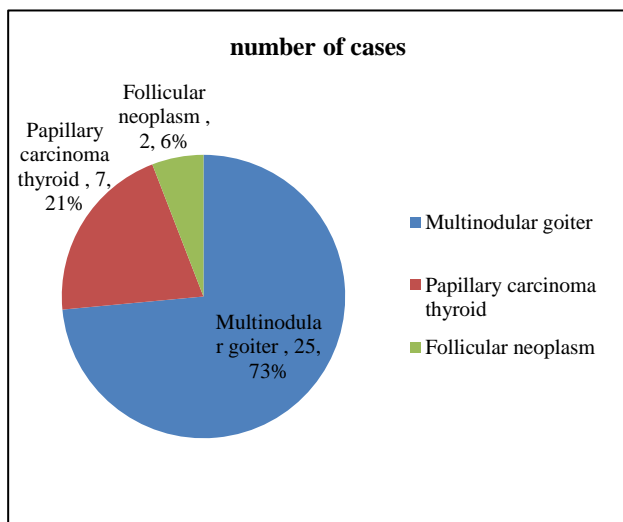


Figure 1: Indication for total thyroidectomy cases.

Other 3 patients with bilateral abductor paralysis, 1 patient was not willing for tracheostomy (Figure 4) and 2 patients underwent tracheostomy.

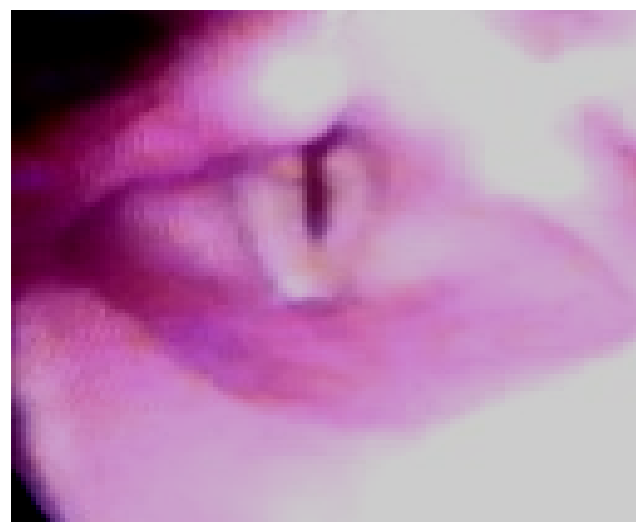


Figure 2: Delayed recurrent laryngeal nerve paresis.

Of those with tracheostomy, one had partial recovery after one year (Figure 5) and tracheostomy was removed.

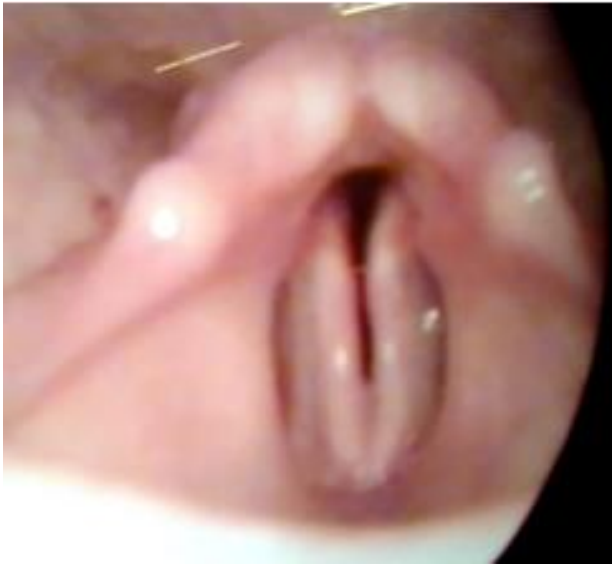

Figure 3: Bilateral abductor paralysis.

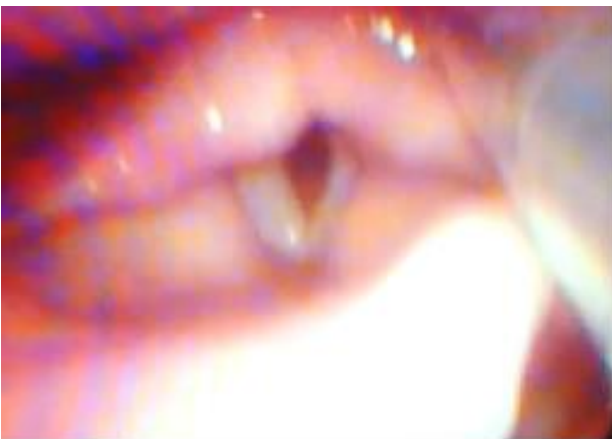

Figure 4: Combined (both abductor and adductor) paralysis of both vocal cords with nasogastric tube seen behind inserted to avoid aspiration.

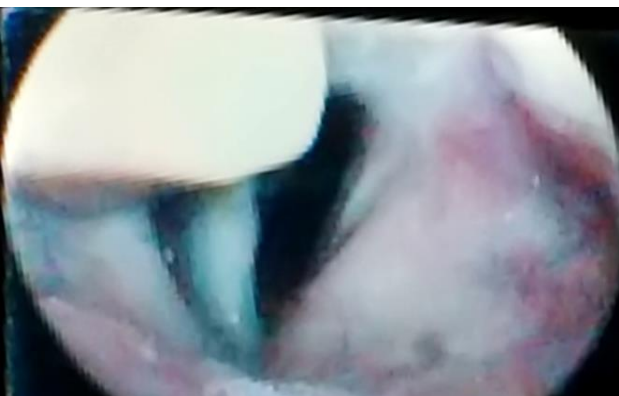

Figure 5: Recovered bilateral recurrent laryngeal nerve injury.

The other patient had coblation arytenoidectomy (Figure 6 a-e).

Three out of five patients managed without tracheostomy for various reasons. Two patients had tracheostomy, one of them recovered partial vocal cord function and one patient had undergone surgery. Hence tracheostomy was removed for both.

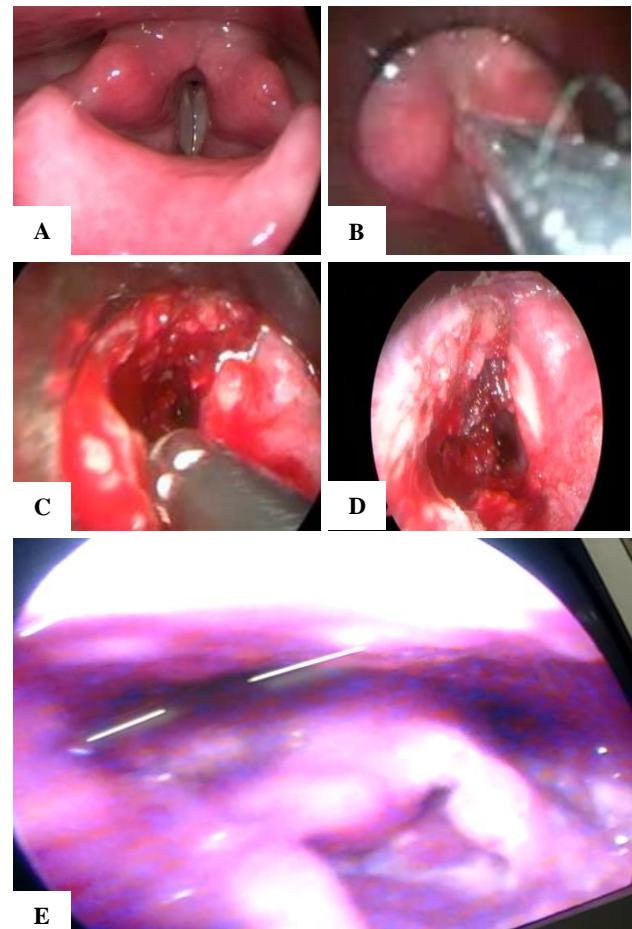


Figure 6: (A) Bilateral abductor paralysis; (B) endoscopic view of bilateral paralysis of vocal cords in midline position; (C) sub mucosal dissection of arytenoid cartilage and vaporization of thyroarytenoid muscle fibers using coblator; (D) postoperative view immediately after Kashima's procedure; (E) post cordectomy status.

DISCUSSION

In our study, 3 patients (8.8%) had temporary paralysis and 2 patients (5.8%) had permanent paralysis of 34 total thyroidectomy cases done between 2014 and 2018.

Jatzko et al reviewed 21 patients of total thyroidectomy from 1984 to 1991 and reported 9.5% temporary paralysis and 4.8% permanent paralysis.¹⁶

Kasem suwan et al reviewed 105 patients of total thyroidectomy from 1993 to 1996 and had an experience of 6.7% Temporary paralysis and 7.6% permanent paralysis.¹⁷

Aytac et al did a retrospective study of 418 patients of all types of tracheostomy from 1989 to 2003 and found 13.6% Temporary paralysis and 9% Permanent paralysis among total thyroidectomy patients.¹⁸

Chaudhary et al reviewed about 310 patients of lobectomy and total thyroidectomy from 2000 to 2005 and published 7.69% Temporary paralysis and 3.8% Permanent paralysis among total thyroidectomy patients.¹⁹

Zakaria et al reviewed 340 patients between 1990 and 2005 and published in 2010 3.8% temporary paralysis and 0.29% Permanent paralysis among total thyroidectomy patients.²⁰

Over all incidence of vocal cord paralysis from review of literature ranges from 1.5-14%.

Immediate management

Two clinical situations of our series have undergone tracheostomy immediately after extubation because of airway compromise. In our case series, first patient had paresis manifesting symptoms only three days later. Tracheostomy was delayed and patient observed closely, managed with steroids and anti-inflammatory drugs. Patient had recovery of recurrent laryngeal nerve function later and successfully survived without tracheostomy. In the second patient although the patient presented with stridor, since the patient was not willing for tracheostomy, tracheostomy was not done. Even now, the patient comes occasionally to casualty with stridor and gets treated medically without tracheostomy. In the third patient there was combined paralysis of both vocal cords, and patient had aspiration for liquid feeds. Tracheostomy with cuffed tube was indicated to prevent aspiration, but patient was managed with nasogastric tube liquid feeding and solid semisolid diet orally.

Recommendations after review of literature is the following.^{21,22}

1. In acute bilateral abductor paralysis, Tracheostomy or endotracheal intubation should be done.
2. In delayed onset paralysis, as it is due to edema, antiedema measures and tracheostomy shall be delayed if there is no stridor.
3. In late onset after several weeks which occurs due to aberrant reinnervation or synkinesis, Tracheostomy should be done if there is airway compromise.

Timing of intervention

In clinical situations of resistant or non-recovering bilateral recurrent laryngeal nerve injury, the timing of surgery for permanent airway without tracheostomy is not defined yet.

In the fourth patient who had partial recovery of one vocal cord function after one year tracheostomy was weaned successfully.

In the fifth patient there were no signs of recovery at three months and the patient was willing for surgical intervention, hence arytenoidectomy with partial cordectomy done and tracheostomy was weaned successfully.

The duration for recovery of recurrent laryngeal nerve injury depends on type of injury.

In a large retrospective study of patients that underwent total thyroidectomy due to malignant disease, the risk of postoperative vocal fold paresis was found to be 9.5%, of which 22% became permanent with resulting demand for secondary surgical intervention of the paralyzed vocal fold.²³

In most clinical situations the recurrent laryngeal nerve is macroscopically intact and the injury is located within the peripheral nerve. To predict recovery, the surgeon would need to define the presence, location, and type of the nerve injury. However, very little data is available at clarifying the differences between the transient and permanent injury of the recurrent laryngeal nerve.

Laryngeal electromyography (LEMG)

Postoperative electro diagnostic methods can be used to determine the presence and type of nerve injury and to characterize the ongoing or completed reinnervation processes.²⁴

Pototschnig et al proposed guidelines for Laryngeal Electromyography and set optimal time window for postoperative LEMG seems to be 2-4 weeks after the nerve injury.²⁵ They further stated that patients with pathological electromyographic findings at least two months after the paresis are most likely to need laryngeal framework surgery. For patients with only a conduction block (neuropraxia) of the RLN, vocal fold movement is most likely to return.

In our series we didn't had access to this investigation and it was not done in our case series.

Regeneration promotion

Use of nimodipine for promoting regeneration of recurrent laryngeal nerve after injury is proposed by Remahl et al, Young et al, Smith et al.²⁶⁻²⁸

The mechanism of nimodipine is by altering the intracellular concentration of calcium ions and has a strict correlation to the ability of the growth cone to sprout. Nimodipine, a voltage-gated calcium flow antagonist to the L-type channels has been evaluated in rodent models, and is a pharmacologically good choice because it

penetrates the blood brain barrier better than most other calcium flow antagonists.

In the third patient with combined paralysis we treated the patient with nimodipine and there was recovery of function due to multiple factors, one of which may be nimodipine. However we don't have enough valuable data to prove efficacy of nimodipine in recurrent laryngeal nerve injury.

Permanent treatment for bilateral recurrent laryngeal nerve injury. The surgical options available for permanent bilateral recurrent laryngeal nerve injury to relieve patients of tracheostomy are the following.²⁹ Arytenoidectomy as open-neck resection of the arytenoid was performed from early 1900s.

In 1948, Thornell first described endolaryngeal arytenoidectomy.³⁰ Ossoff et al demonstrated arytenoidectomy using CO₂ laser endoscopically.³¹

Crumley proposed endoscopic laser medial arytenoidectomy with minimal resection of the vocal fold.³²

Recently use of an endoscopic plasma coblator avoids thermal damage to surrounding tissues, hence less scar formation.³³

Cordotomy aims at resection of laryngeal soft tissues, such as parts of the vocal fold, the vocal ligament, or the thyroarytenoid (TA) muscle. Sometimes they are performed conjointly (i.e., arytenoidcordectomy).³⁴ In comparison to arytenoidectomy, cordotomy is preferred because it is less destructive and there are fewer tendencies for aspiration. Cordotomy can be proposed as an alternative to tracheostomy even at the time of diagnosis, but with risk for aspiration.

Dennis and Kashima followed suit with their introduction of a modern endoscopic laser cordotomy technique in 1989.³⁵ They performed the CO₂ laser posterior cordotomy by resecting the soft tissues of the posterior vocal fold and transecting the conus elasticus. In this technique, a C-shaped wedge of posterior vocal fold was excised from the free border with a lateral extension of a couple millimeters to release soft tissue tension on the vocal fold. Cordotomy was susceptible to granulation, scar formation and deterioration of voice quality. Patients often complained of a rough and breathy voice because of damage to the vibratory part of the operated vocal fold.

In the fifth case of our series we managed the bilateral vocal fold paralysis with above method, coblation cordotomy with arytenoidectomy and had good results.

Castellanos et al after review of all procedures concluded that Laser endoscopic cordotomy has become the preferred therapeutic intervention for long-term management of BVFP.³⁶

Other options in management of bilateral recurrent laryngeal nerve injury. Suture laterofixation and suture lateralization of the arytenoid and/or the attached vocal fold using a combination of endoscopic and external means has emerged as an alternative surgical approach.³⁷ It helps in temporary management of the airway, with expectation of recovery of laryngeal function or avoidance of tracheostomy.

Laryngeal reinnervation with primary goal should be to re-establish the vocal fold abduction, as dyspnea is the major symptom in most of these patients, through reinnervation of the abductor (PCA) muscle.³⁸

Phrenic nerve is a good source of nerve supply as it contains a homogeneous composition of motoneurons that are active during inspiration.³⁹

Functional electrical stimulation (FES) of paralyzed laryngeal muscles has been investigated by laryngeal pacing. Zeale et al did laryngeal pacing as an effective mean of treatment in the human using an external device.⁴⁰

Shiotani et al in 2007 demonstrated Gene therapy for laryngeal paralysis.⁴¹ Dirja et al in 2016 demonstrated Potential of laryngeal muscle regeneration using induced pluripotent stem cell-derived skeletal muscle cells.⁴² However both gene therapy and stem cell therapy are still in animal experimental stages till this time of publication.

CONCLUSION

In bilateral recurrent laryngeal nerve injury, Tracheostomy should be done immediately if airway is compromised. Patients with pathological electromyographic findings at least two months after the paresis are most likely to need laryngeal framework surgery. Endoscopic cordotomy is the preferred therapeutic intervention for long-term management of bilateral vocal fold paralysis.

Funding: No funding sources

Conflict of interest: None declared

Ethical approval: The study was approved by the Institutional Ethics Committee

REFERENCES

1. Ready AR, Barnes AD. Complications of thyroidectomy. *Br J Surg.* 1994;81(11):1555-6.
2. Jatzko GR, Lisborg PH, Müller MG, Wette VM. Recurrent nerve palsy after thyroid operations—principal nerve identification and a literature review. *Surgery.* 1994;115(2):139-44.
3. Sosa JA, Bowman HM, Tielsch JM, Powe NR, Gordon TA, Udelsman R. The importance of surgeon experience for clinical and economic outcomes from thyroidectomy. *Ann Surg.* 1998;228(3):320-30.

4. Lamadé W, Renz K, Willeke F, Klar E, Herfarth C. Effect of training on the incidence of nerve damage in thyroid surgery. *Br J Surg.* 1999;86(3):388-91.
5. Asgharpour E, Marañillo E, Sañudo J, Pascual-Font A, Rodriguez-Niedenführ M, Valderrama FJ, et al. Recurrent laryngeal nerve landmarks revisited. *Head Neck.* 2012;34:1240-6.
6. Dilworth TF. The Nerves of the Human Larynx. *J Anat.* 1921;56:48-52.
7. Sañudo JR, Marañillo E, León X, Mirapeix RM, Orús C, Quer M. An anatomical study of anastomoses between the laryngeal nerves. *Laryngoscope.* 1999;109:983-7.
8. Björck G, Margolin G, Måbäck GM, Persson JK, Mattsson P, Hydman J. New animal model for assessment of functional laryngeal motor innervation. *Ann Otol Rhinol Laryngol.* 2012;121:695-9.
9. Hydman J, Mattsson P. Collateral reinnervation by the superior laryngeal nerve after recurrent laryngeal nerve injury. *Muscle Nerve.* 2008;38:1280-9.
10. Wu BL, Sanders I, Mu L, Biller HF. The human communicating nerve. An extension of the external superior laryngeal nerve that innervates the vocal cord. *Arch Otolaryngol Head Neck Surg.* 1994;120:1321-8.
11. Marañillo E, León X, Quer M, Orús C, Sañudo JR. Is the external laryngeal nerve an exclusively motor nerve? The cricothyroid connection branch. *Laryngoscope.* 2003;113:525-9.
12. Hydman J, Svensson M, Kuylenstierna R, Ohlsson M, Mattsson P. Neuronal survival and glial reactions after recurrent laryngeal nerve resection in the rat. *Laryngoscope.* 2005;115:619-24.
13. Blinzinger K, Kreutzberg G. Displacement of synaptic terminals from regenerating motoneurons by microglial cells. *Z Zellforsch Mikrosk Anat.* 1968;85:145-57.
14. Randolph GW, Dralle H. International Intraoperative Monitoring Study Group. Electrophysiologic recurrent laryngeal nerve monitoring during thyroid and parathyroid surgery: international standards guideline statement. *Laryngoscope.* 2011;121(1):1-16.
15. Dionigi G, Donatini G, Boni L, Rauser S, Rovera F, Tanda ML, et al. Continuous monitoring of the recurrent laryngeal nerve in thyroid surgery: a critical appraisal. *Int J Surg.* 2013;11(1):44-6.
16. Jatzko GR, Lisborg PH, Müller MG, Wette VM. Recurrent nerve palsy after thyroid operations—principal nerve identification and a literature review. *Surgery.* 1994;115(2):139-14.
17. Kasemsuwaran L, Nubthuenetr SJ. Recurrent laryngeal nerve paresis: a complication of thyroidectomy. *Otorhinolaryngology.* 1997;26:365-7.
18. Aytac B, Karamercan A. Recurrent laryngeal nerve injury and preservation in thyroidectomy. *Saudi Med J.* 2005;26(11):1746-9.
19. Chaudhary IA, Samiullah MR, Masood R, Majrooh MA, Mallhi AA. Recurrent laryngeal nerve injury: an experience with 310 thyroidectomies. *J Ayub Med Coll Abbottabad.* 2007;19(3):46-50.
20. Zakaria HM, Awad NAA, Kreedes ASA, Al-Mulhim AMA, Al-Sharway MA, Hadi MA, et al. Recurrent Laryngeal Nerve Injury in Thyroid. *Surg Oman Med J.* 2011;26(1):34-8.
21. Hillel AD, Benninger M, Blitzer A, Crumley R, Flint P, Kashima HK, et al. Evaluation and management of bilateral vocal cord im-mobility. *Otolaryngol Head Neck Surg.* 1999;121(6):760-5.
22. Myssiorek D. Recurrent laryngeal nerve paralysis: anatomy and etiology. *Otolaryngol Clin North Am.* 2004;37(1):25-44.
23. Francis DO, Pearce EC, Ni S, Garrett CG, Penson DF. Epidemiology of vocal fold paralyse after total thyroidectomy for well-differentiated thyroid cancer in a Medicare population. *Otolaryngol Head Neck Surg* 2014;150:548-57.
24. Wang CC, Chang MH, De Virgilio A, Jiang RS, Lai HC, Wang CP, et al. Laryngeal electromyography and prognosis of unilateral vocal fold paralysis—A long-term prospective study. *Laryngoscope.* 2015;125(4):898-903.
25. Volk GF, Hagen R, Pototschnig C, Friedrich G, Nawka T, Arens C, et al. Laryngeal electromyography: a proposal for guidelines of the European Laryngological Society. *Eur Arch Otorhinolaryngol.* 2012;269:2227-45.
26. Mattsson P, Björck G, Remahl S, Bäckdahl M, Hamberger B, Hydman J, et al. Nimodipine and microsurgery induced recovery of the vocal cord after recurrent laryngeal nerve resection. *Laryngoscope* 2005;115:1863-5.
27. Rosen CA, Smith L, Young V, Krishna P, Muldoon MF, Munin MC. Prospective investigation of nimodipine for acute vocal fold paralysis. *Muscle Nerve.* 2014;50:114-8.
28. Sridharan SS, Rosen CA, Smith LJ, Young VN, Munin MC. Timing of nimodipine therapy for the treatment of vocal fold paralysis. *Laryngoscope.* 2015;125:186-90.
29. Li Y, Garrett G, Zelear D. Department of Otolaryngology, Vanderbilt University Medical Center, Nashville, TN, USA Review Current Treatment Options for Bilateral Vocal Fold Paralysis: A State-of-the-Art. *Rev Clin Exp Otorhinol.* 2017;10(3):203-12.
30. Thornell WC. A new intralaryngeal approach in arytenoidectomy in bilateral abductor paralysis of the vocal cords; report of three clinical situations. *Arch Otolaryngol.* 1949;50(5):634-9.
31. Ossoff RH, Karlan MS, Sisson GA. Endoscopic laser arytenoidecto-my *Lasers Surg Med.* 1983;2(4):293-9.
32. Crumley RL. Endoscopic laser medial arytenoidectomy for airway management in bilateral laryngeal paralysis *Ann Otol Rhinol Laryngol.* 1993;102(2):81-4.

33. Googe B, Nida A, Schweinfurth J. Coblator arytenoidectomy in the treatment of bilateral vocal cord paralysis. *Case Rep Otolaryngol.* 2015;2015:487280.
34. Sapundzhiev N, Lichtenberger G, Eckel HE, Friedrich G, Zenev I, Toohill RJ, et al. Surgery of adult bilateral vocal fold paralysis in adduction: history and trends. *Eur Arch Otorhinolaryngol.* 2008;265(12):1501-14.
35. Dennis DP, Kashima H. Carbon dioxide laser posterior cordectomy for treatment of bilateral vocal cord paralysis *Ann Otol Rhinol Laryngol.* 1989;98(12):930-4.
36. Szakacs L, Sztano B, Matievics V, Bere Z, Bach A, Castellanos PF, et al. A comparison between transoral glottis-widening techniques for bilateral vocal fold immobility *Laryngoscope.* 2015;125(11):2522-9.
37. Damrose EJ. Suture laterofixation of the vocal fold for bilateral vocal fold immobility. *Curr Opin Otolaryngol Head Neck Surg.* 2011;19(6):416-21.
38. Marina MB, Marie JP, Birchall MA. Laryngeal reinnervation for bilateral vocal fold paralysis *Curr Opin Otolaryngol Head Neck Surg.* 2011;19(6):434-8.
39. Li M, Chen S, Zheng H, Chen D, Zhu M, Wang W, et al. Reinnervation of bilateral posterior cricoarytenoid muscles using the left phrenic nerve in patients with bilateral vocal fold paralysis *PLoS One.* 2013;8(10):e77233.
40. Zealear DL, Rainey CL, Herzon GD, Netterville JL, Ossoff RH. Electrical pacing of the paralyzed human larynx *Ann Otol Rhinol Laryngol.* 1996;105(9):689-93.
41. Shiotani A, Saito K, Araki K, Moro K, Watabe K. Gene therapy for laryngeal paralysis *Ann Otol Rhinol Laryngol.* 2007;116(2):115-22.
42. Irja BT, Yoshie S, Ikeda M, Imaizumi M, Nakamura R, Otsuki K, et al. Potential of laryngeal muscle regeneration using induced pluripotent stem cell-derived skeletal muscle cells. *Acta Otolaryngol.* 2016;136(4):391-6.

Cite this article as: Thamizharasan P, Madanagopal R. Iatrogenic bilateral recurrent laryngeal nerve injury: a retrospective study. *Int J Otorhinolaryngol Head Neck Surg* 2018;4:1444-51.